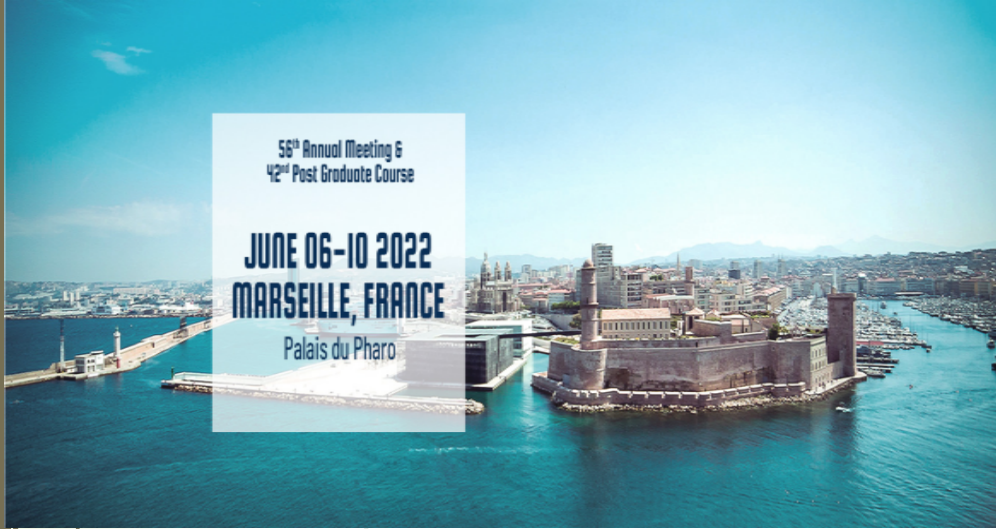



NEONATAL RENAL VEIN THROMBOSIS : PROGNOSTIC IMAGING MARKERS AT DIAGNOSIS AND OUTCOME ACCORDING TO THE TREATMENT

ESPR 56th annual meeting, June 2022

Karim BERGAOUI (1) , Bellaure NDOUDI LIKOH (2), Anca TANASE (1), Alexandra NTORKOU (1), Theresa KWON (2), Julien HOGAN (2), Marianne ALISON (1)

(1) Pediatric radiology, Robert Debré Hospital, Université de Paris

(2) Pediatric nephrology, Robert Debré Hospital, Université de Paris



Background

- Neonatal Renal Vein Thrombosis (NRVT) :
- Rare condition (estim. at 2,6/100 000)
- Retrospective studies
- No consensus about treatment



Objective

- Imaging findings
- Outcomes according to treatment
- Imaging prognostic markers (1) ?

(1) Jeannette K. Kraft. *Pediatr Radiol* (2011) 41:299–307. Sonography of renal venous thrombosis in neonates and infants: can we predict outcome



Methods

- Retrospective study (2005-2020)
- 17 neonates (13 unilateral – 4 bilateral)
- Risk factors for thrombosis
- Clinical presentation
- Imaging findings (PACS)
- Treatment and follow up



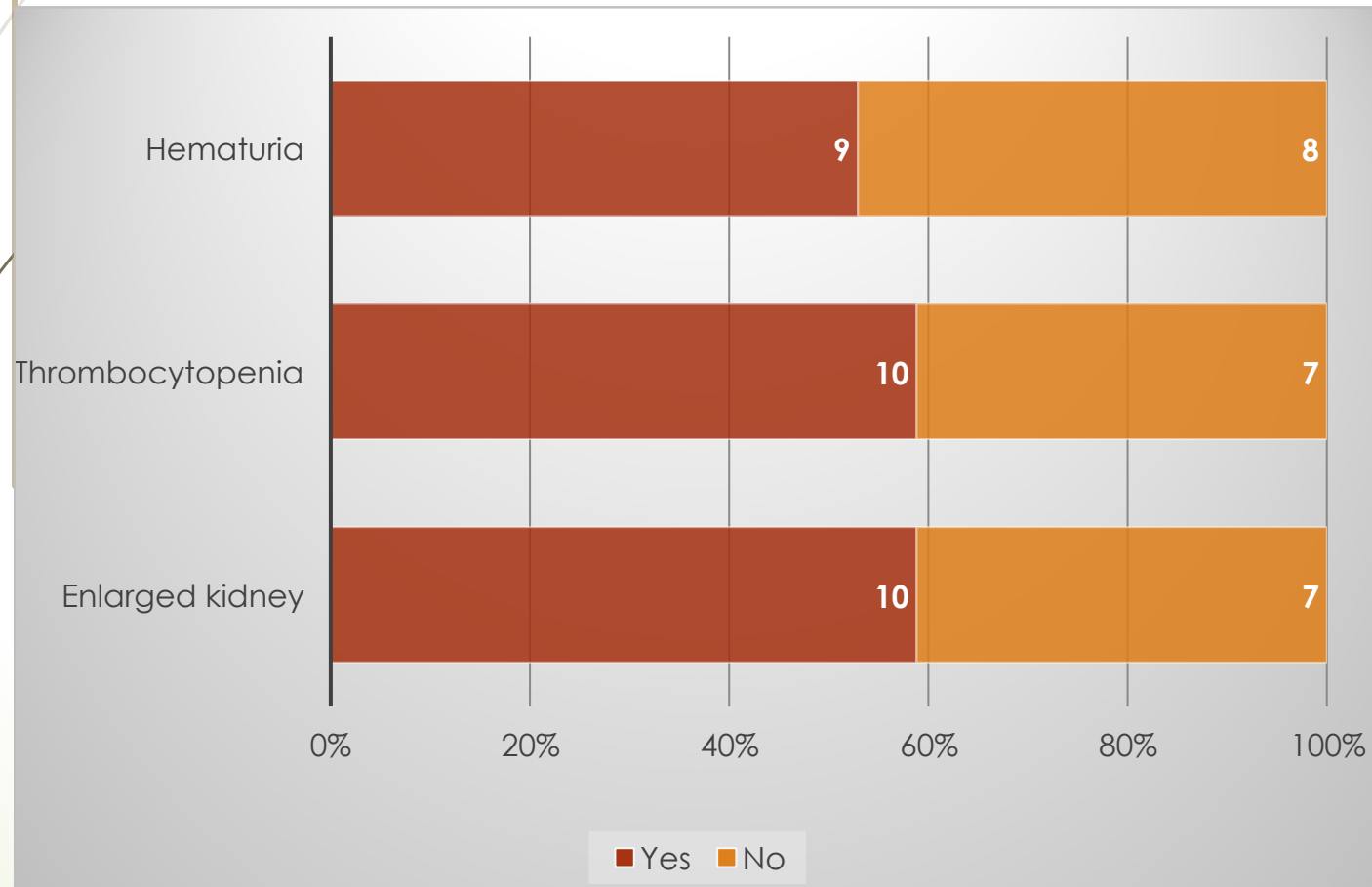
Methods

Retrospective analysis of US images on PACS

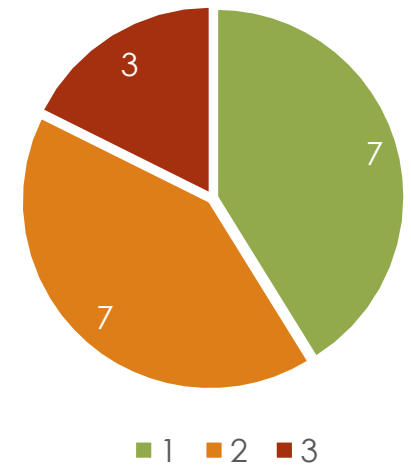
- Side
- Renal size
- CM differentiation, echogenicity
- Echogenic interlobar vascular streaks
- Thrombus: renal vein / extension to IVC
- Adrenal hemorrhage
- Subcapsular collection
- Doppler: venous flow, overall renal flow and main artery resistive index

Results

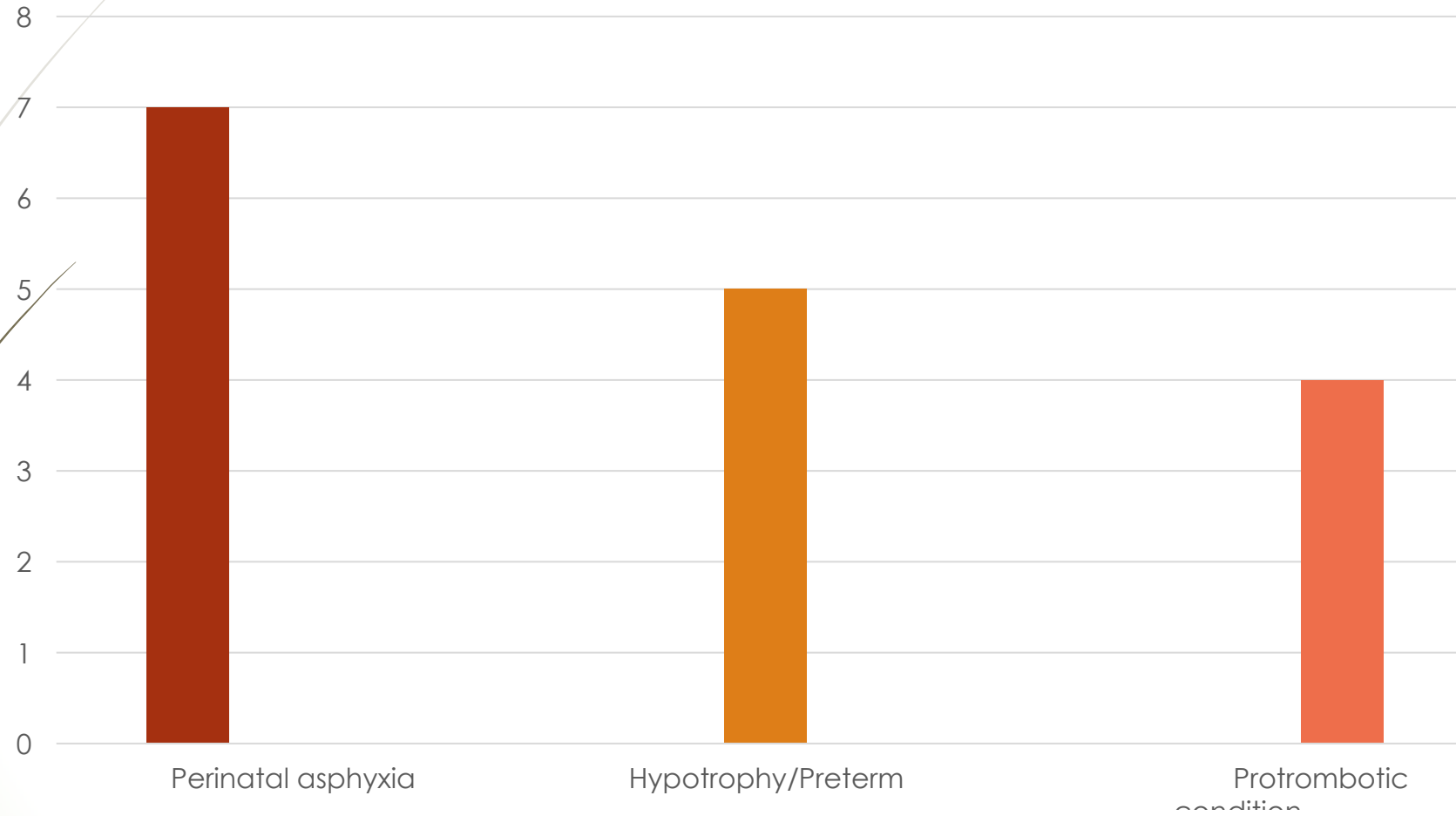
- Median age of diagnosis 5.8 days
- Prenatal enlarged kidney 3
- Post-natal symptoms in all neonates



Number of symptoms

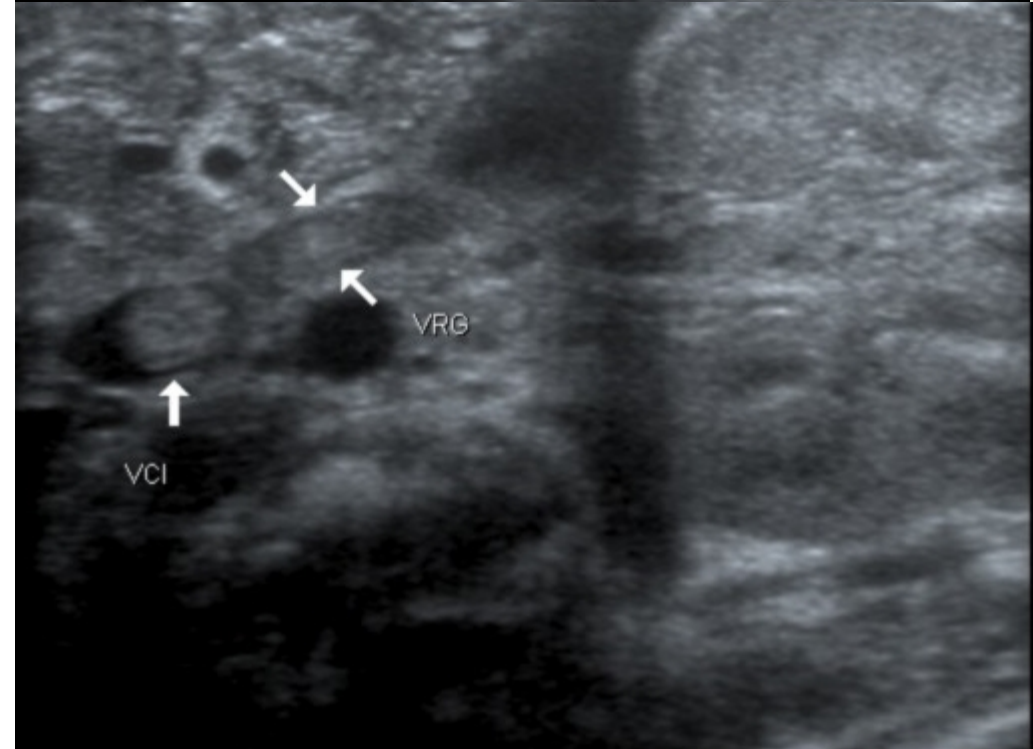
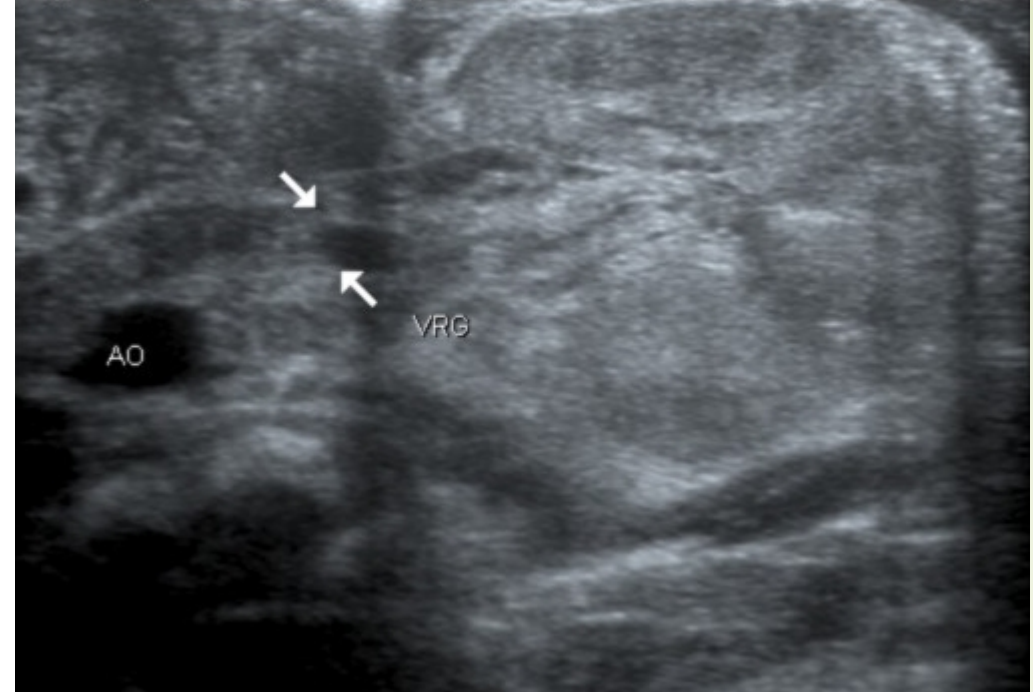


Results – risk factors



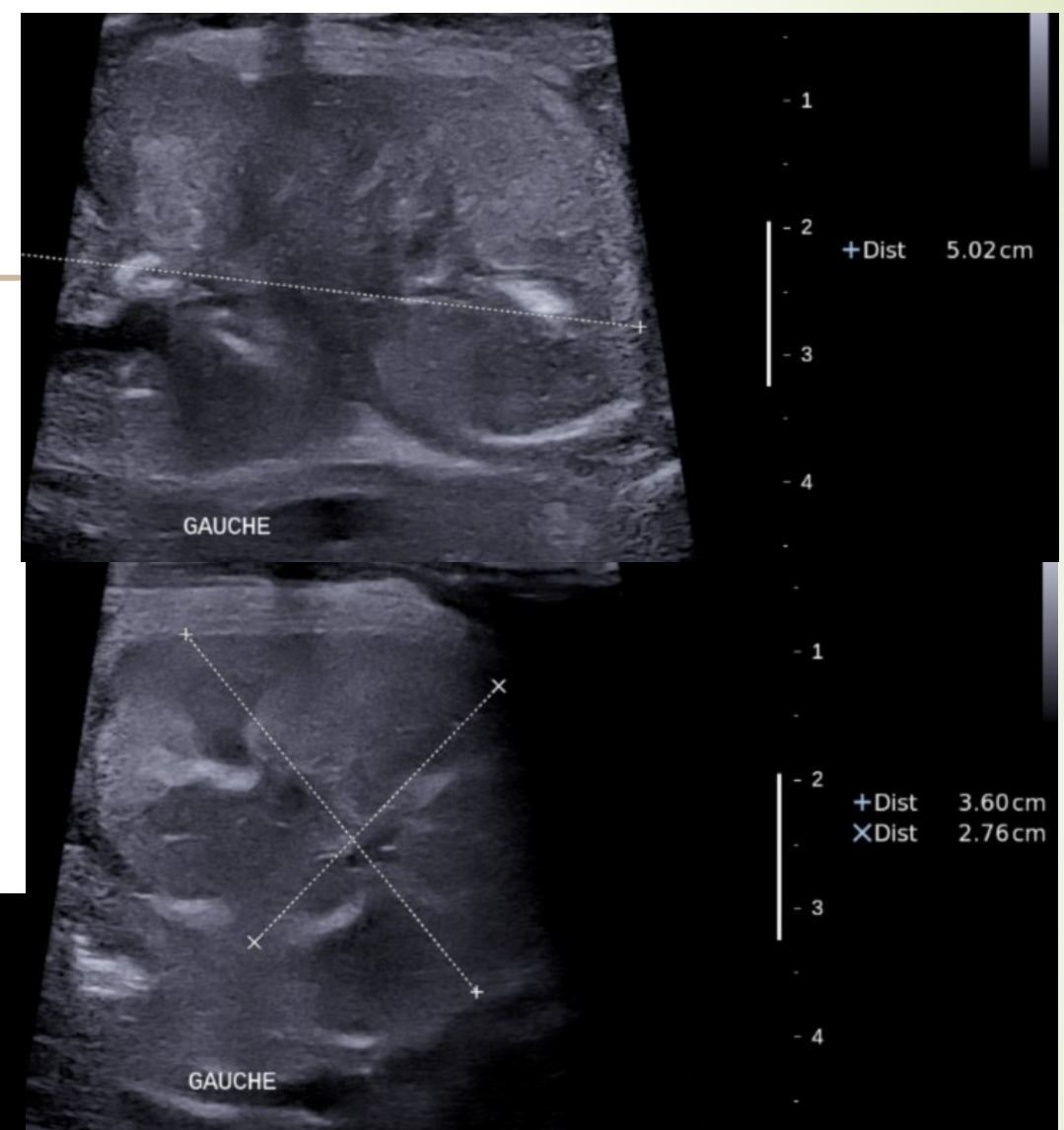
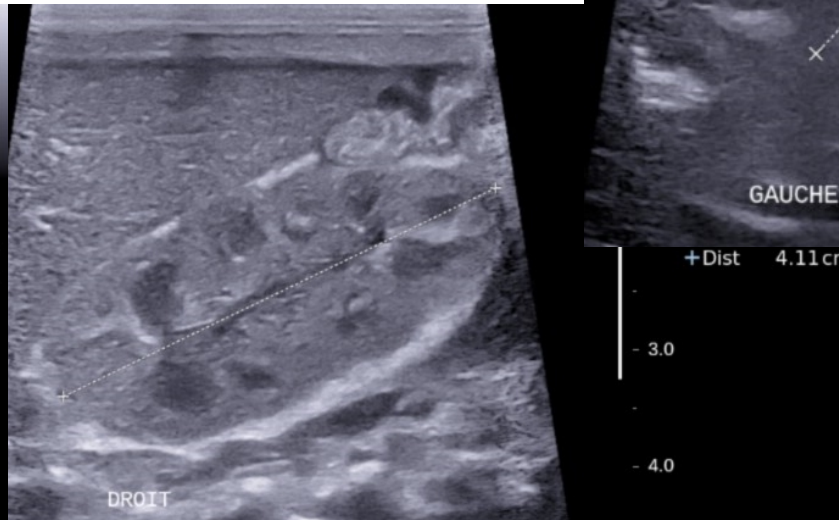
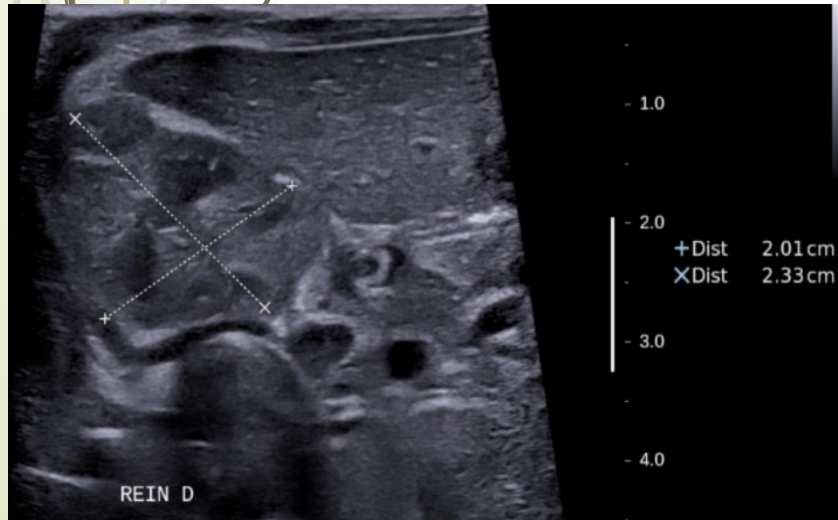
Results - US

- US: diagnosis in all cases
- Left side: 55%
- Venous thrombus in renal vein: 76% (16/21)
- IVC extension: 76% (13/17)



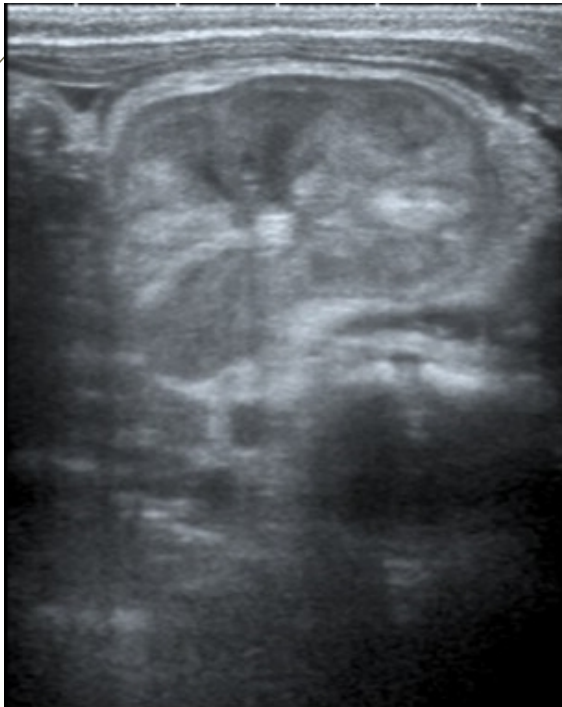Results - US

- Enlarged kidney: 71% (15/21)
- Decreased CMD: 76% (16/21)

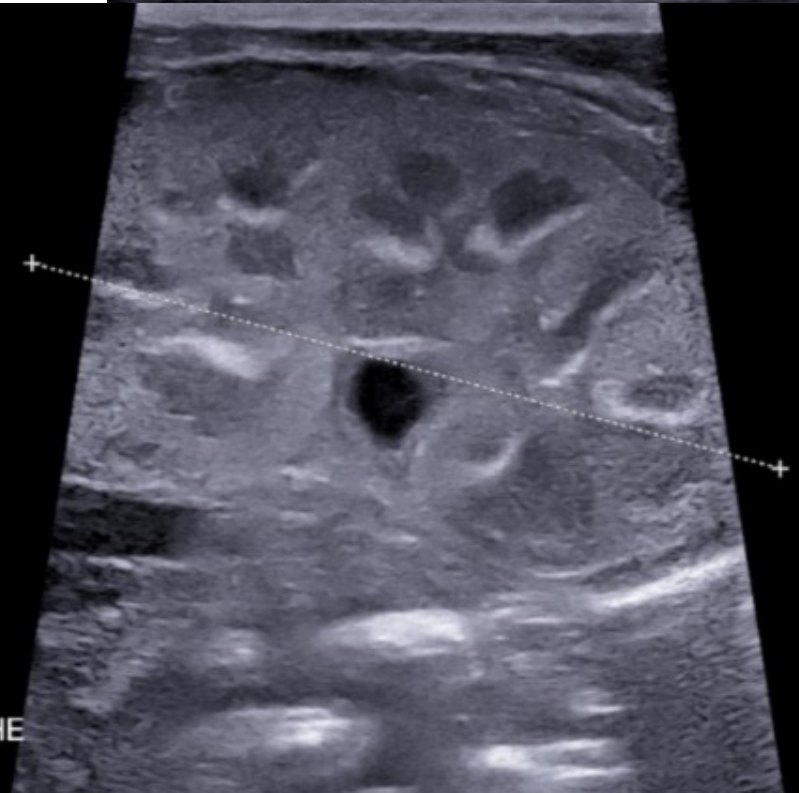
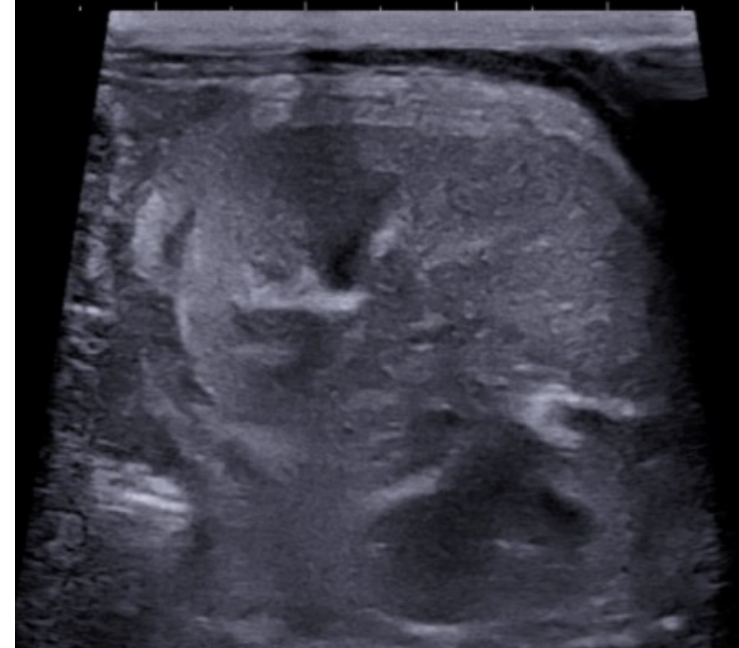
Results - US

➤ Vascular streaks: 52% (11/21)



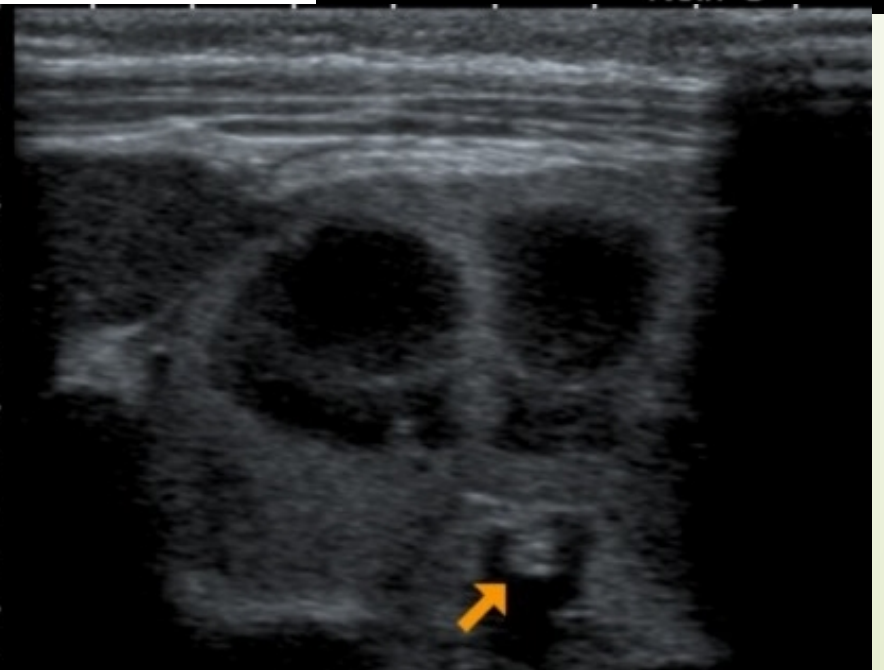
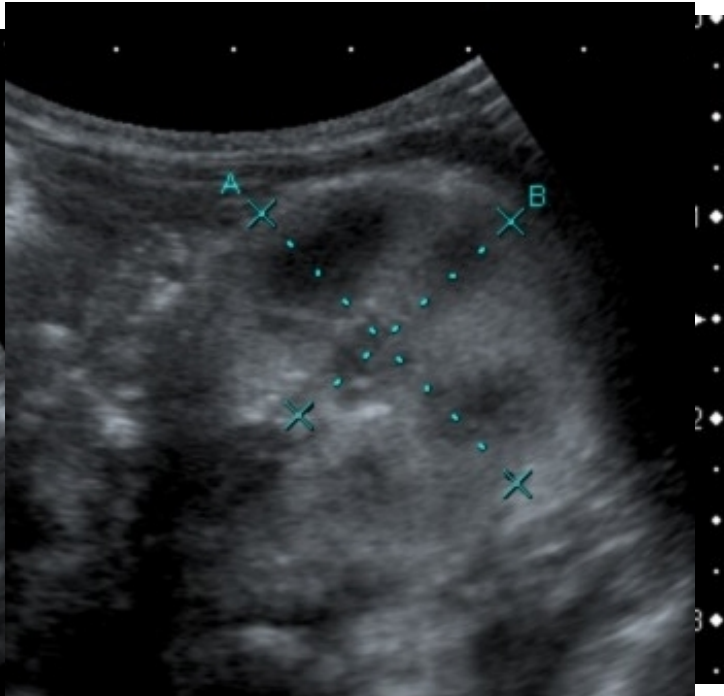
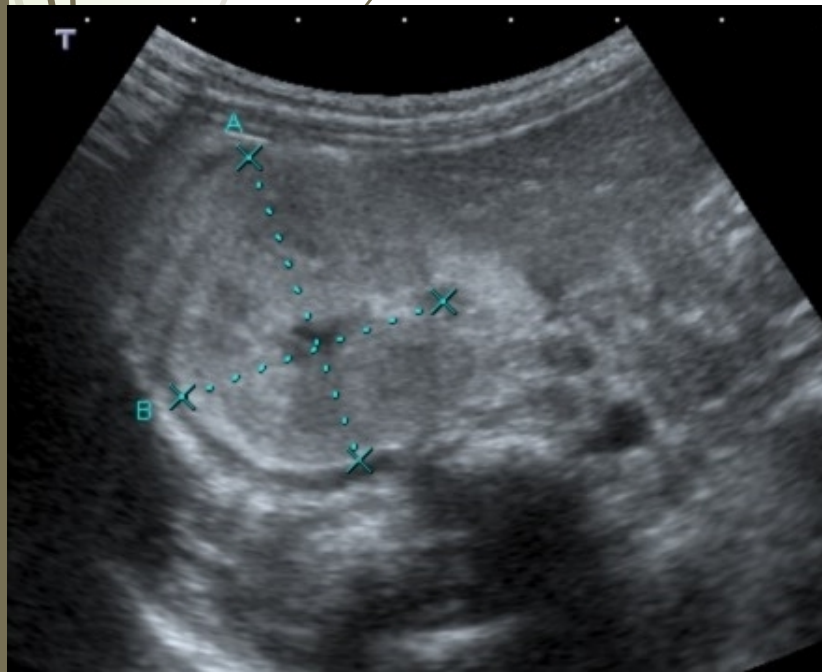
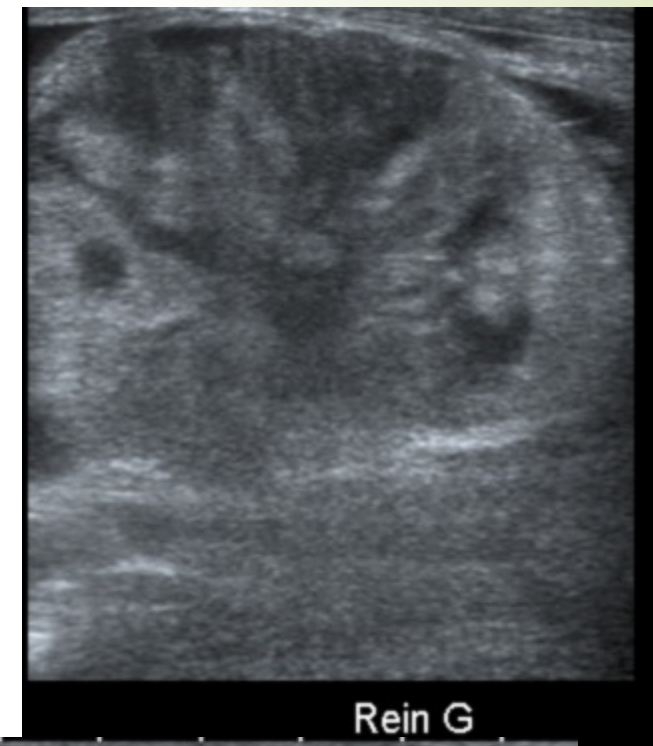Rein G



REIN GAUCHE

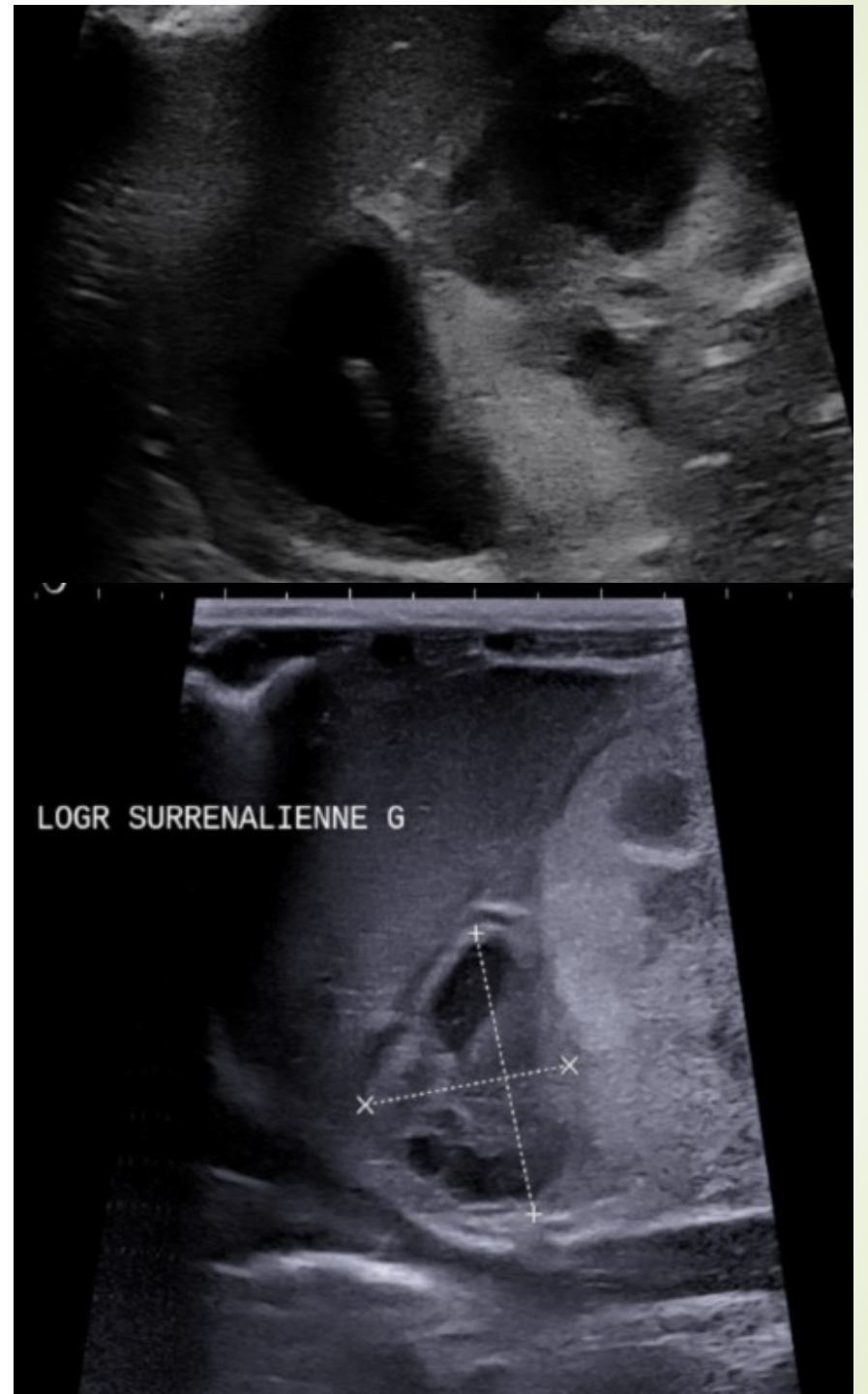
Results - US

- ➡ Heterogeneous cortex 19 % (4/21)
- ➡ Hypoechoic pyramids 33% (7/21)



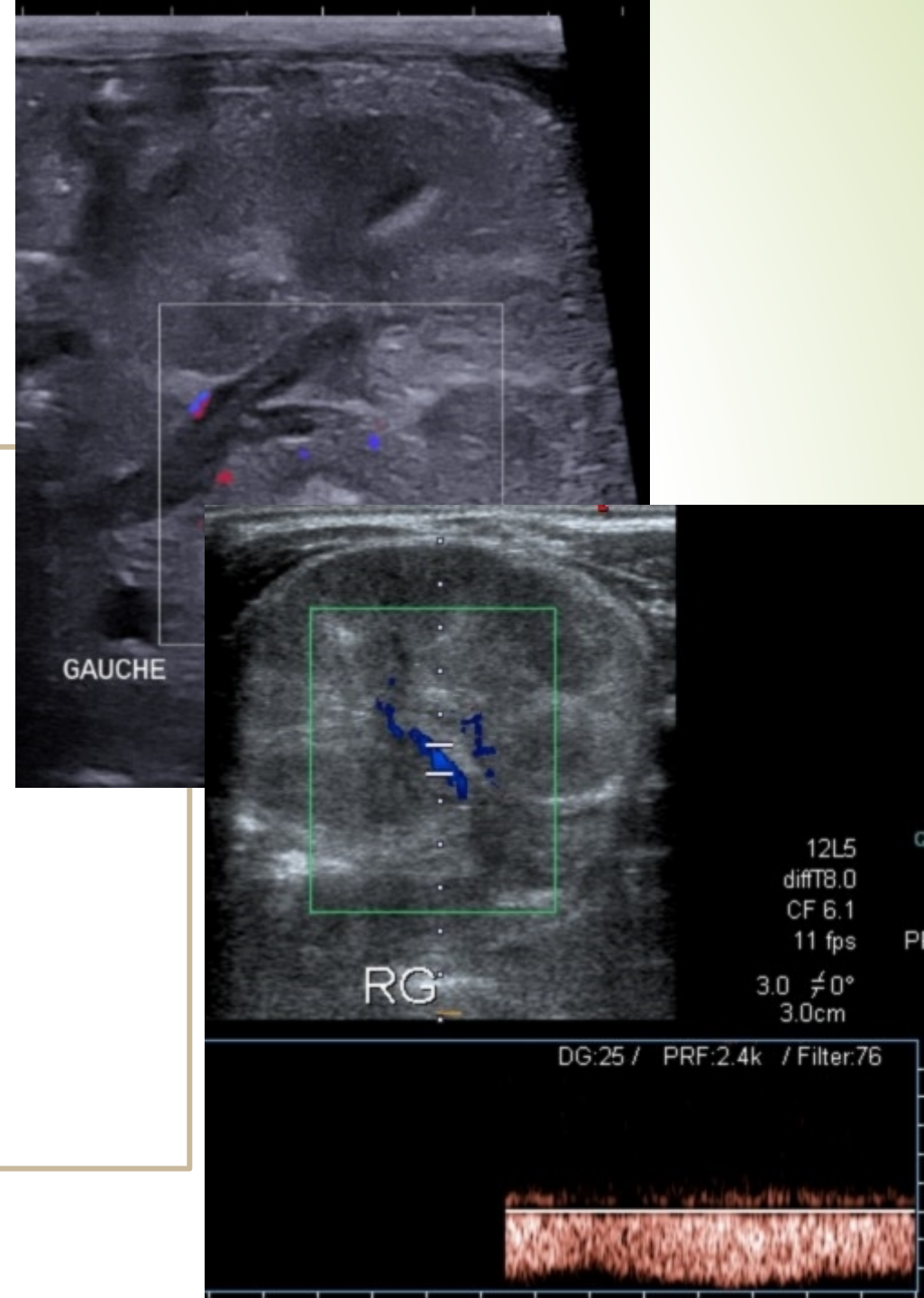
Results - US

- Adrenal hemorrhage
11/21 (52%)
- No subcapsular
collection in our series



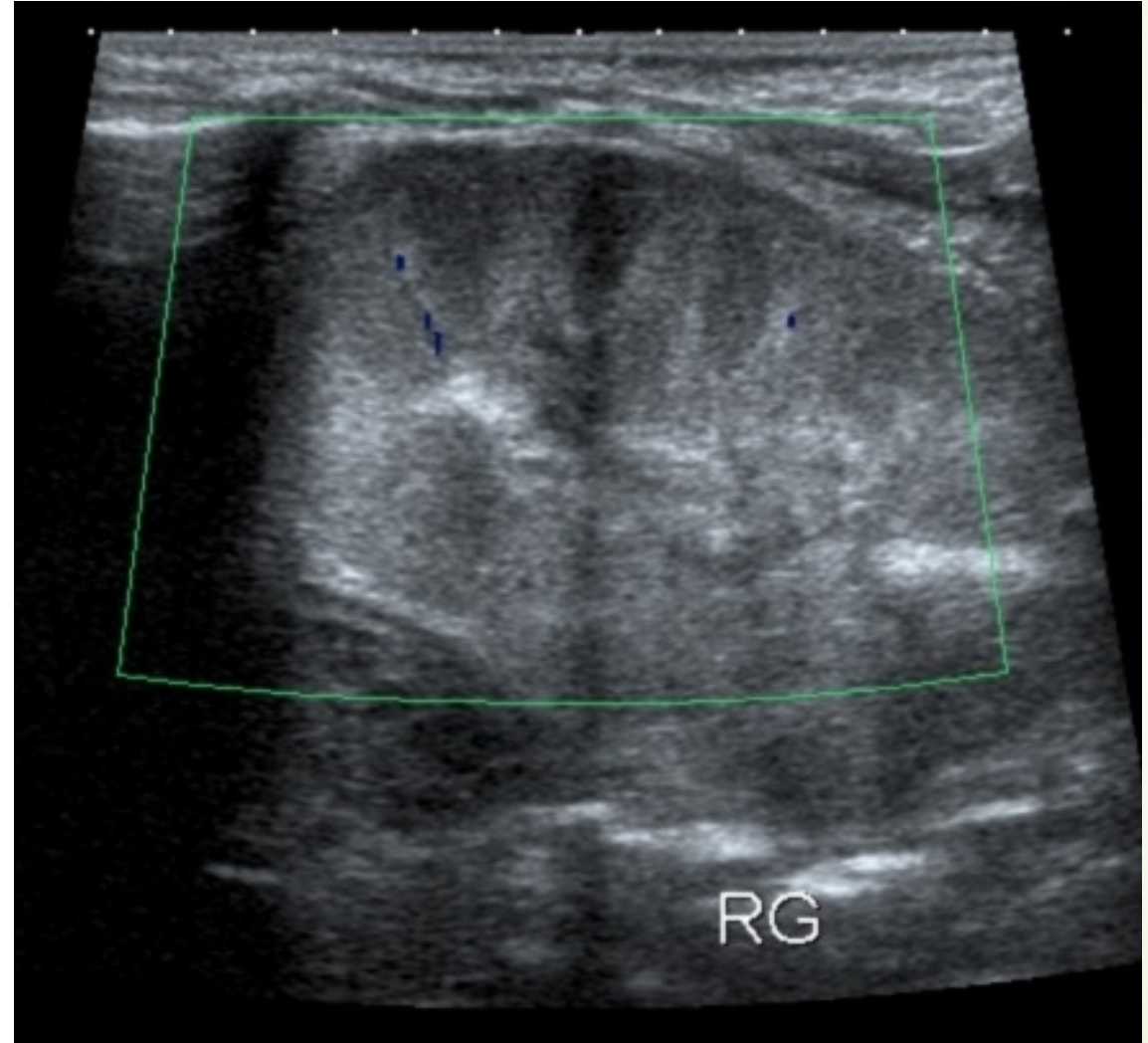
Results – Doppler

- **Abnormal venous flow: 80% (16/20)**
- Overall decreased renal flow: 80% (8/10)
- Reverse flow or increased RI: 55% (10/18)



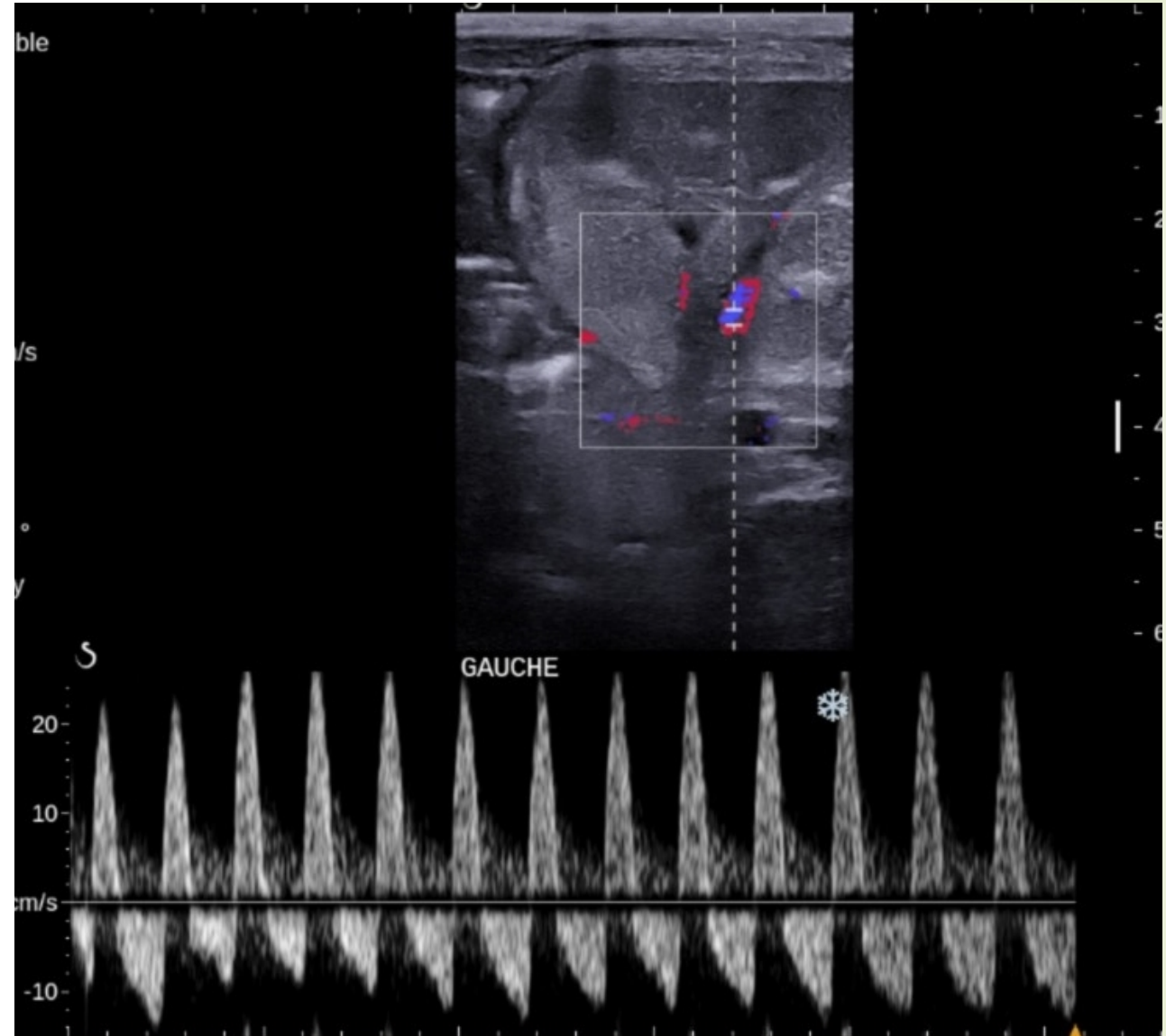
Results – Doppler US

- Abnormal venous flow
16/20 80%
- **Overall decreased renal flow 8/10 80%**
- Reverse flow or increased RI
10/18 55%



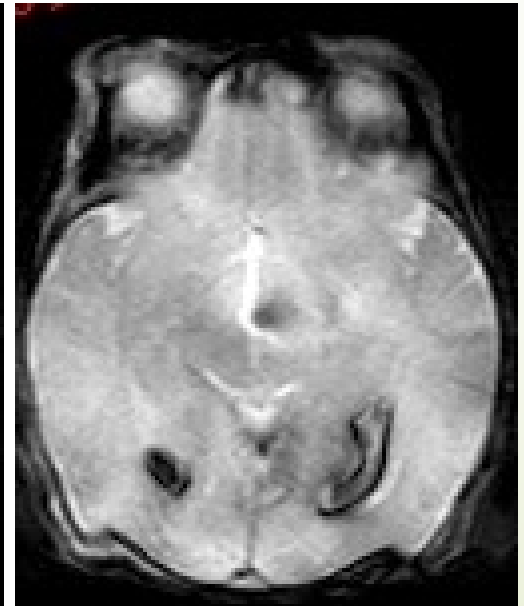
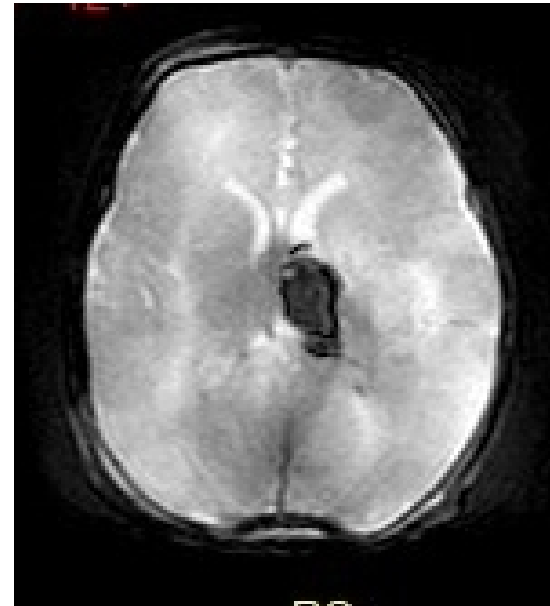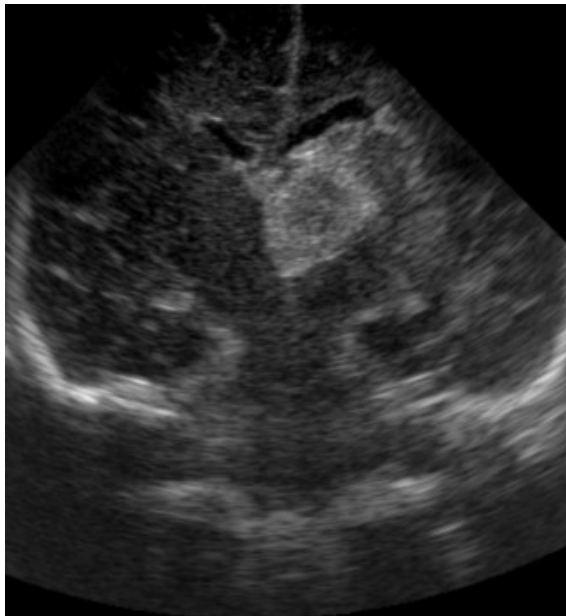
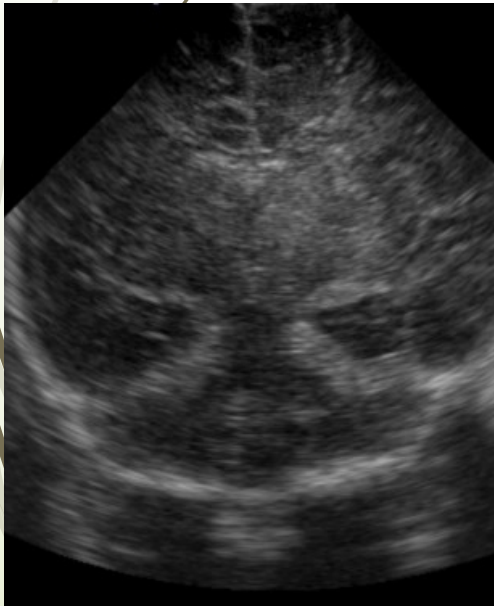
Results – Doppler US

- Abnormal venous flow
16/20 80%
- Overall decreased renal flow 8/10 80%
- **Reverse flow or increased RI**
10/18 55%



Results - treatment

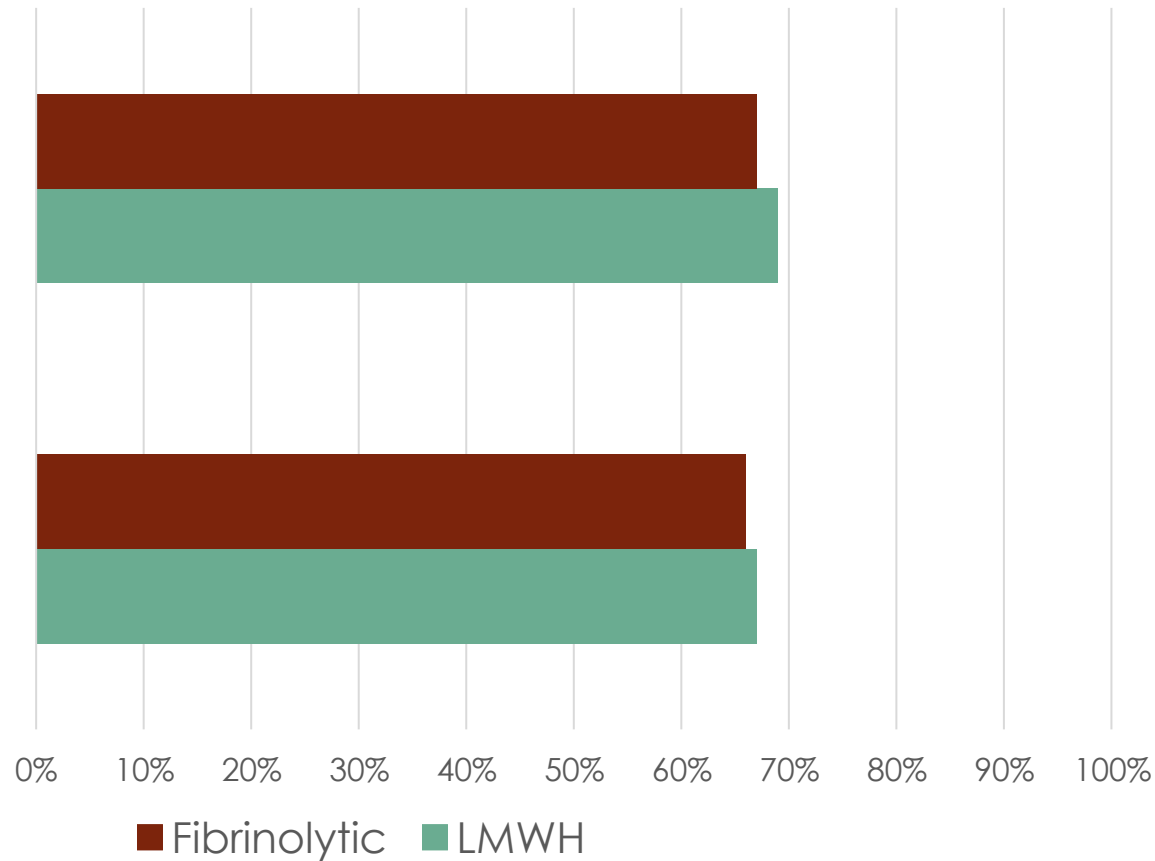
- Mean follow-up : 7 years (1 to 17 years)
- Thrombolytic treatment: **3 neonates** with bilateral thrombosis
 - ➔ **2 brain hemorrhagic complications** with neurologic sequelae
 - ➔ **14 neonates** received **LMWH** with **no hemorrhagic** complication



Results: follow up imaging

Partial or complete
recanalization

Renal atrophy





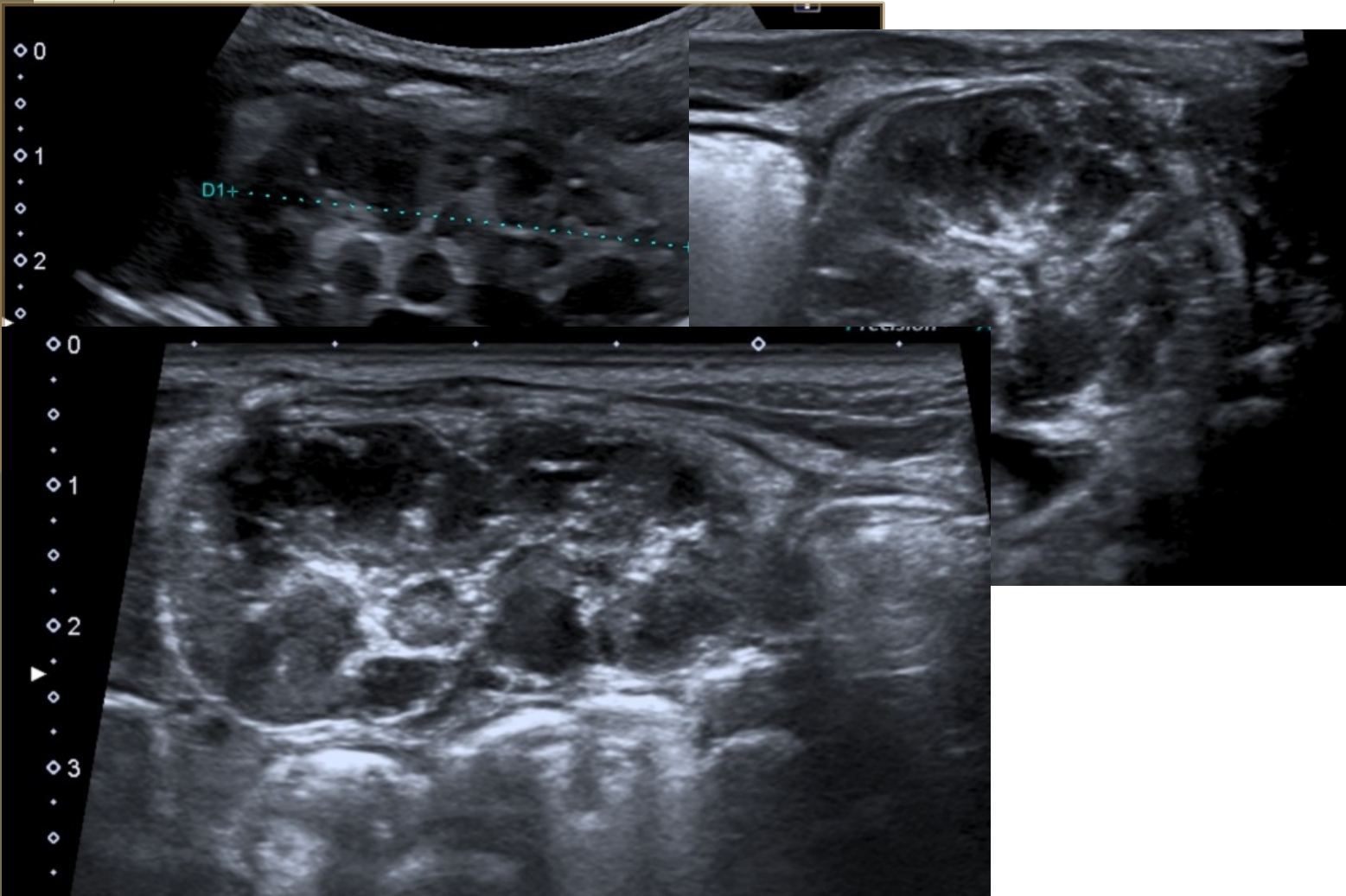
Results – US prognosis markers of renal atrophy

All patients with :

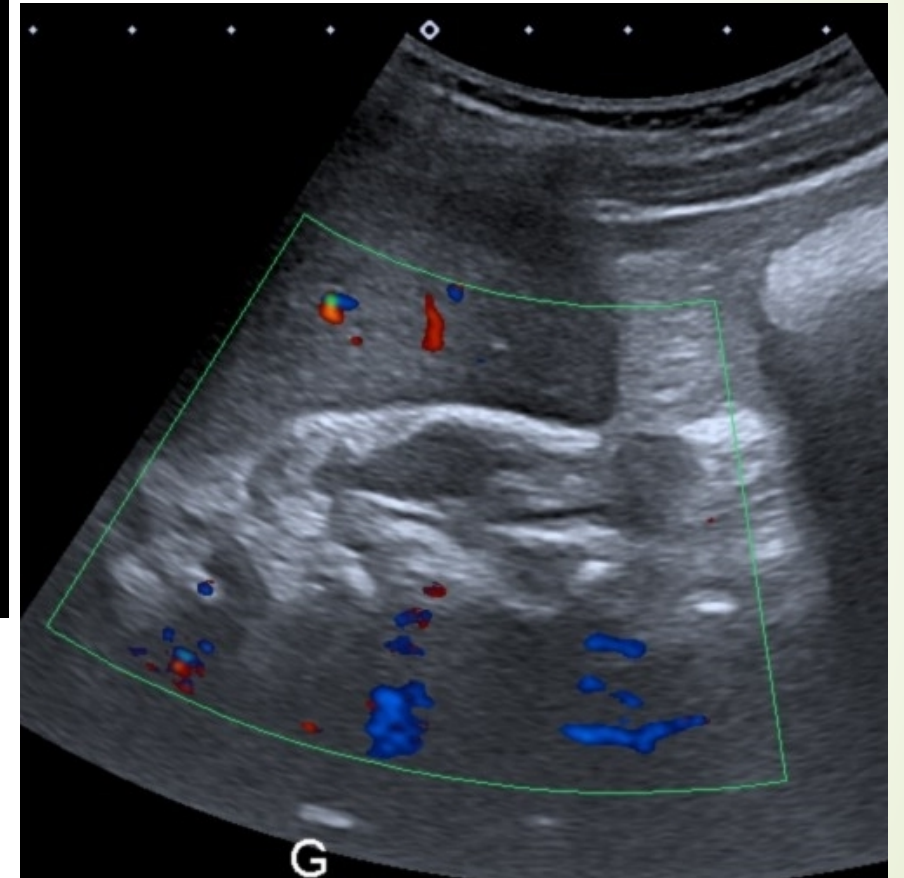
- Vascular streaks (11)
- Profound hypoechoic and irregular pyramids (7)
- Heterogenous cortex (4)
- Decreased overall renal flow (7)

→ Progressed to renal atrophy

Results – renal atrophy



18 days



1 year



Conclusion



- Best diagnostic features : Thrombus, nephromegaly, vascular streaks, overall kidney vascularization. Adrenal hemorrhage alarm sign.
- **Poor prognosis : renal atrophy in 2/3**
 - Profound hypoechoic and irregular pyramids
 - Heterogeneous cortex
 - Decreased overall renal flow
 - Vascular streaks ?
- **No benefit of fibrinolytic vs LMWH** / severe hemorrhagic complications

Thanks for your attention





BIBLIOGRAPHIE



- 1. Elsaify WM. Neonatal renal vein thrombosis: grey-scale and Doppler ultrasonic features. *Abdom Imaging*. 2009 May-Jun;34(3):413-8. doi: 10.1007/s00261-008-9394-6. PMID: 18404284.
- 2. Kraft JK, Brandão LR, Navarro OM. Sonography of renal venous thrombosis in neonates and infants: can we predict outcome? *Pediatr Radiol*. 2011 Mar;41(3):299-307. doi: 10.1007/s00247-010-1817-1. Epub 2010 Aug 24. PMID: 20734037.
- 3. Lau KK, Stoffman JM, Williams S, McCusker P, Brandao L, Patel S, et al. Neonatal renal vein thrombosis: review of the English-language literature between 1992 and 2006. *Pediatrics*. nov 2007;120(5):e1278-1284.