



ESPR
European Society of
Paediatric Radiology

56th Annual Meeting &
42nd Post Graduate Course
June 06 - 10 2022



Ear, nose and throat and ophthalmology Challenging cases showing mimics and pitfalls

Lorenzo Ugga

Department of Advanced Biomedical Sciences, University of Naples "Federico II"

lorenzo.ugga@unina.it



Disclosure

I have no conflicts of interest to disclose



Challenging cases showing mimics and pitfalls

Vascular anomalies

Cystic lesions

Solid lesions



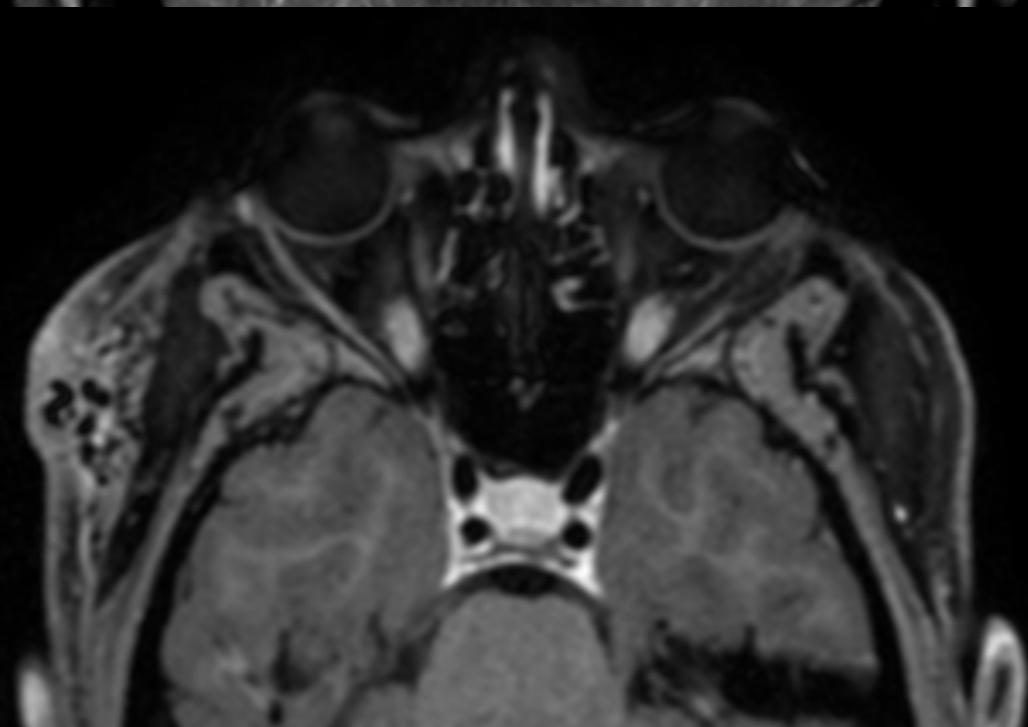
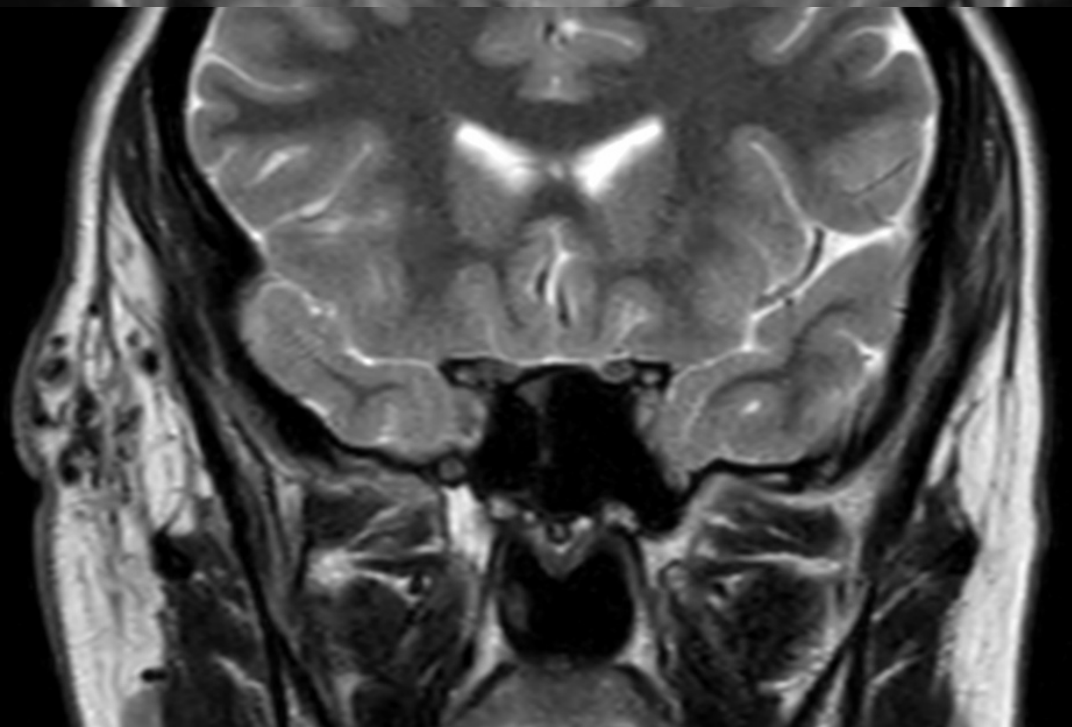
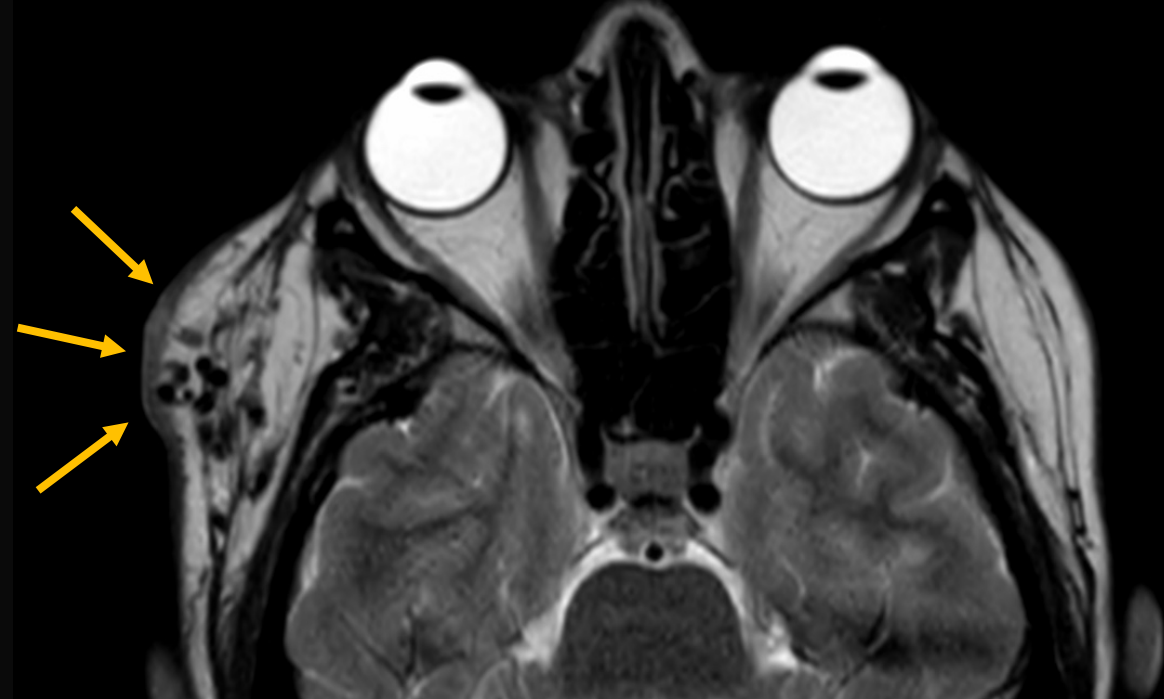
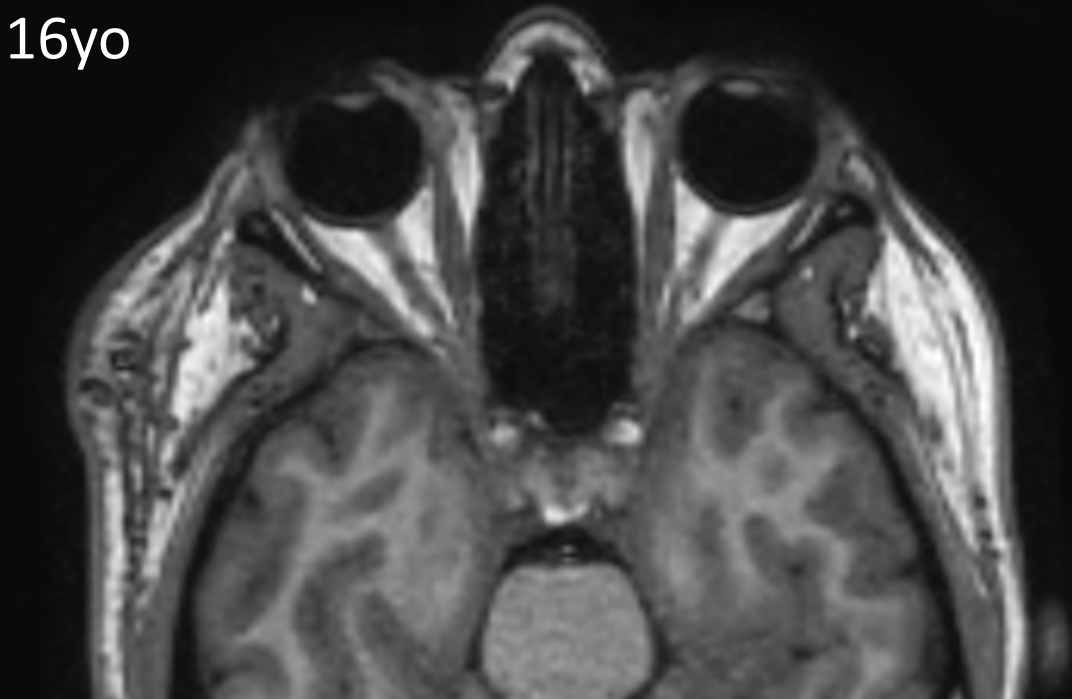
Challenging cases showing mimics and pitfalls

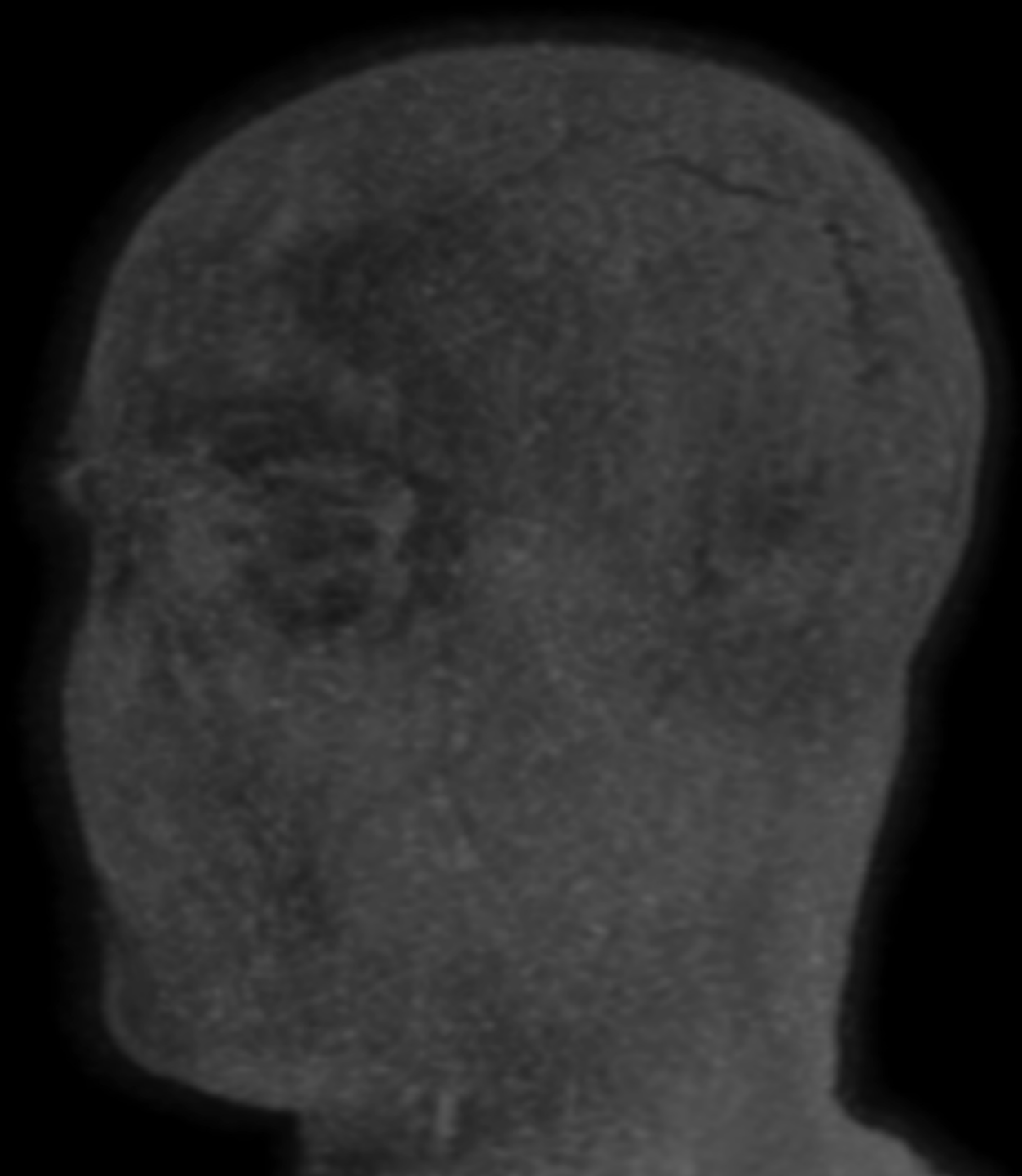
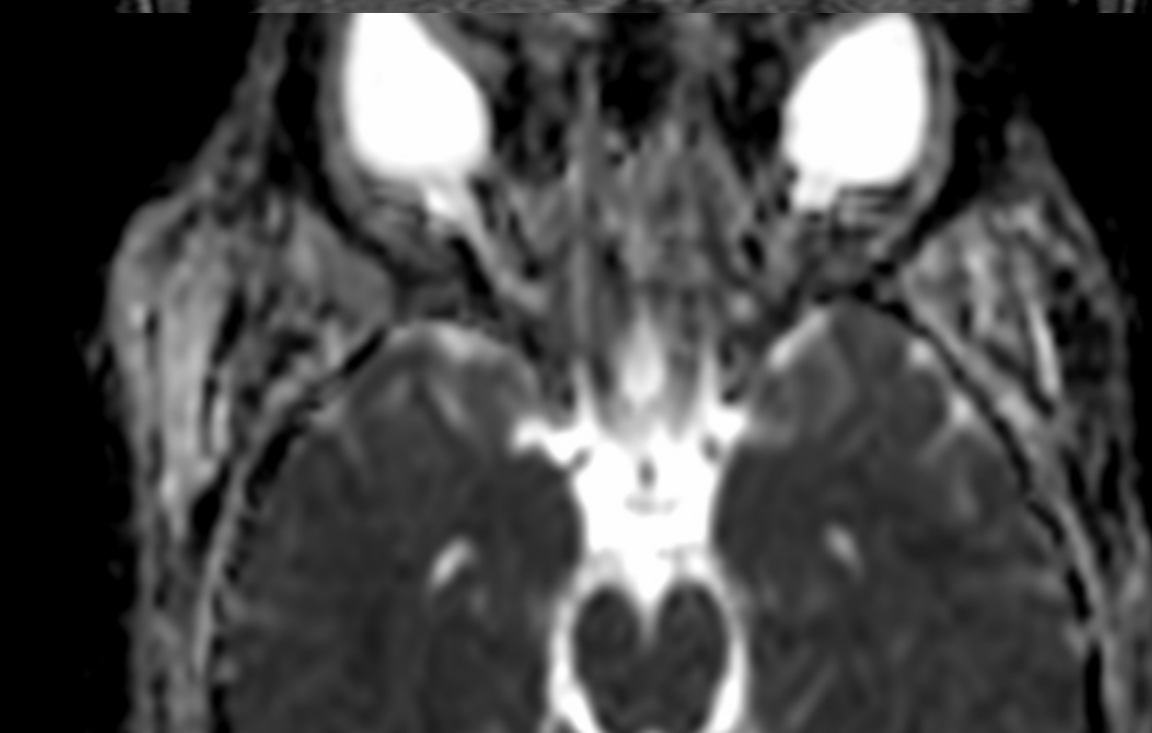
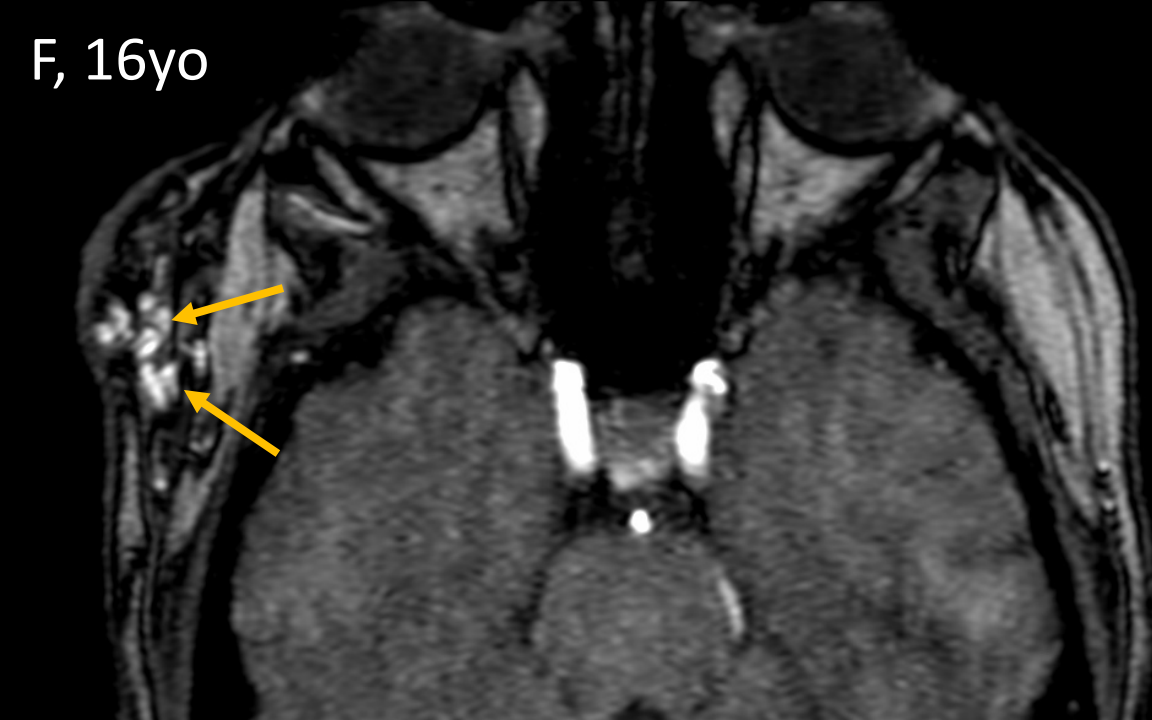
Vascular anomalies

Cystic lesions

Solid lesions

F, 16yo





ISSVA classification for vascular anomalies

Last revision May 2018

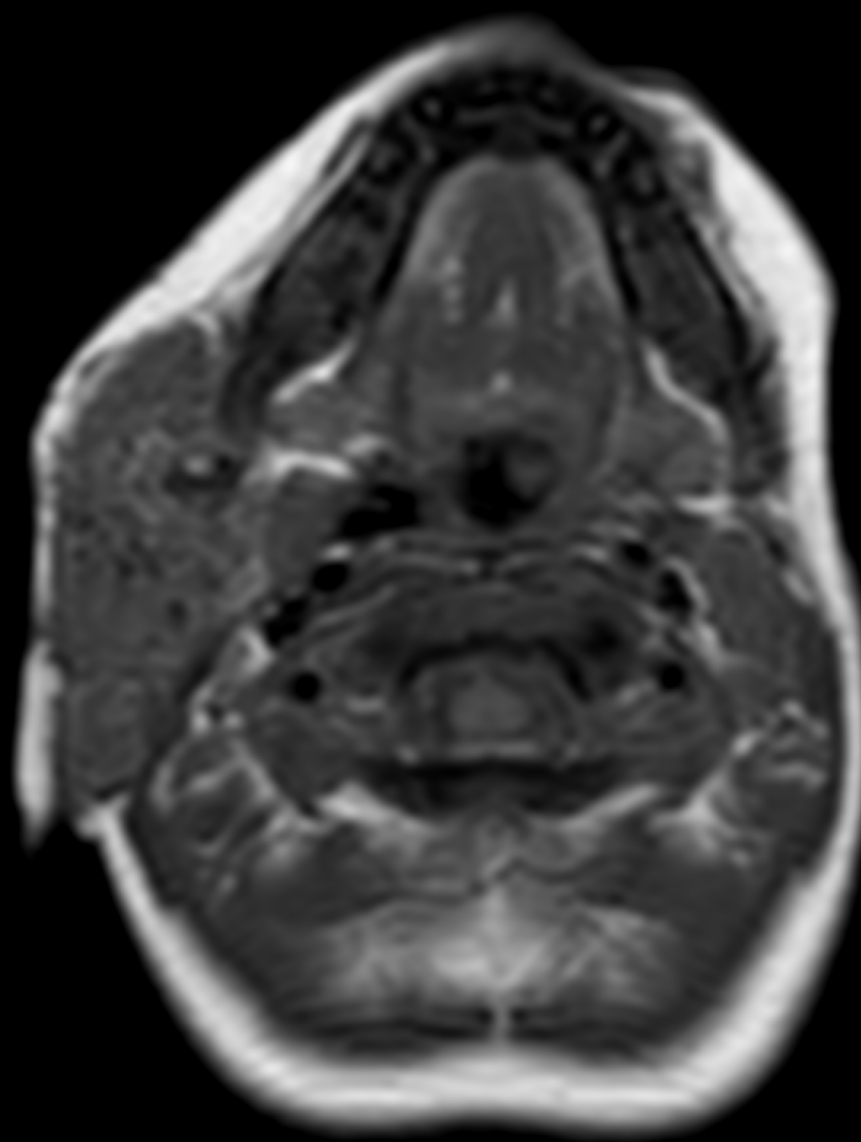
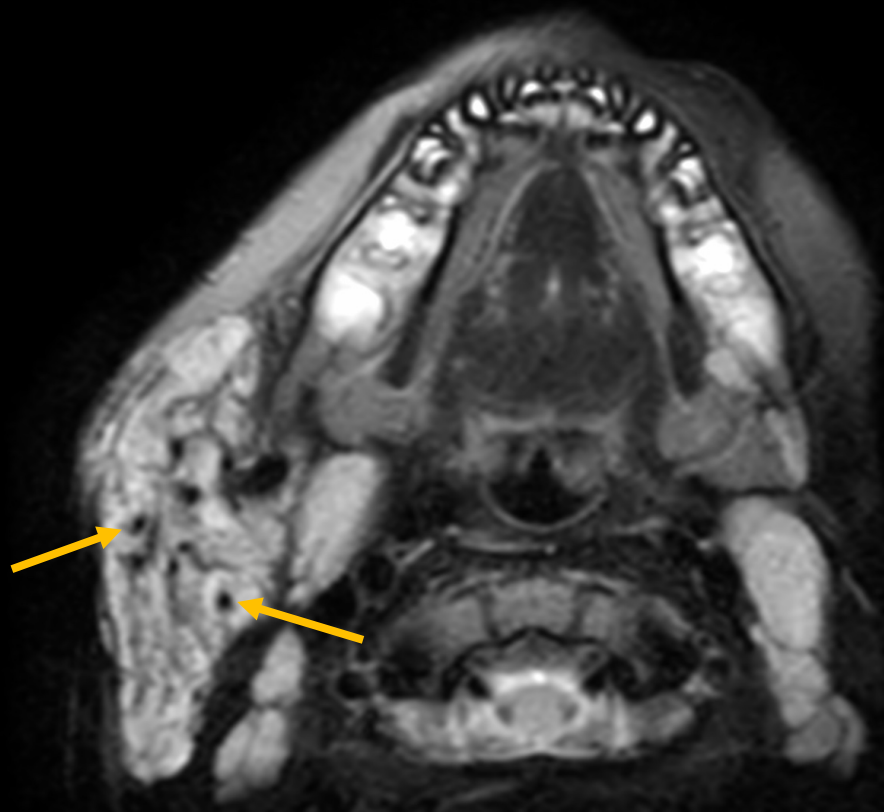Vascular anomalies				
Vascular tumors	Vascular malformations			
	Simple	Combined °	of major named vessels	associated with other anomalies
Benign Locally aggressive or borderline Malignant	Capillary malformations Lymphatic malformations Venous malformations Arteriovenous malformations* Arteriovenous fistula*	CVM, CLM LVM, CLVM CAVM* CLAVM* others	See details	See list

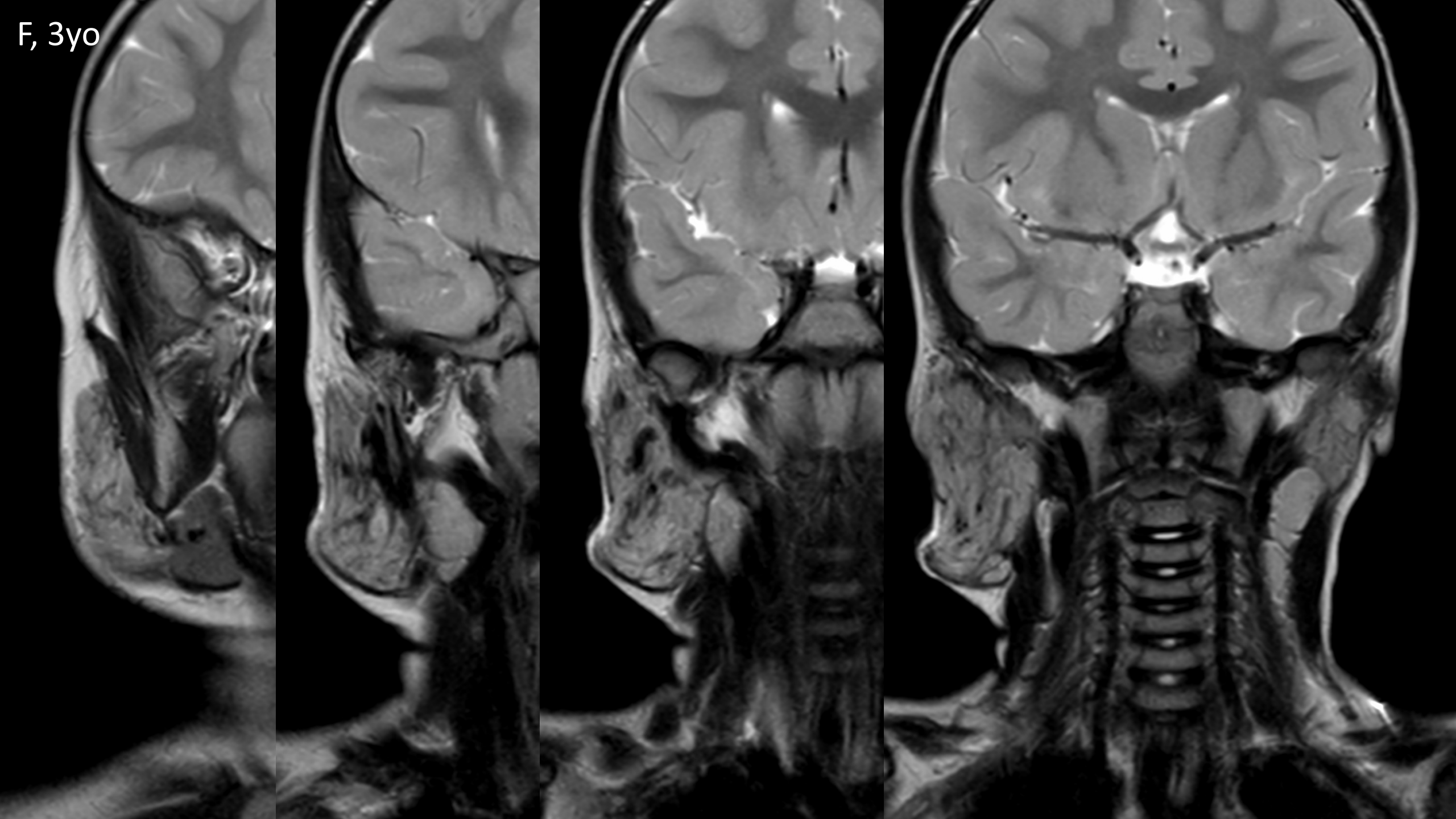
ISSVA classification for vascular anomalies

Last revision May 2018

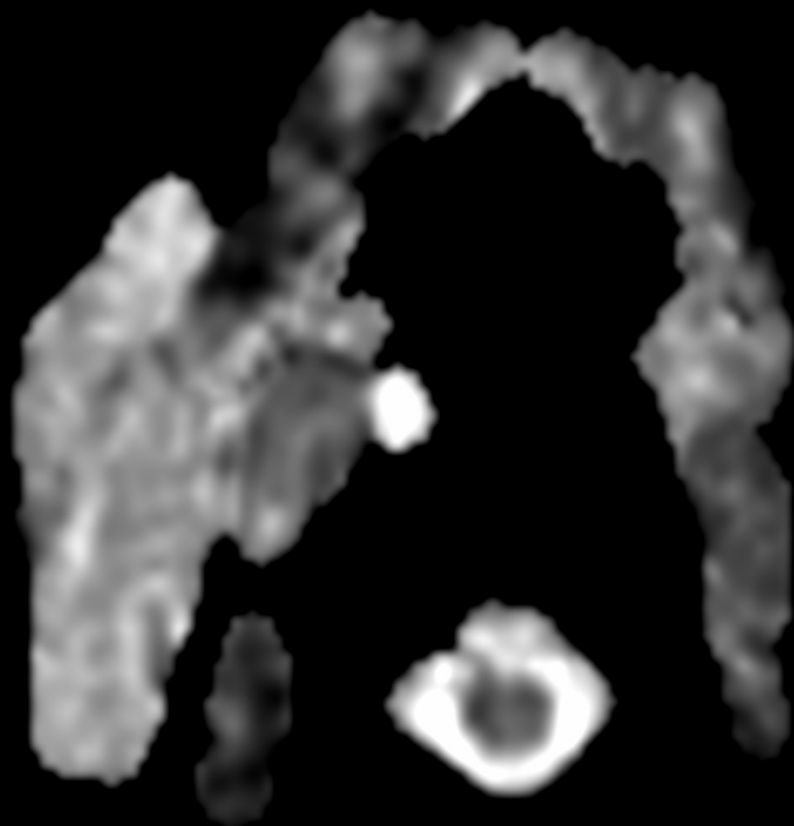
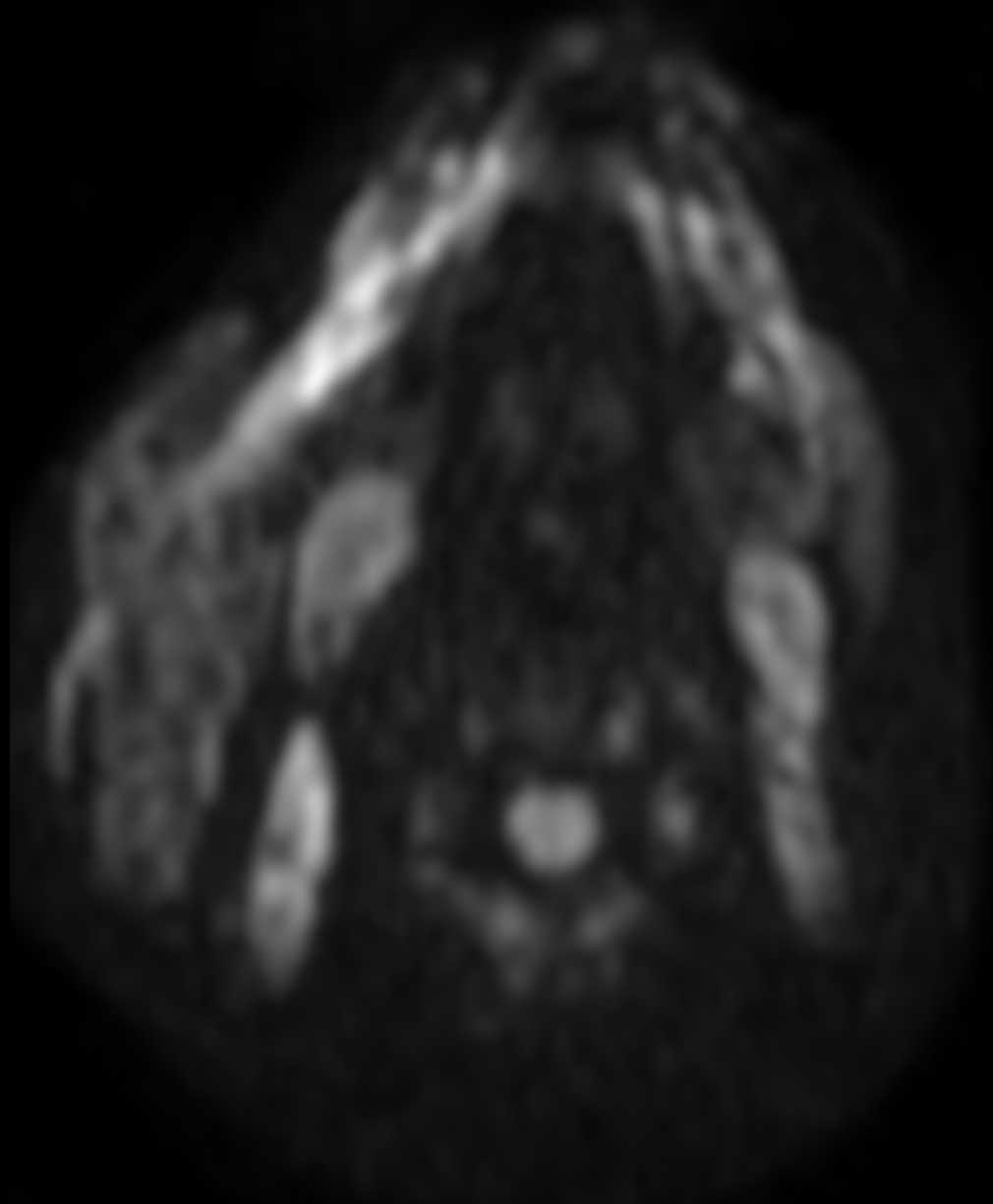
Simple vascular malformations IV	
Arteriovenous malformations (AVM)	
Sporadic	MAP2K1
In HHT	(HHT1 ENG , HHT2 ACVRL1 , HHT3, JPHT SMAD4)
In CM-AVM	RASA1 / EPHB4
Others	
Arteriovenous fistula (AVF) (congenital)	
Sporadic	MAP2K1
In HHT	(HHT1 ENG , HHT2 ACVRL1 , HHT3, JPHT SMAD4)
In CM-AVM	RASA1 / EPHB4
Others	

F, 3yo

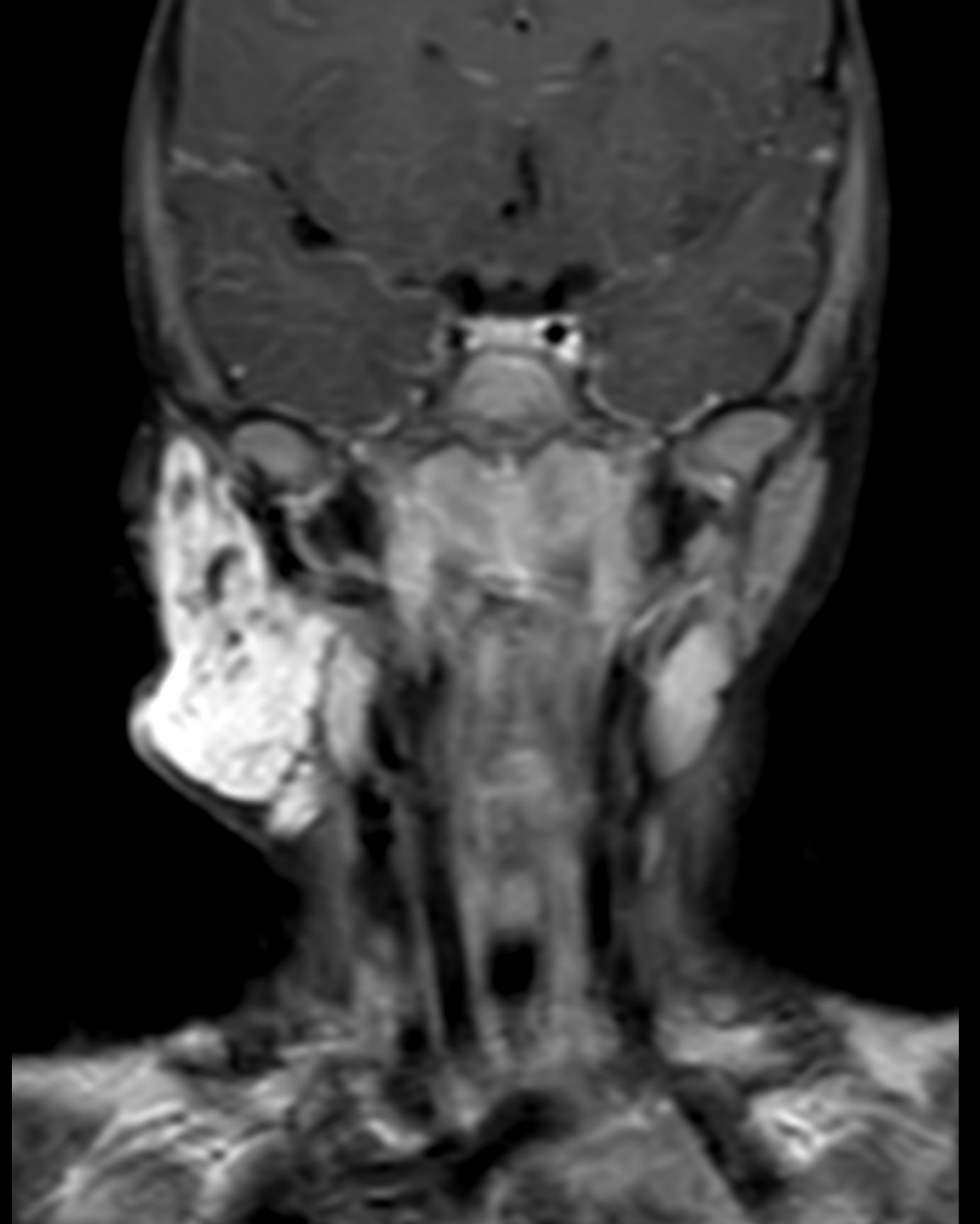
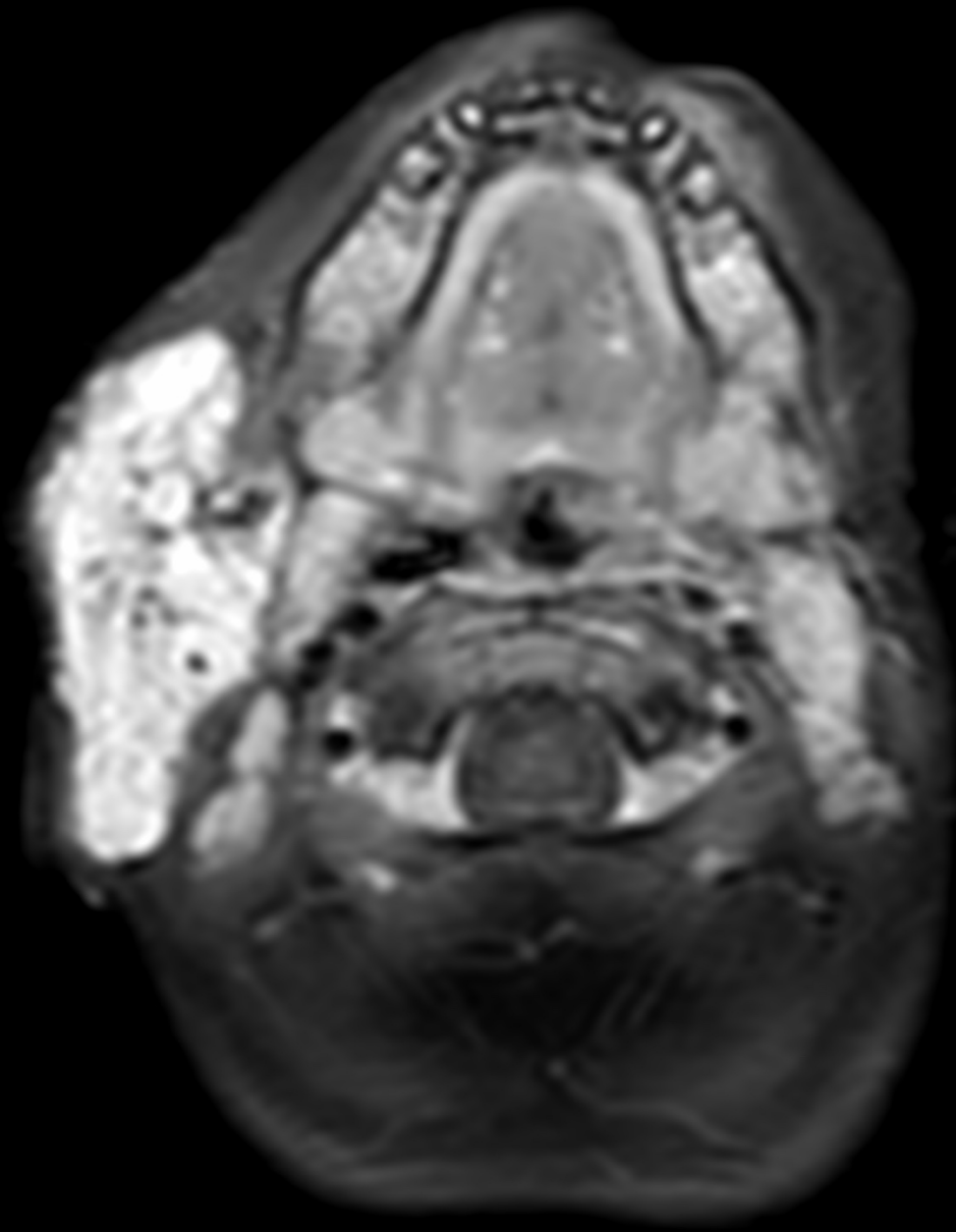




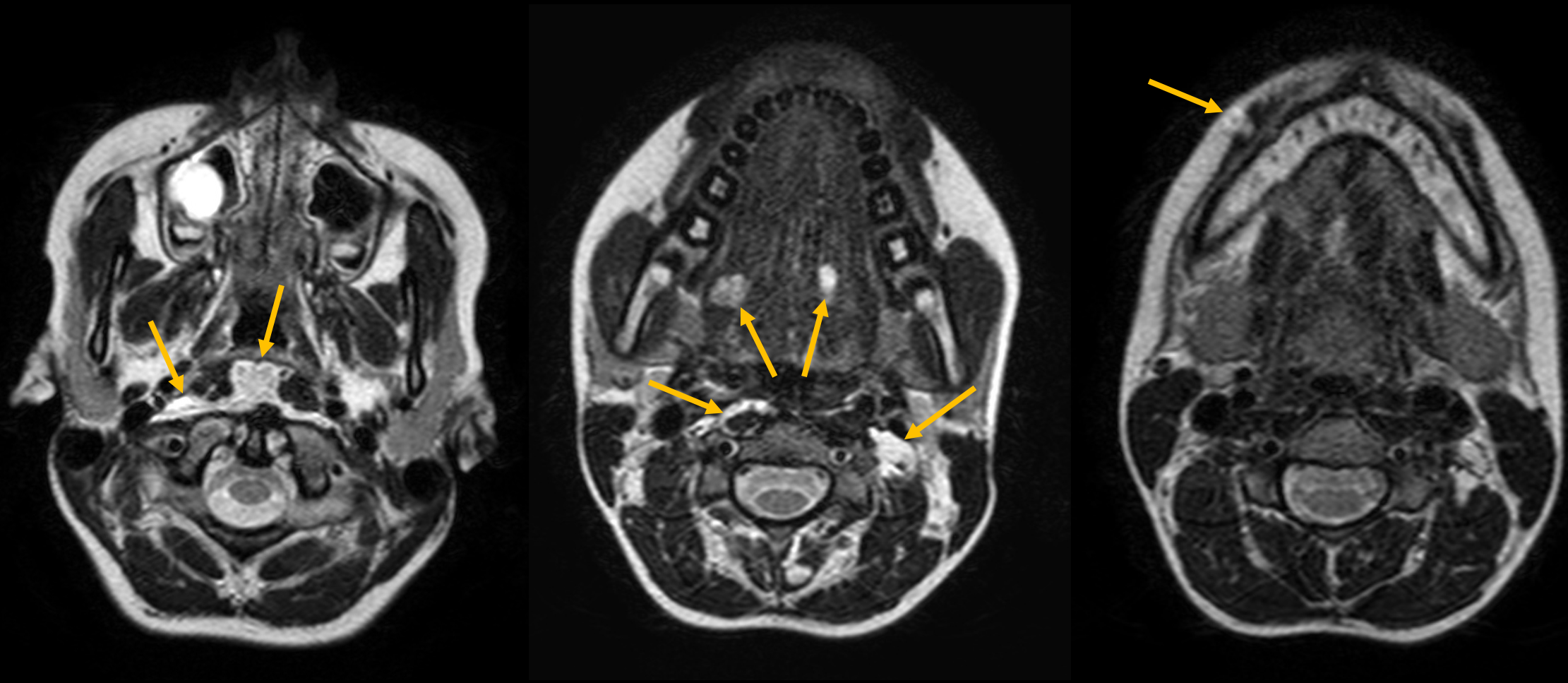
F, 3yo



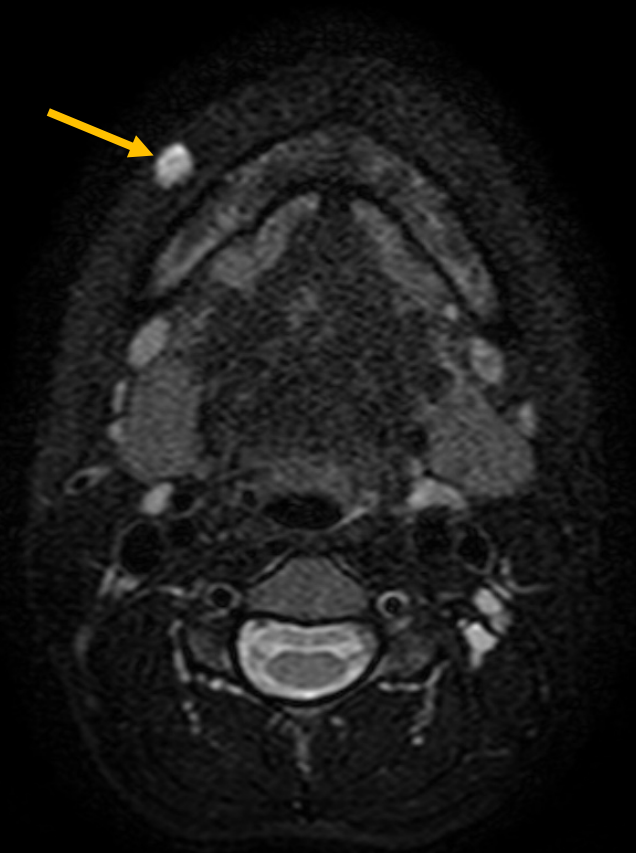
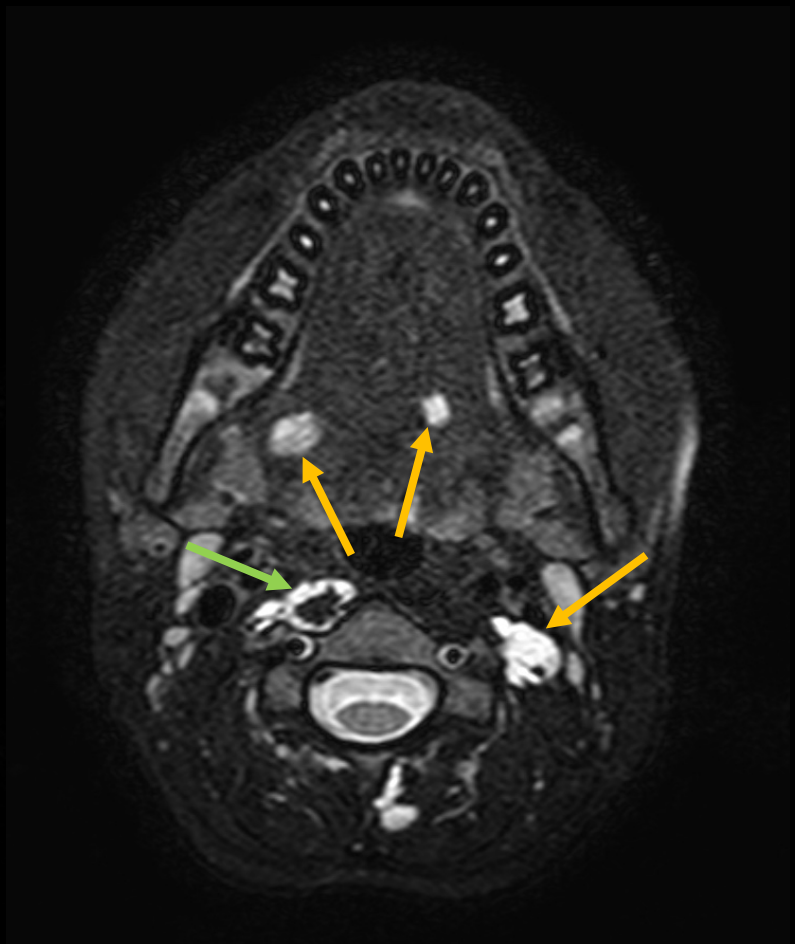
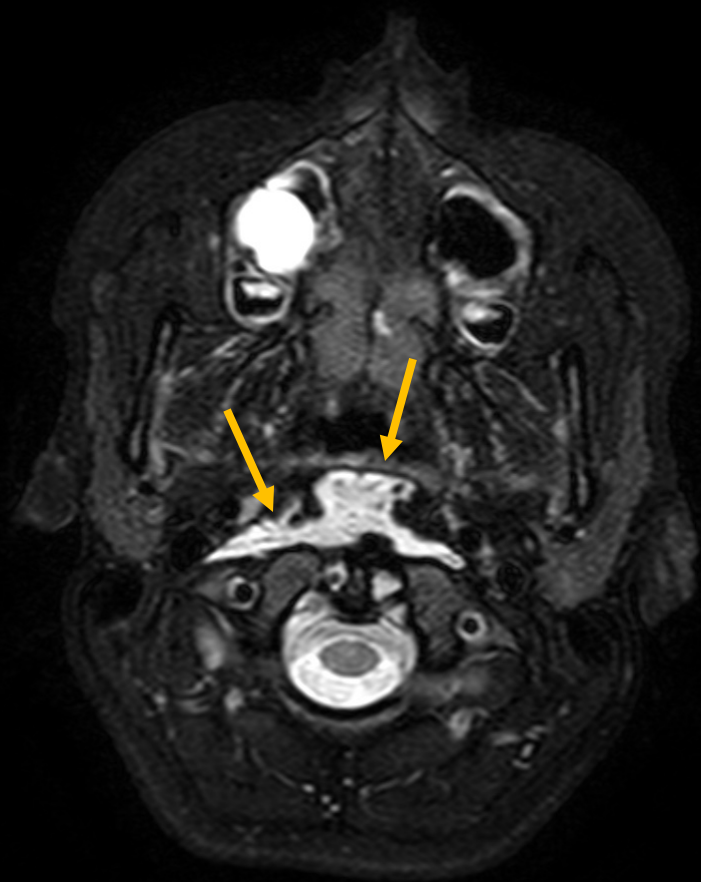
F, 3yo



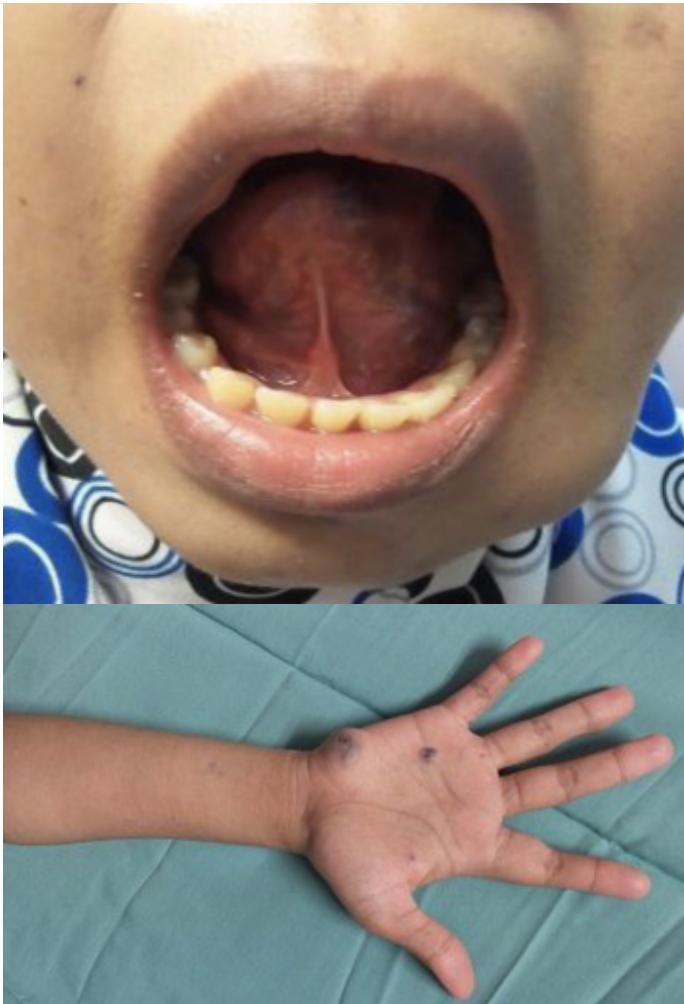M, 10yo



M, 10yo



Blue rubber bleb nevus syndrome



AKA Bean syndrome

Multifocal venous malformations

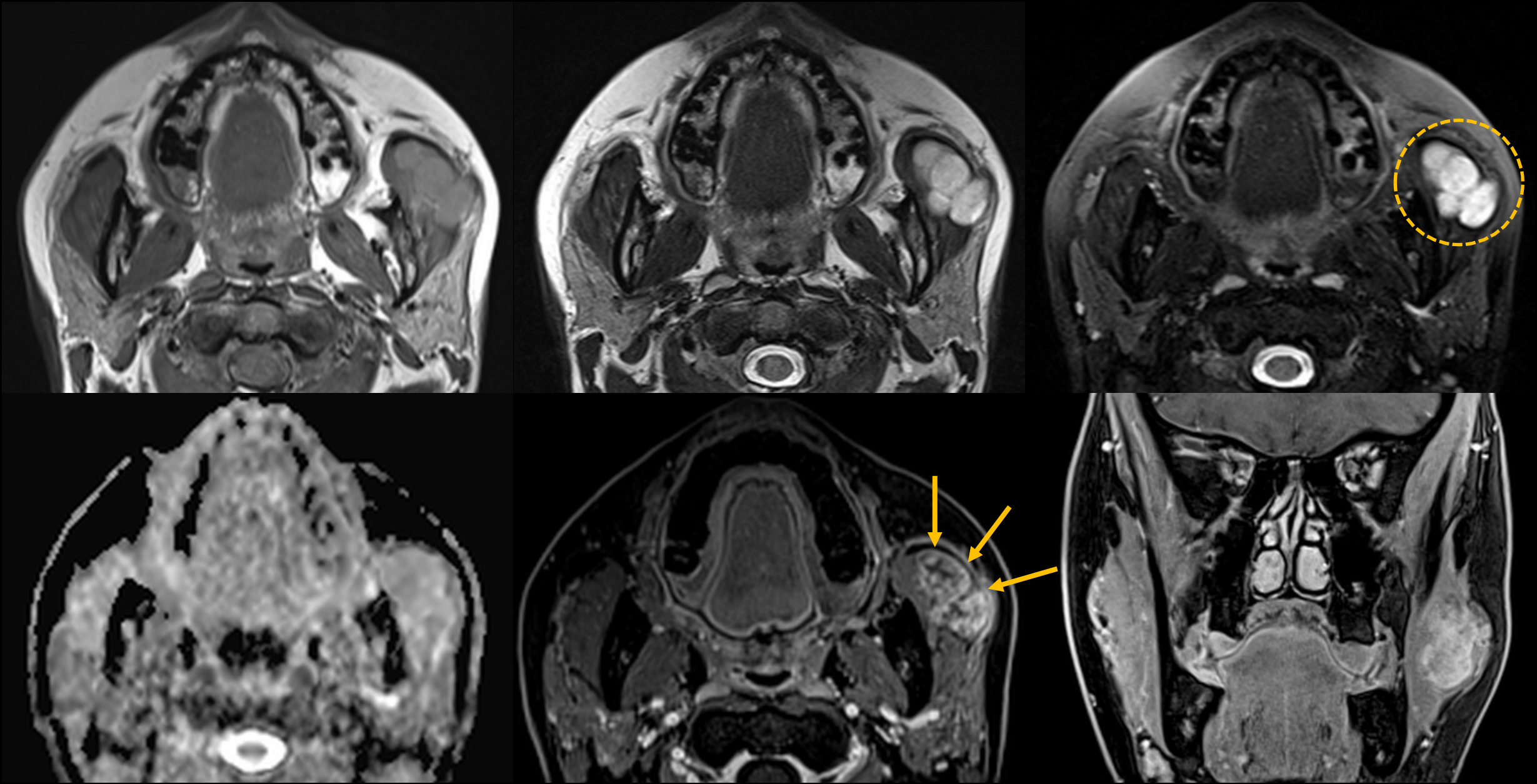
Skin, soft tissues, and gastrointestinal tract

Gastrointestinal lesions are more clinically relevant
bleeding → patients are chronically anemic

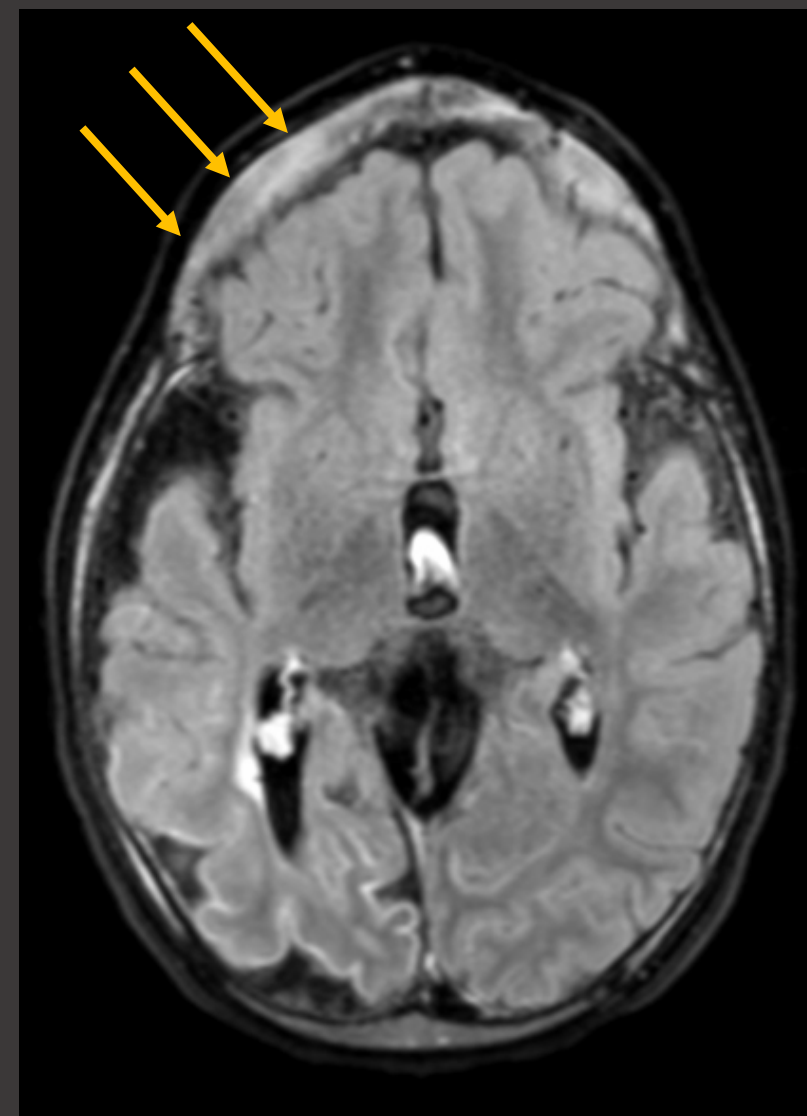
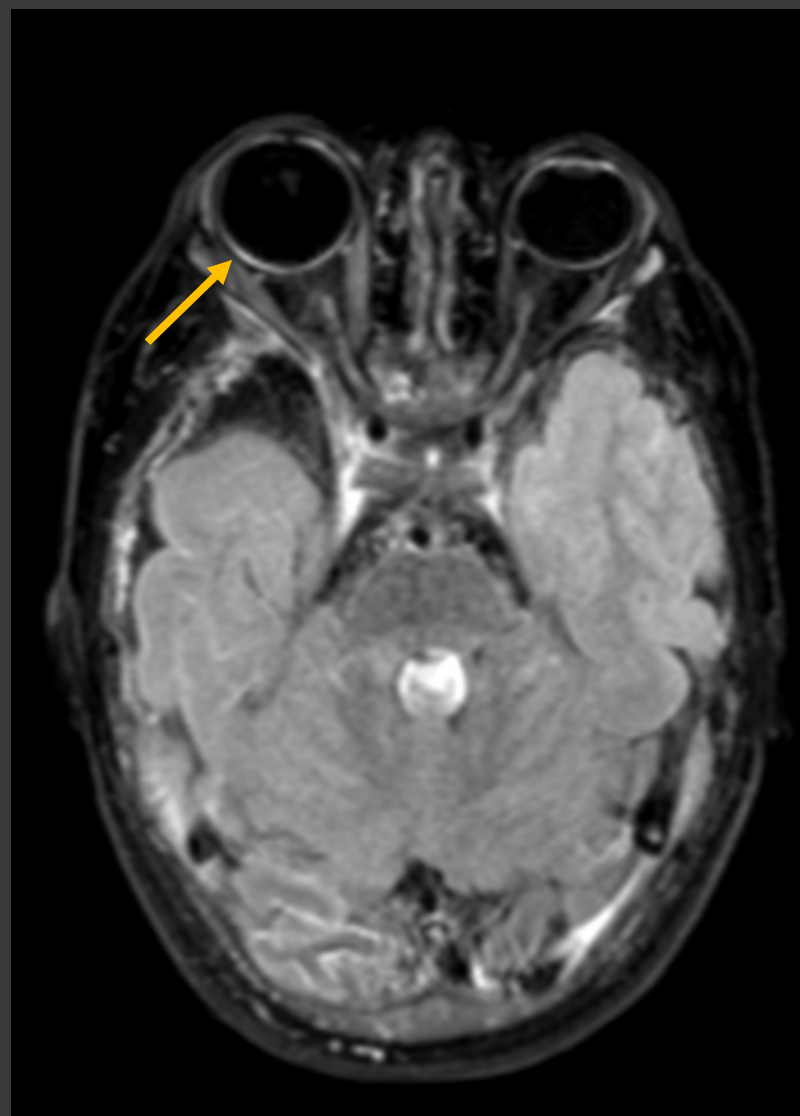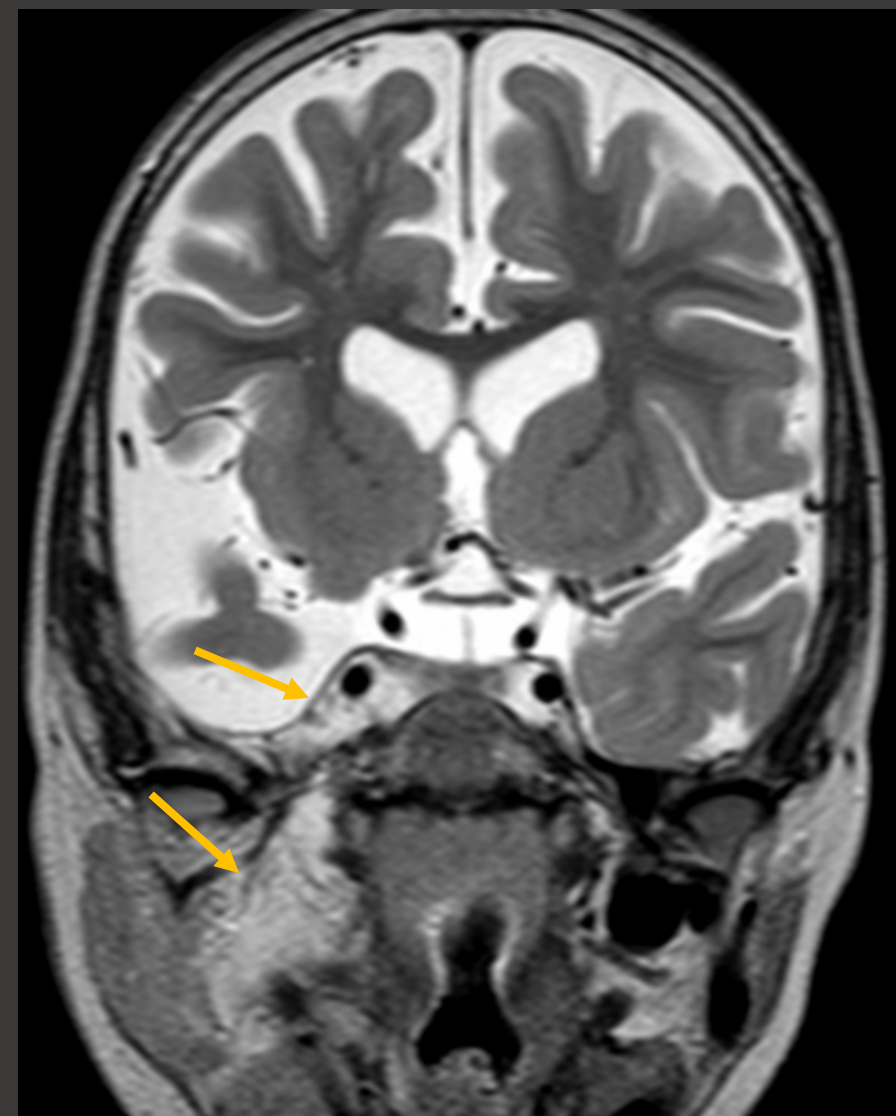
Most cases are sporadic

Familiar: TIE2/TEK, located on 9p21-22
TIE2 signaling pathway crucial for angiogenesis and
vascular maturation

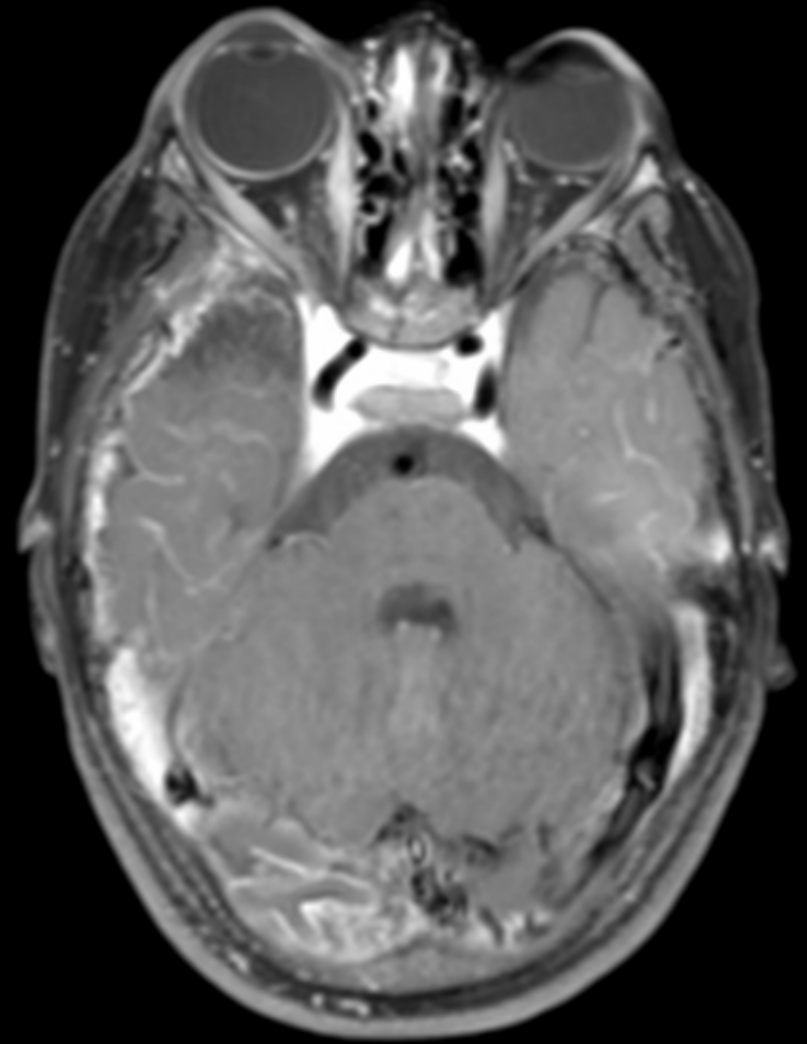
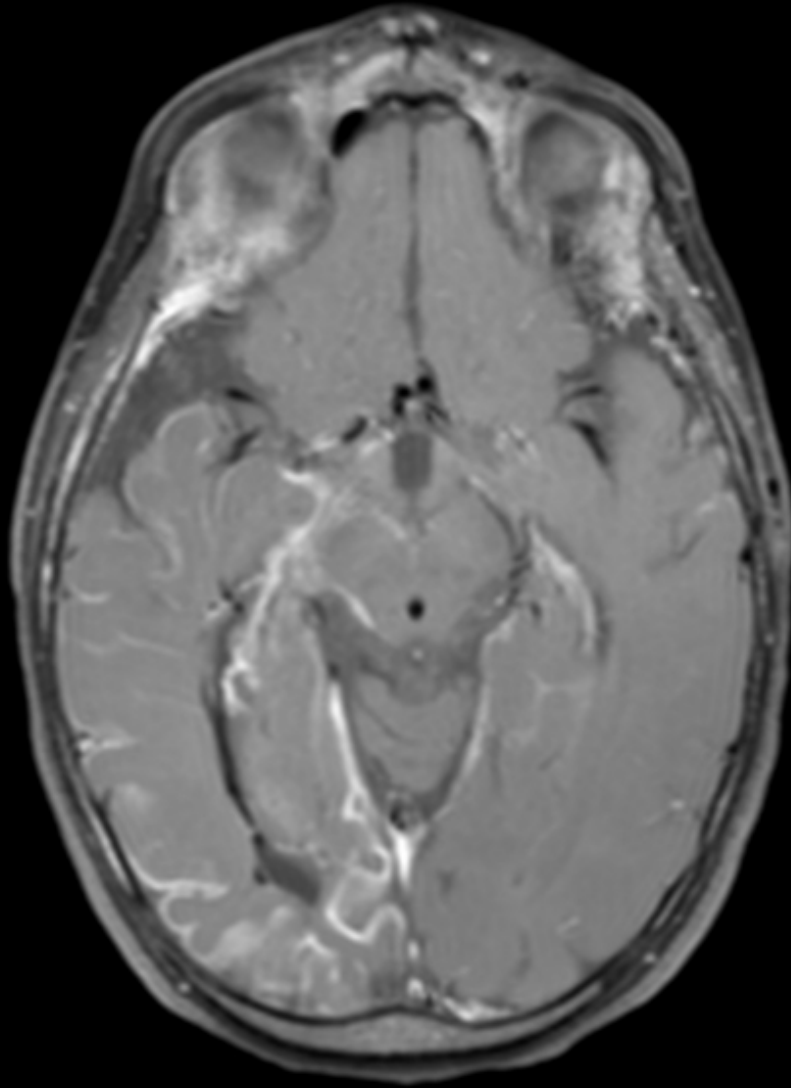
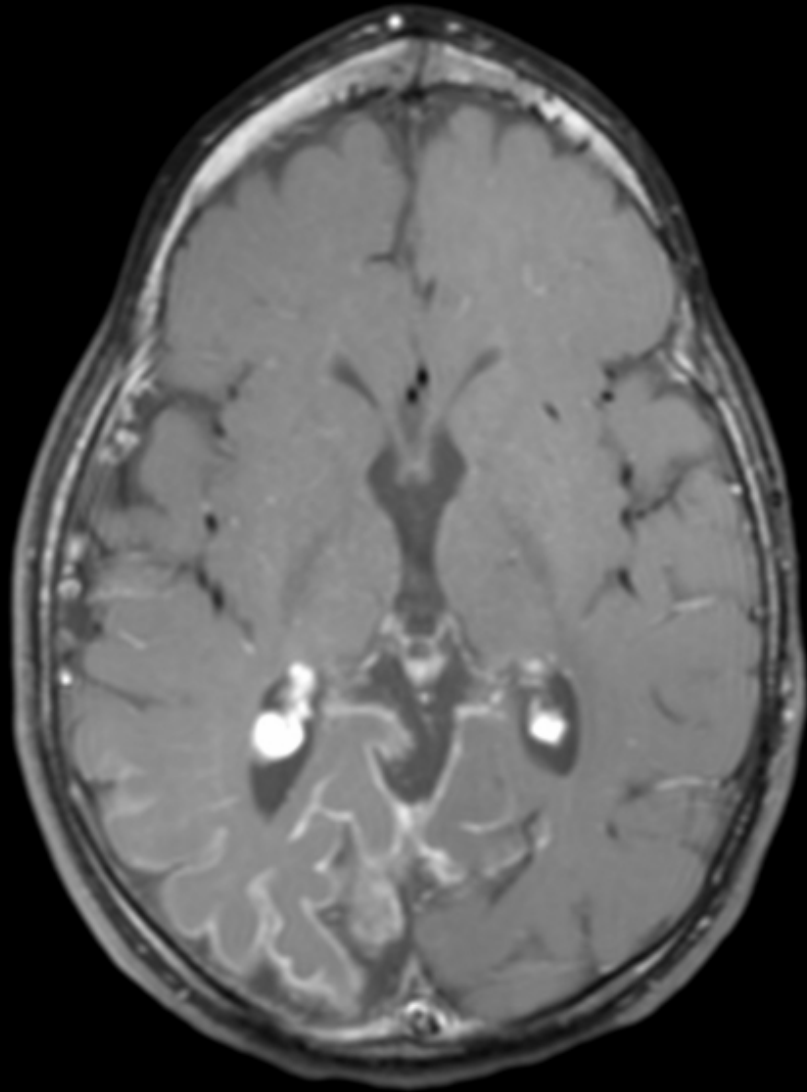
M, 17yo



M, 4yo



M, 4yo

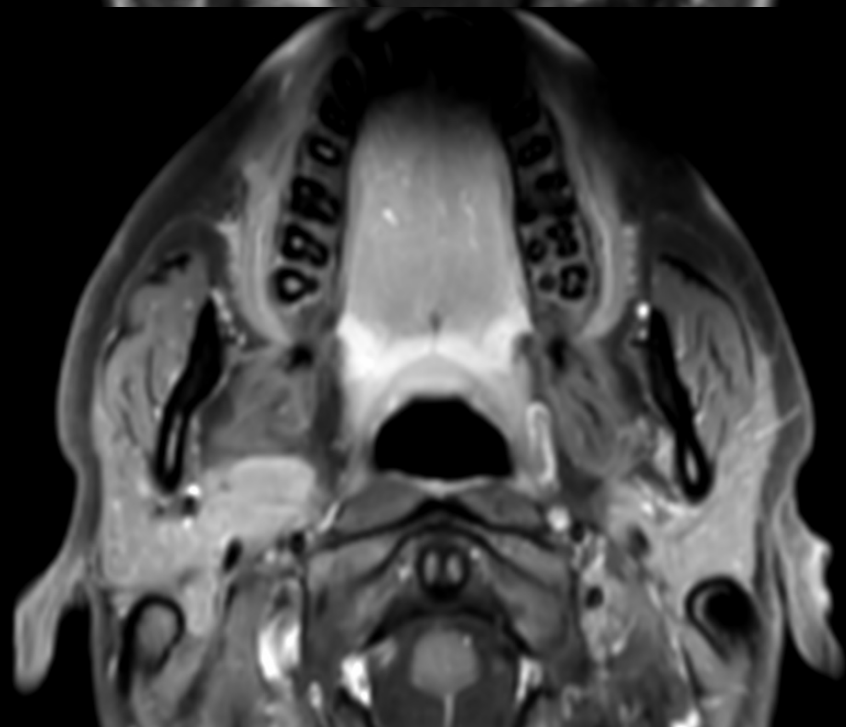
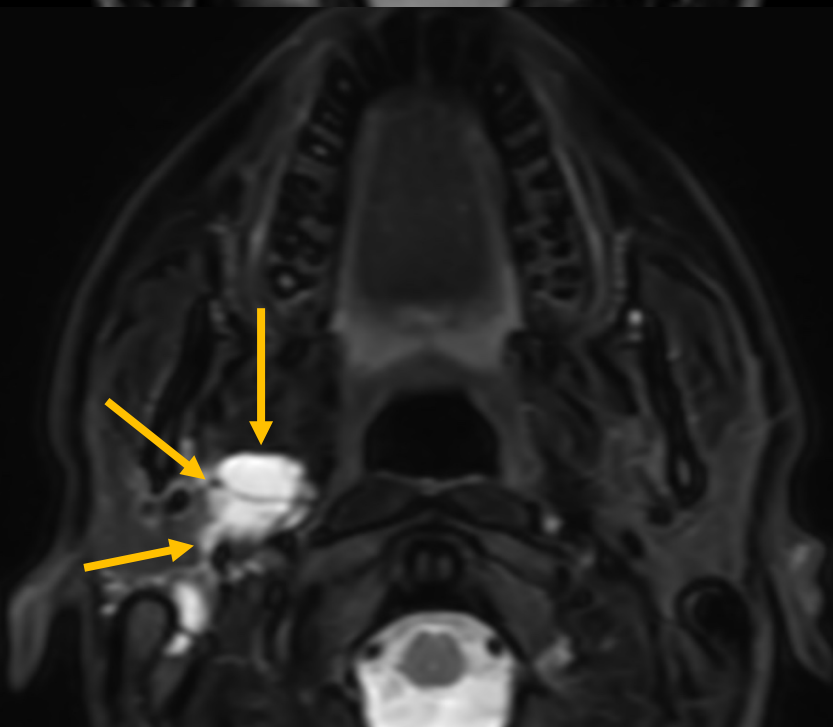
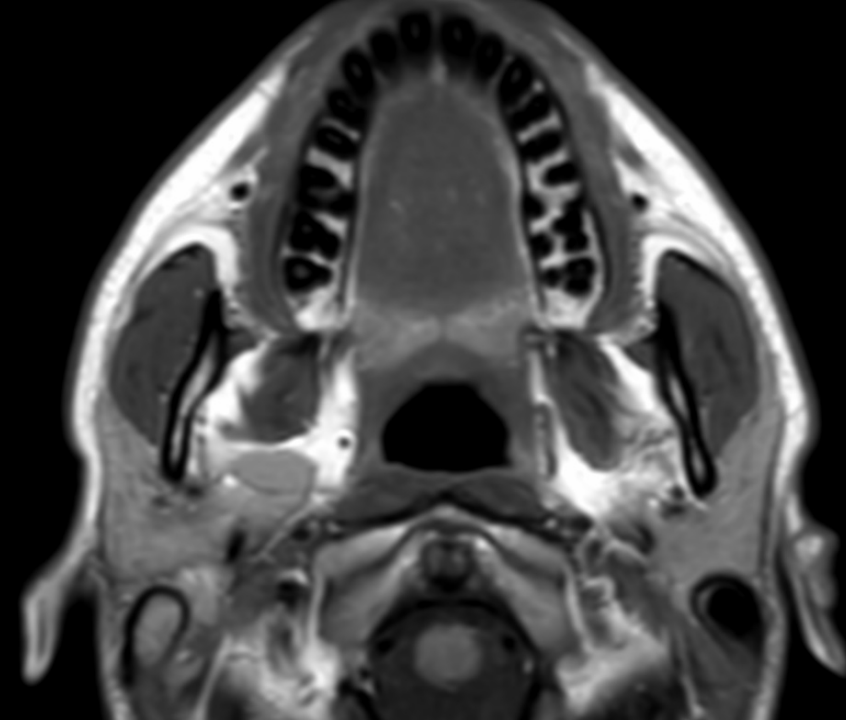
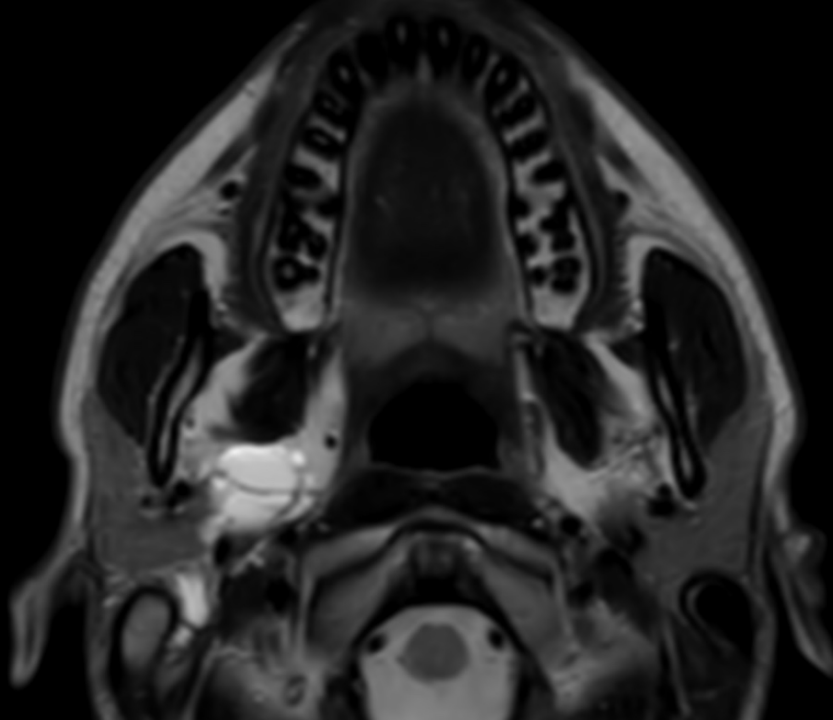
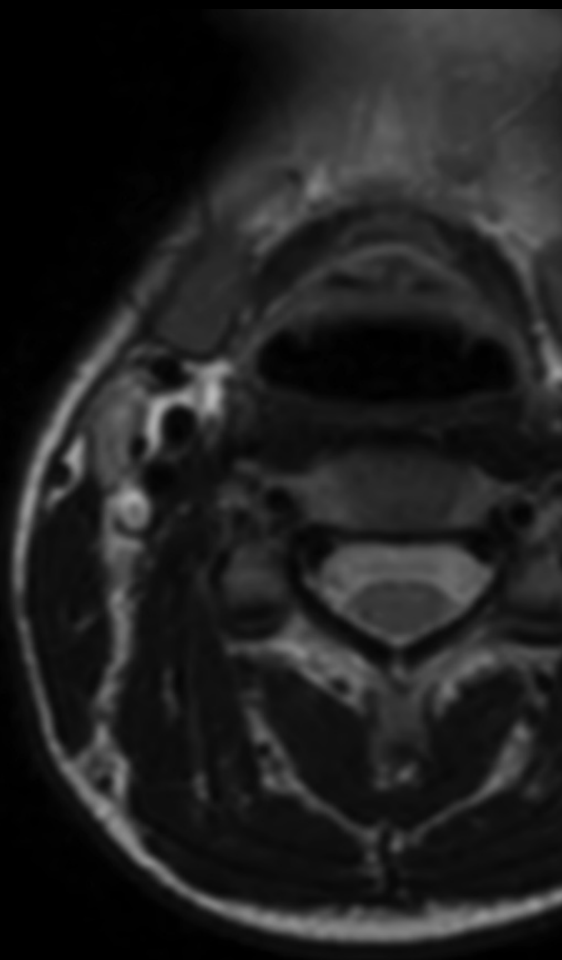


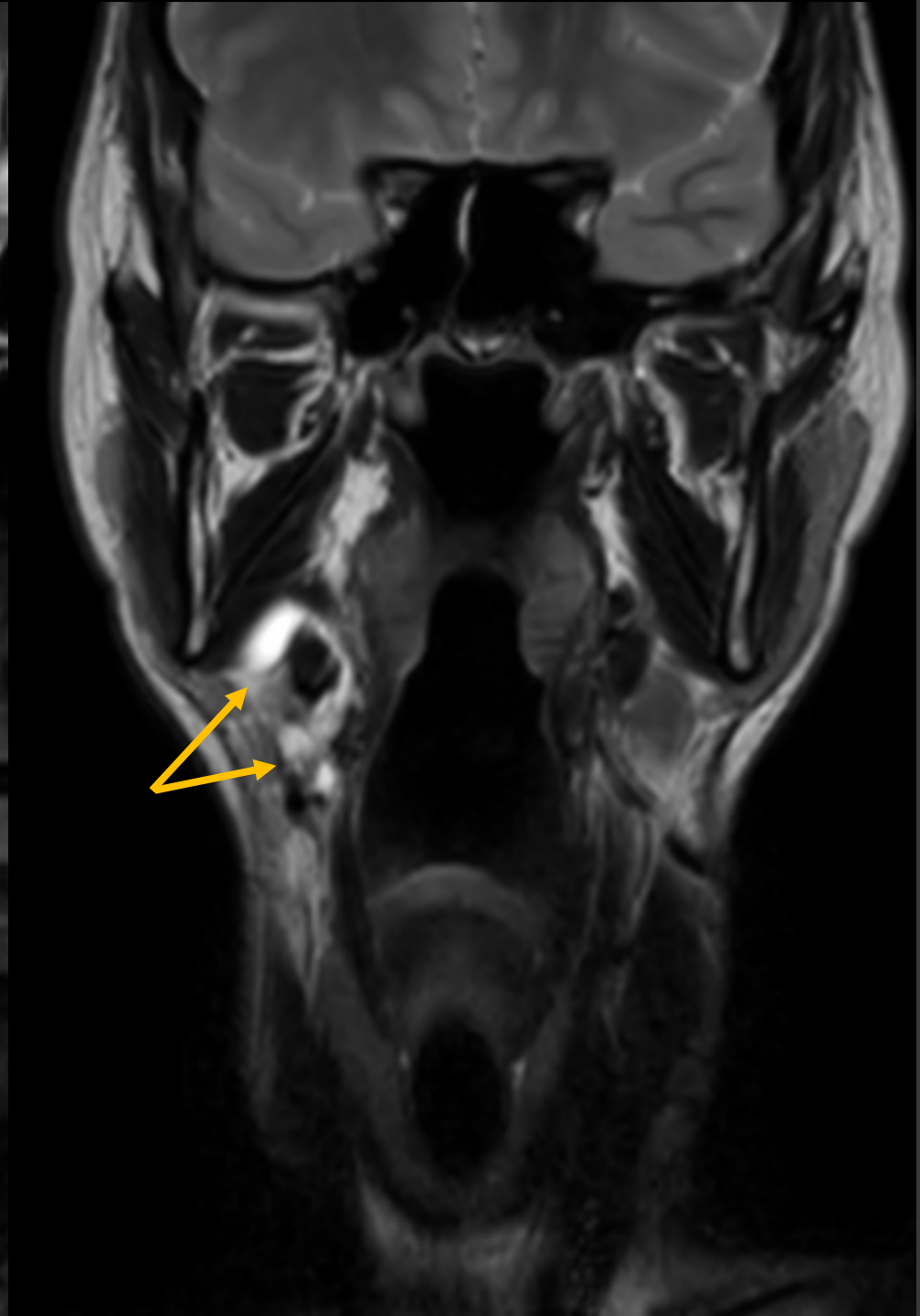
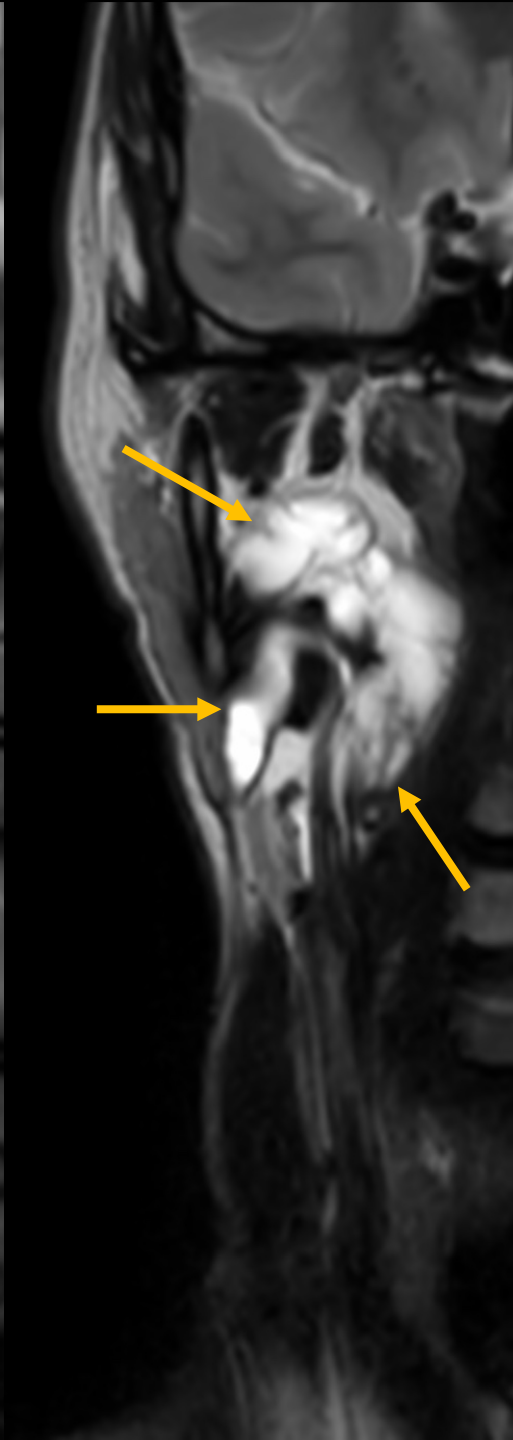
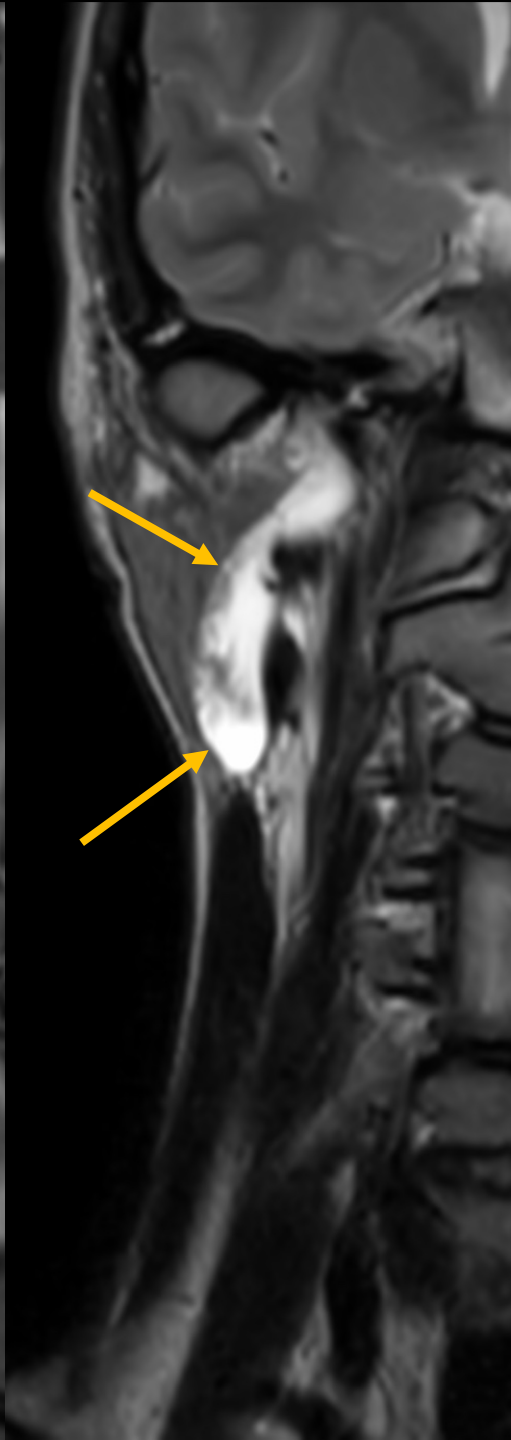
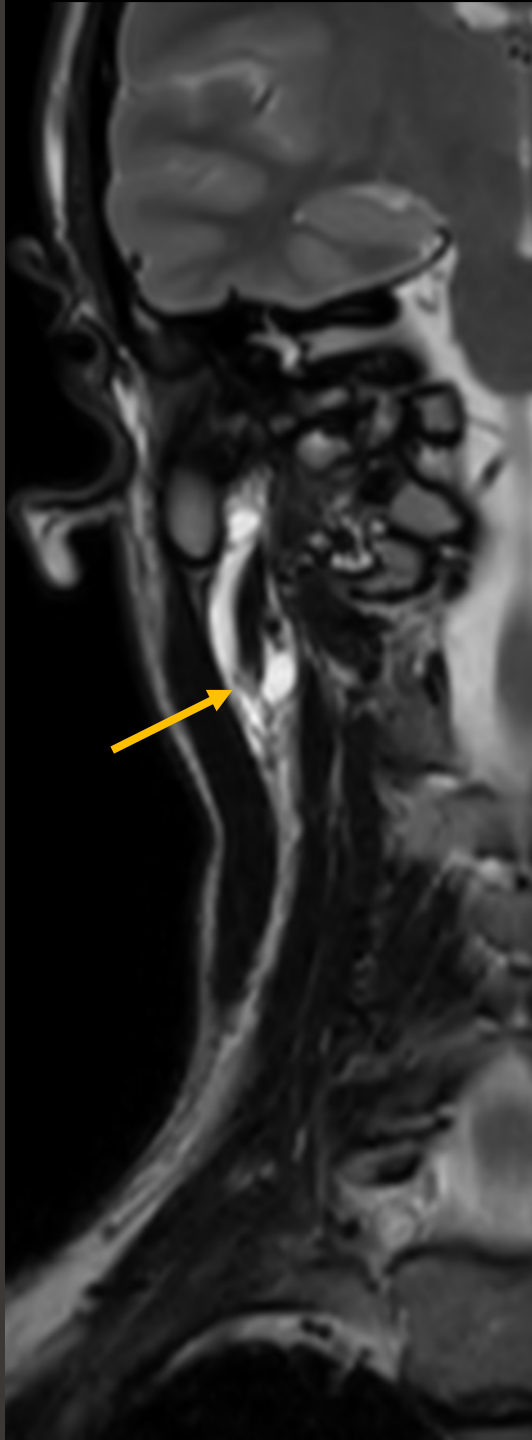
Sturge-Weber Syndrome

Capillary malformations (CM)	
Nevus simplex / salmon patch, "angel kiss", "stork bite"	
Cutaneous and/or mucosal CM (also known as "port-wine" stain)	
Nonsyndromic CM	GNAQ
CM with CNS and/or ocular anomalies (Sturge-Weber syndrome)	GNAQ
CM with bone and/or soft tissues overgrowth	GNA11
Diffuse CM with overgrowth (DCMO)	GNA11
Reticulate CM	
CM of MIC-CAP (microcephaly-capillary malformation)	STAMBP
CM of MCAP (megalencephaly-capillary malformation-polymicrogyria)	PIK3CA
CM of CM-AVM	RASA1 / EPHB4
Cutis marmorata telangiectatica congenita (CMTc)	
Others	
Telangiectasia*	
Hereditary hemorrhagic telangiectasia (HHT)(HHT1 ENG, HHT2 ACVRL1, HHT3, JPHT SMAD4)	
Others	

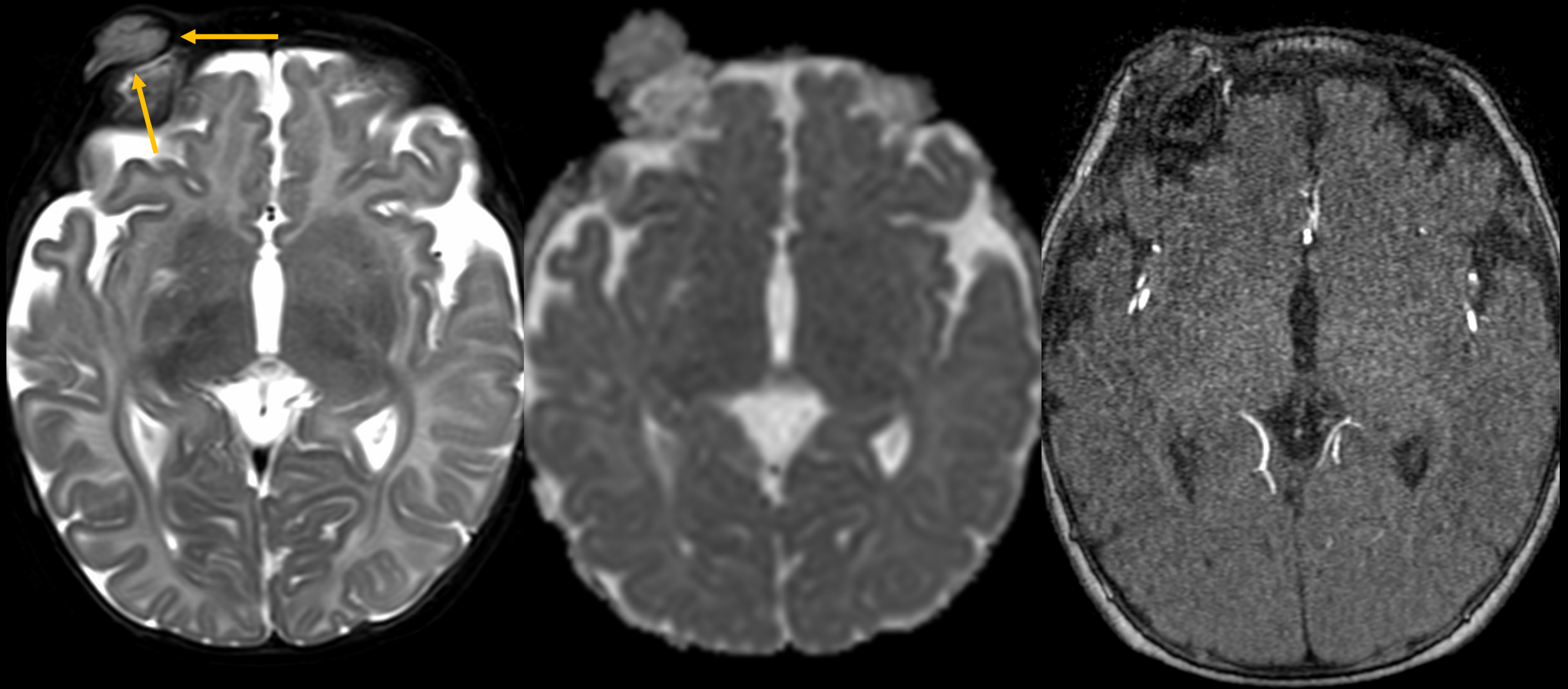
- Encephalotrigeminal angiomatosis
- Neurocutaneous disorder
- Capillary malformation
 - Distribution of the trigeminal branches
- Leptomeningeal angiomatosis
- Cerebral hemiatrophy (steal phenomenon)

F, 15yo

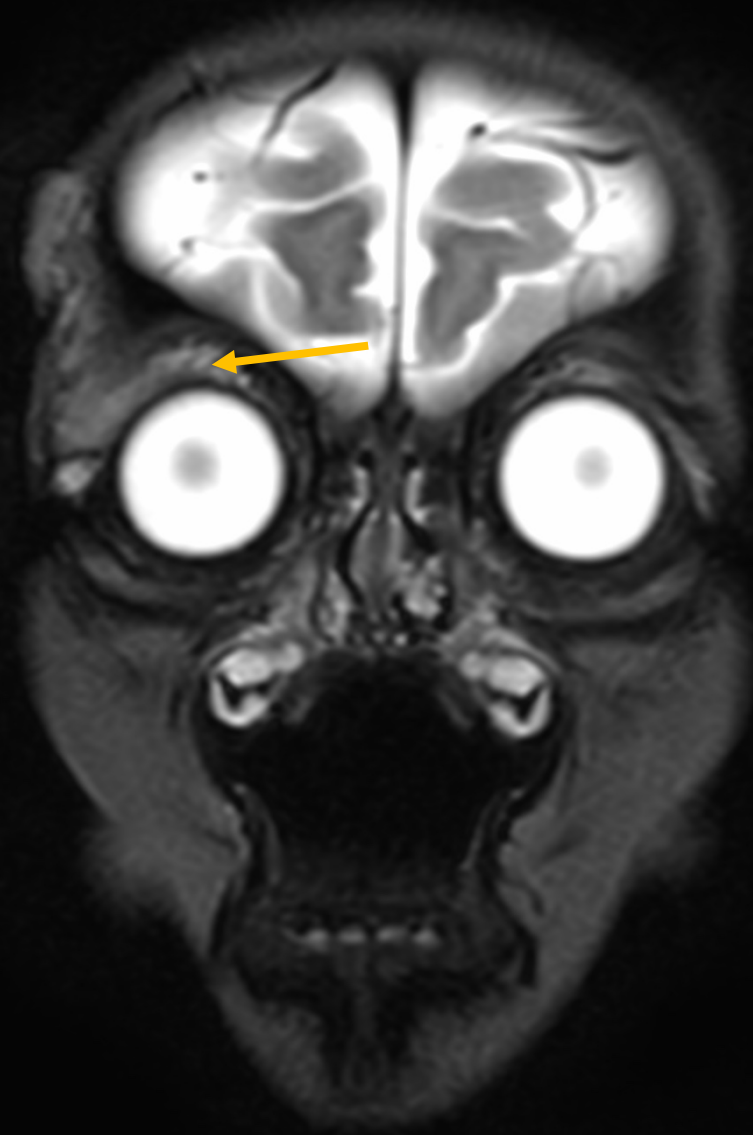
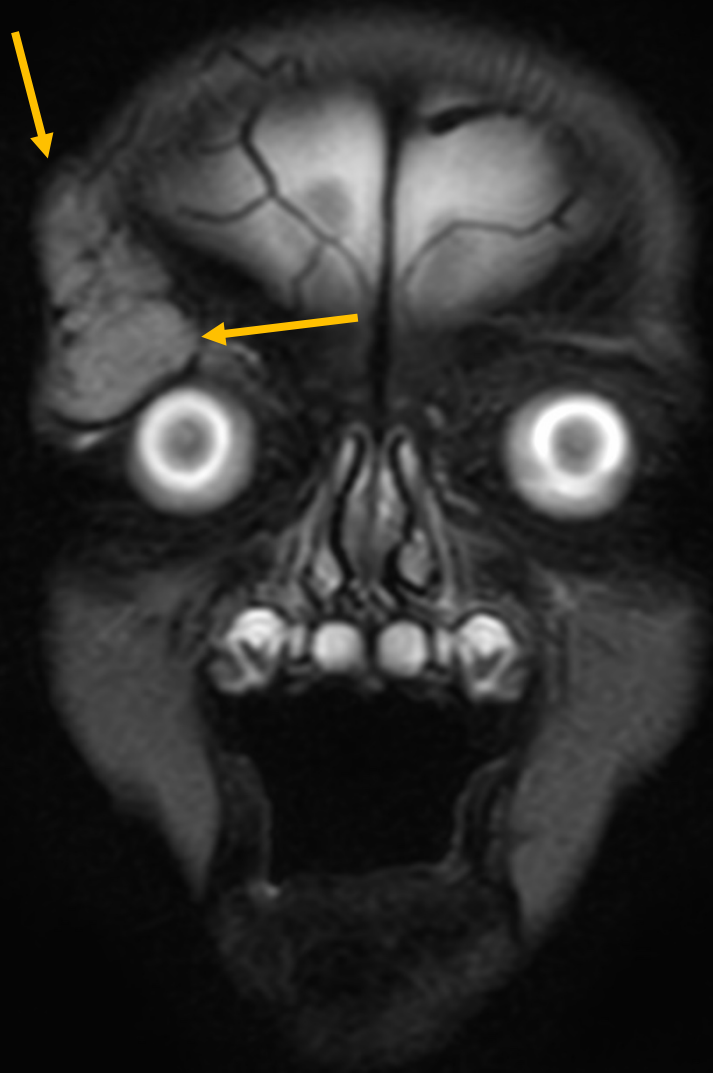


F, 3mo



F, 3mo



Infantile Hemangioma

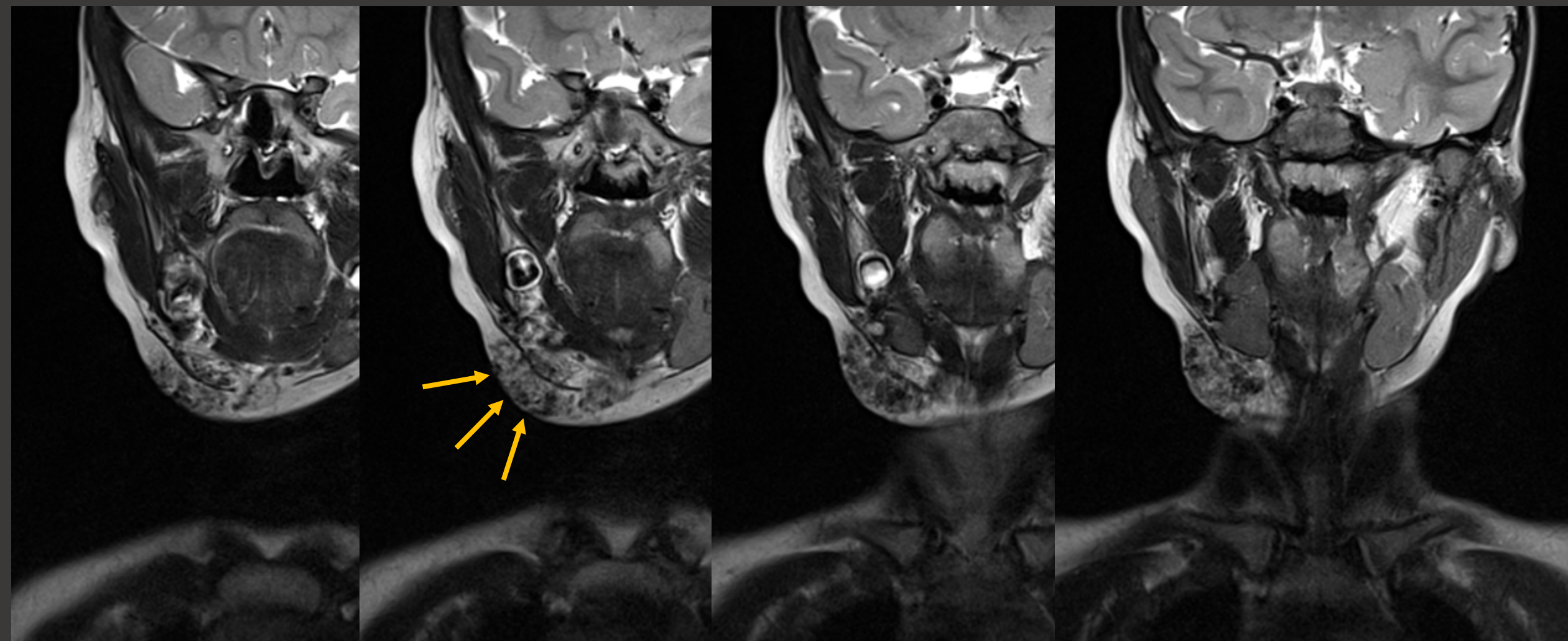
Benign vascular tumors 1	
Infantile hemangioma / Hemangioma of infancy	see details
Congenital hemangioma	GNAQ / GNA11
Rapidly involuting (RICH) *	
Non-involuting (NICH)	
Partially involuting (PICH)	
Tufted angioma * °	GNA14
Spindle-cell hemangioma	IDH1 / IDH2
Epithelioid hemangioma	FOS
Pyogenic granuloma (also known as lobular capillary hemangioma)	BRAF / RAS / GNA14
Others	see details

Pattern	Different types
<ul style="list-style-type: none"> - focal - multifocal - segmental - indeterminate 	<ul style="list-style-type: none"> - superficial - deep - mixed (superficial + deep) - reticular / abortive / minimal growth - others

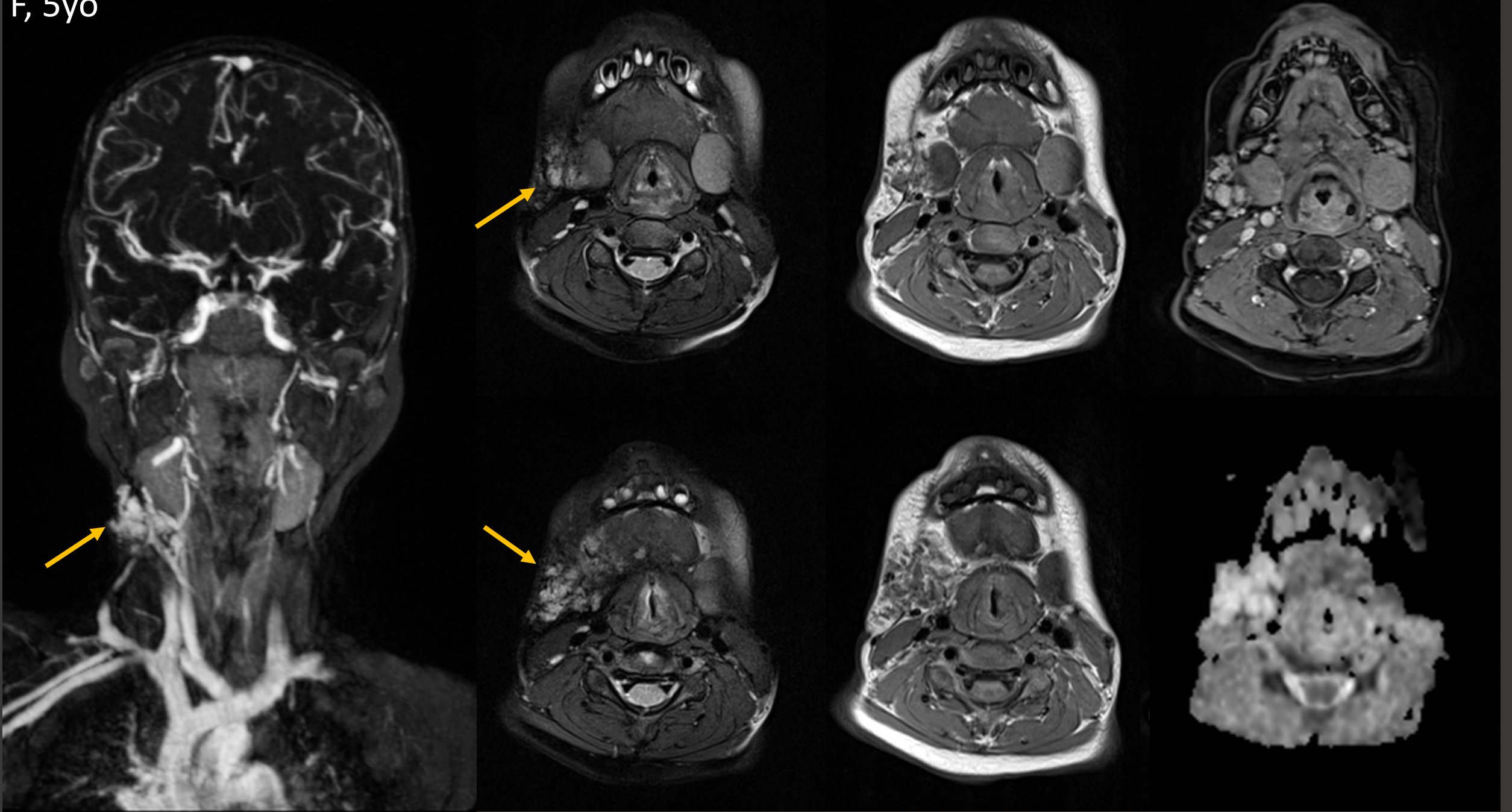
Association with other lesions	
PHACE association / syndrome	Posterior fossa malformations, Hemangioma, Arterial anomalies, Cardiovascular anomalies, Eye anomalies, sternal clefting and/or supraumbilical raphe
LUMBAR (SACRAL, PELVIS) association / syndrome	Lower body hemangioma, Urogenital anomalies, Ulceration, Myelopathy, Bony deformities, Anorectal malformations, Arterial anomalies, and Renal anomalies

- Benign endothelial tumor of infancy
- Not present at birth
- Appear a few weeks later with rapid growth -
 - **proliferative** phase (Phase I)
- Regress slowly beginning at age 2-5 -
 - **involuting** phase (Phase II)
- Typically completely regress by late childhood -
 - **involved** phase (Phase III)
- Glut-1 positive

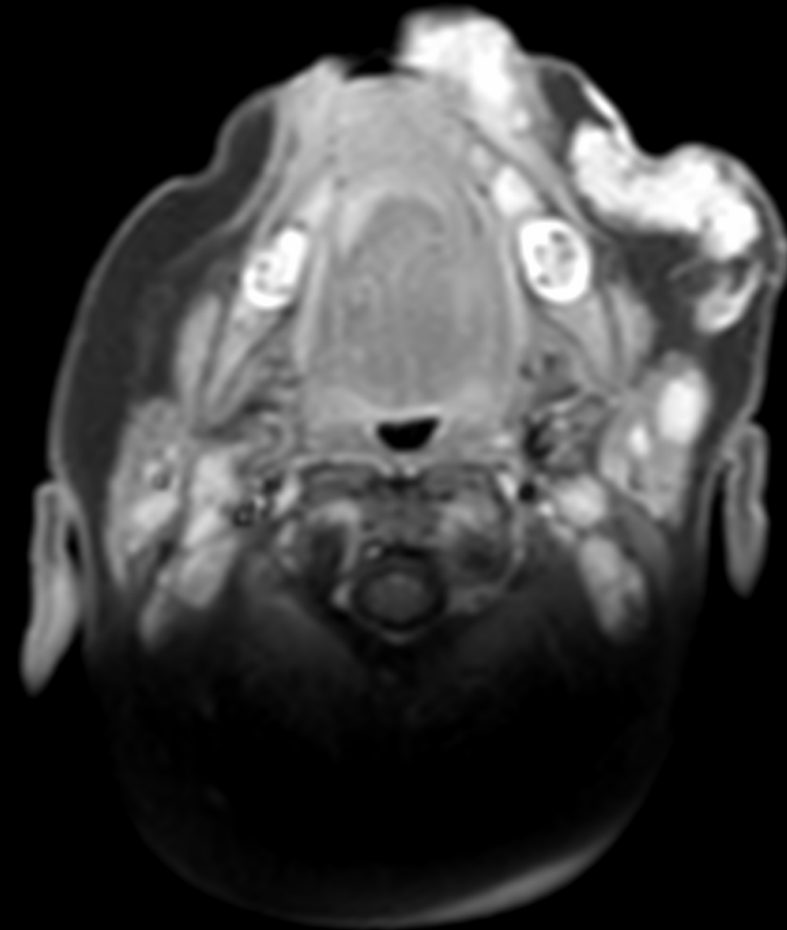
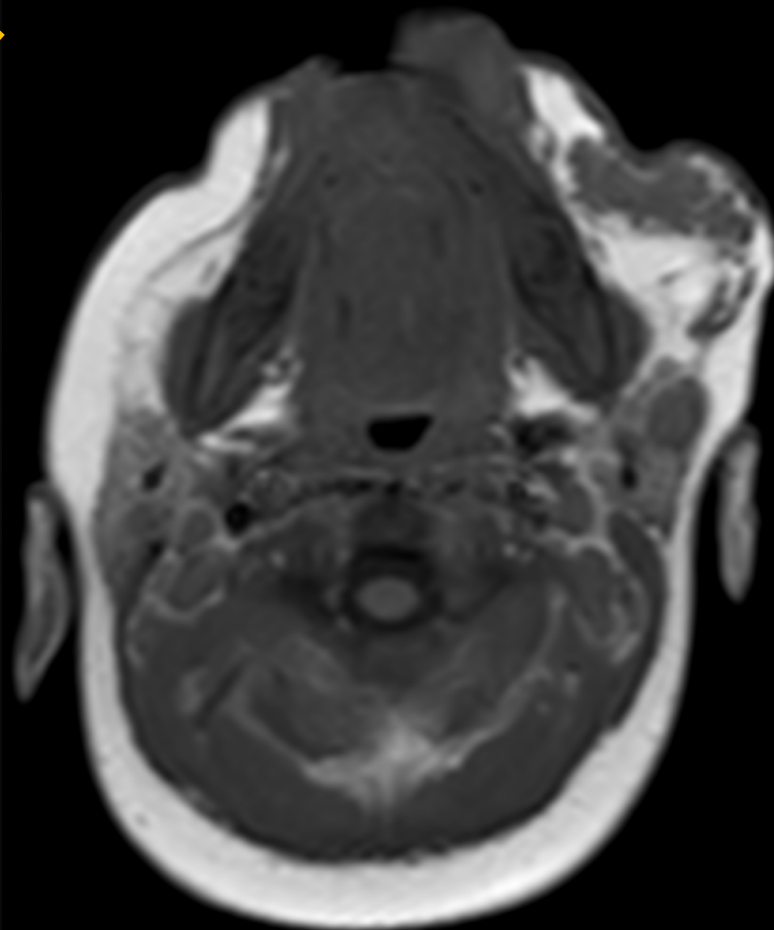
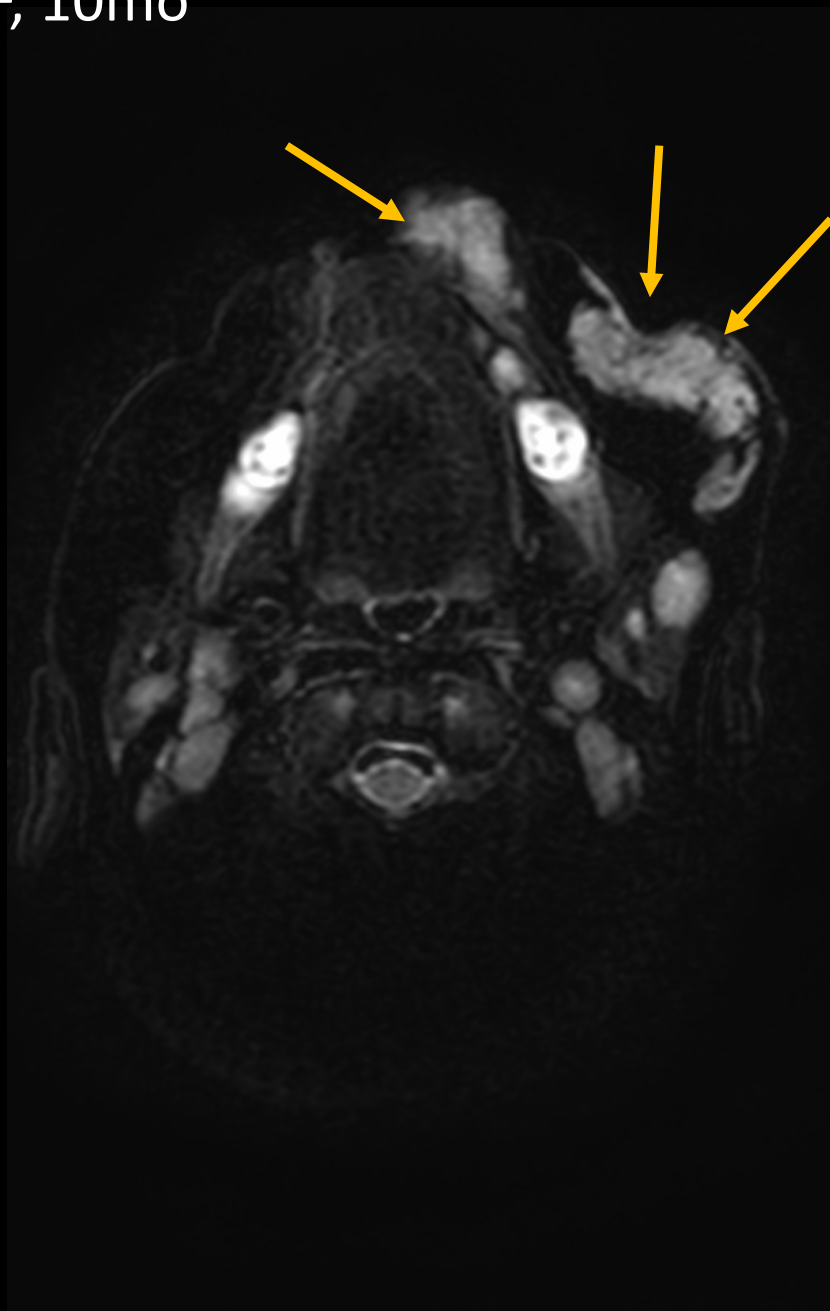F, 5yo



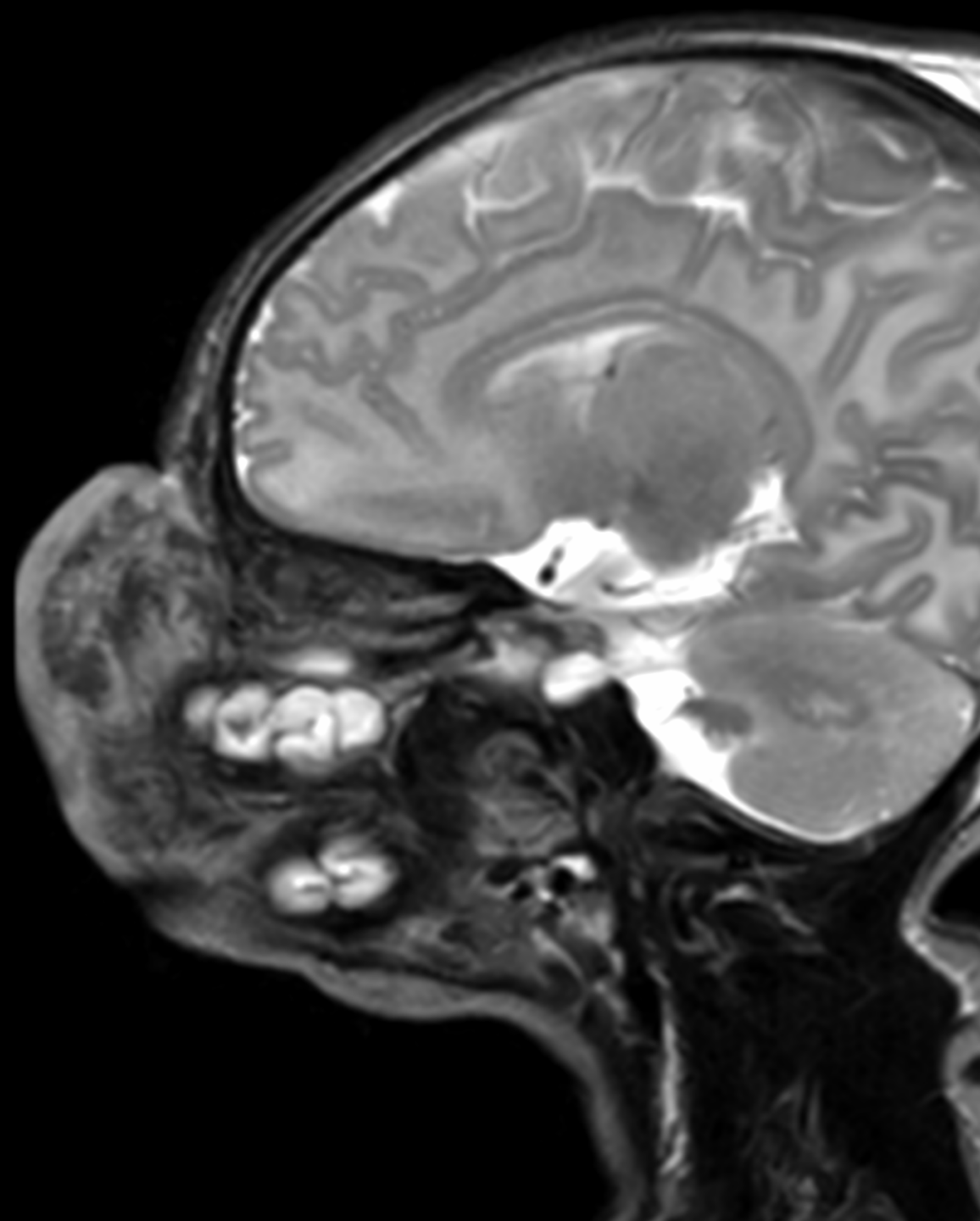
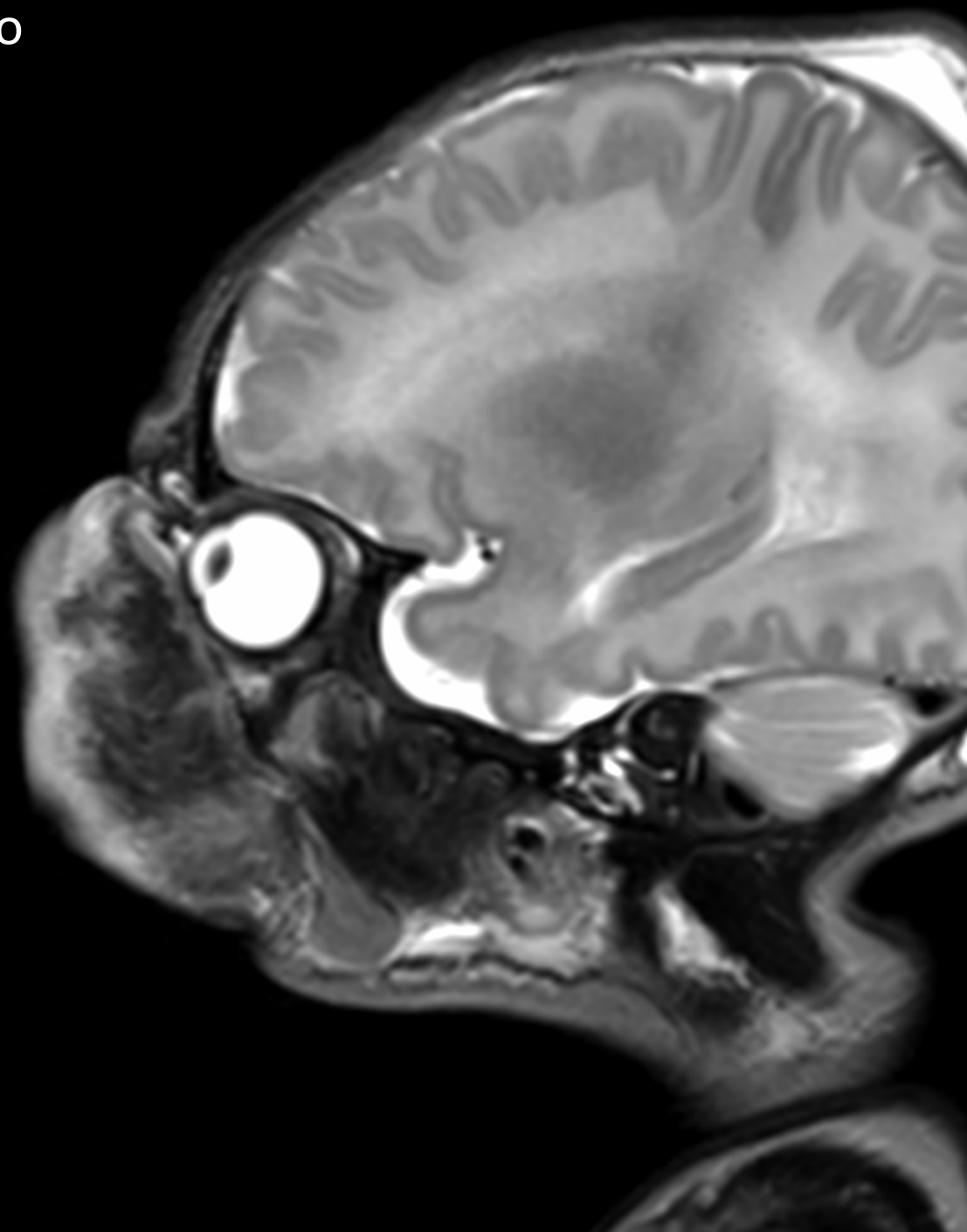
F, 5yo



F, 10mo



F, 3mo

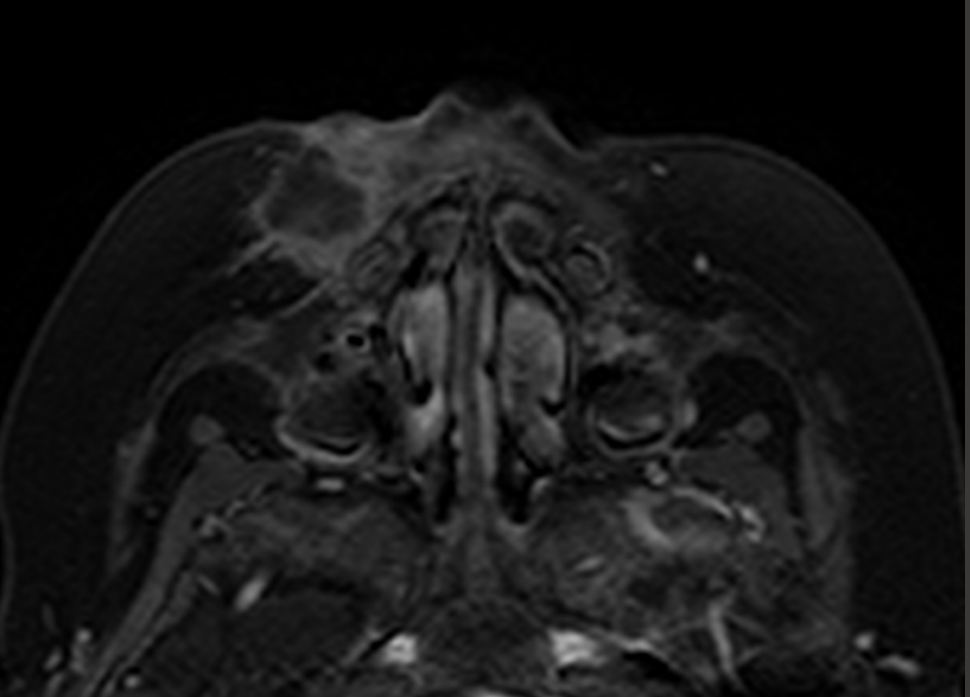

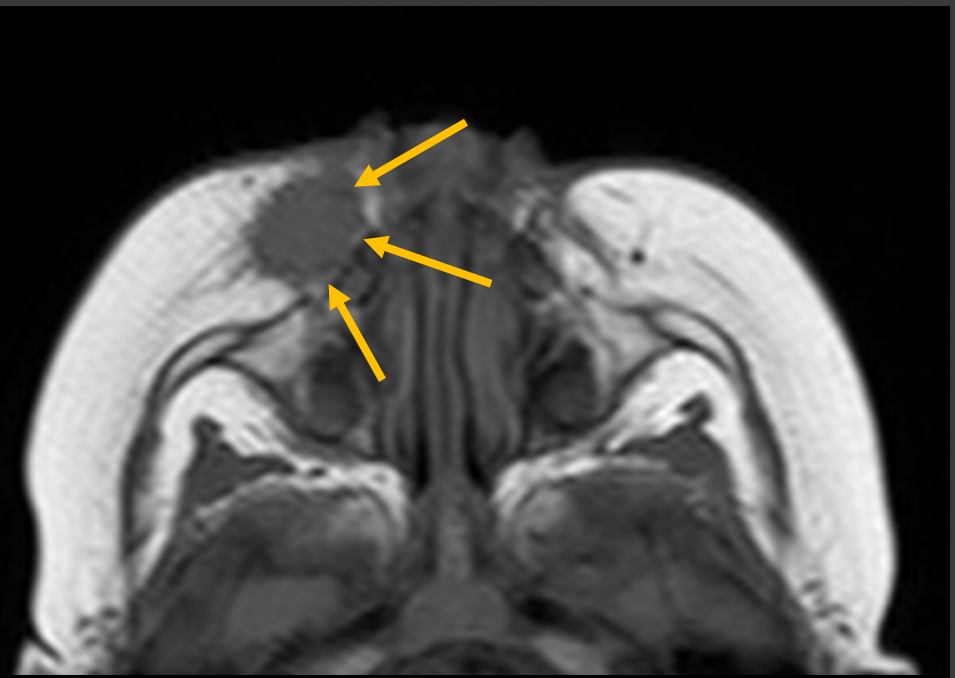
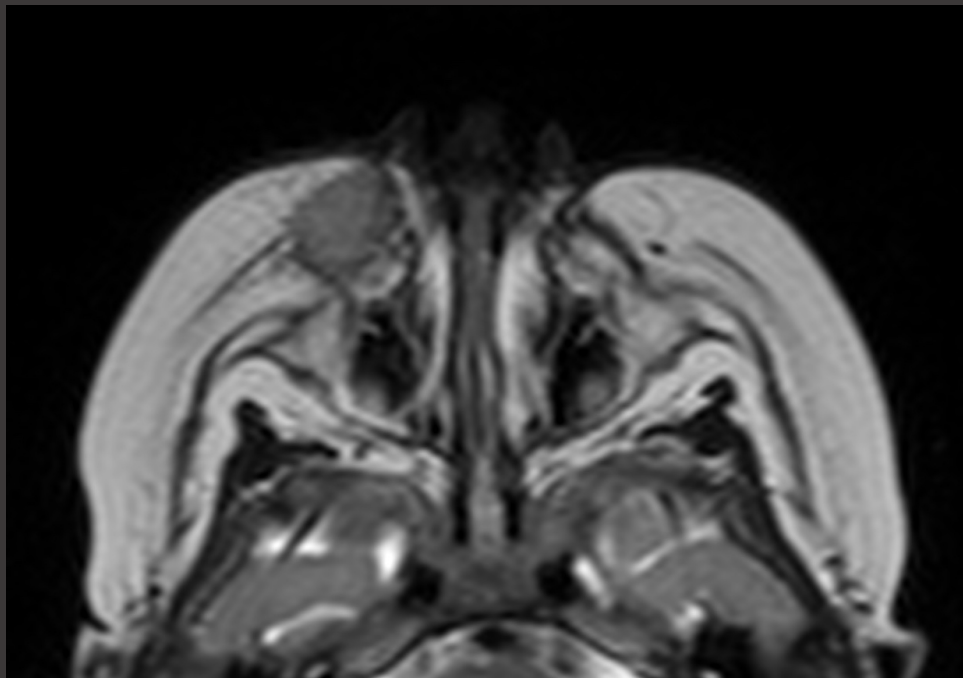


Congenital Hemangioma

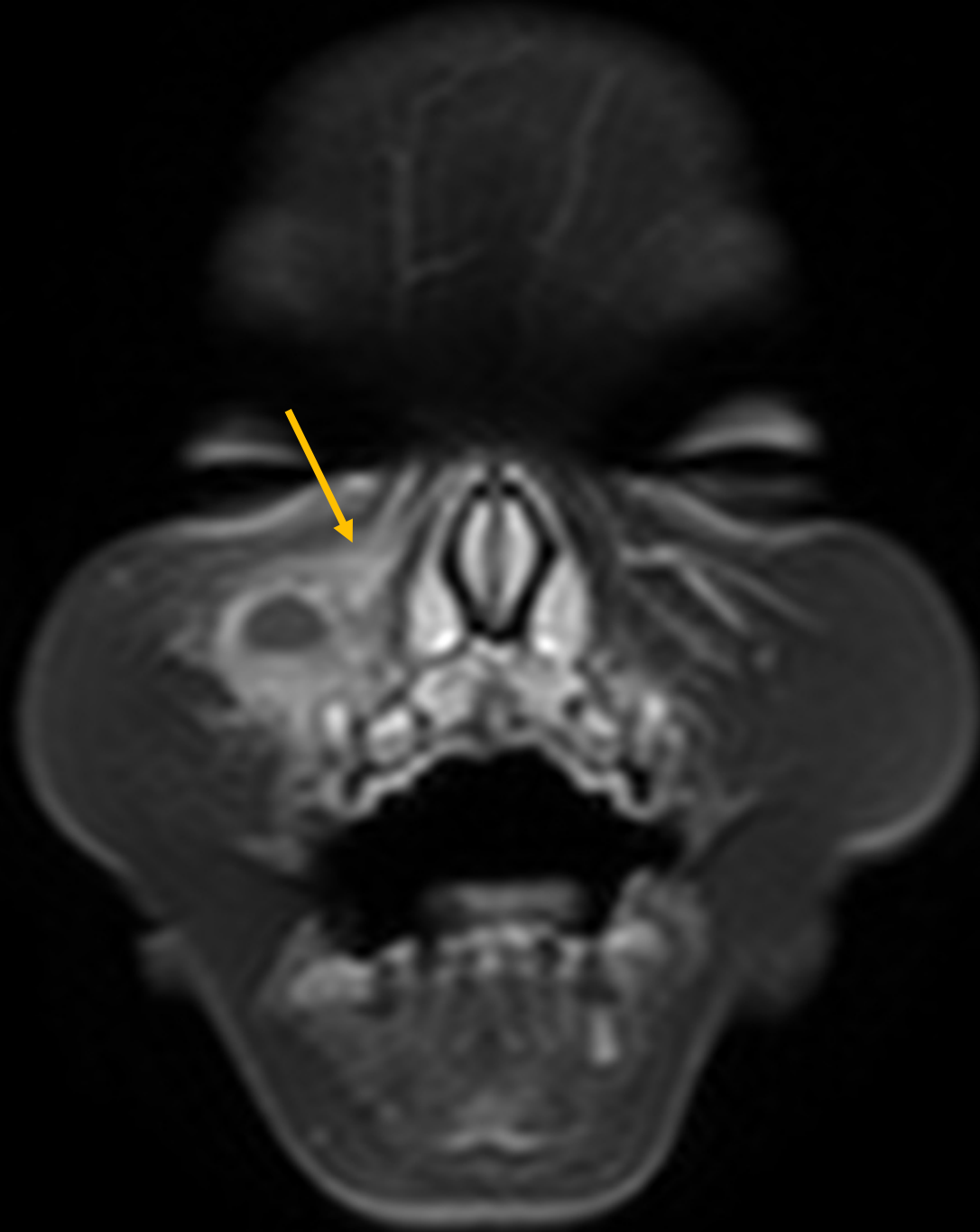
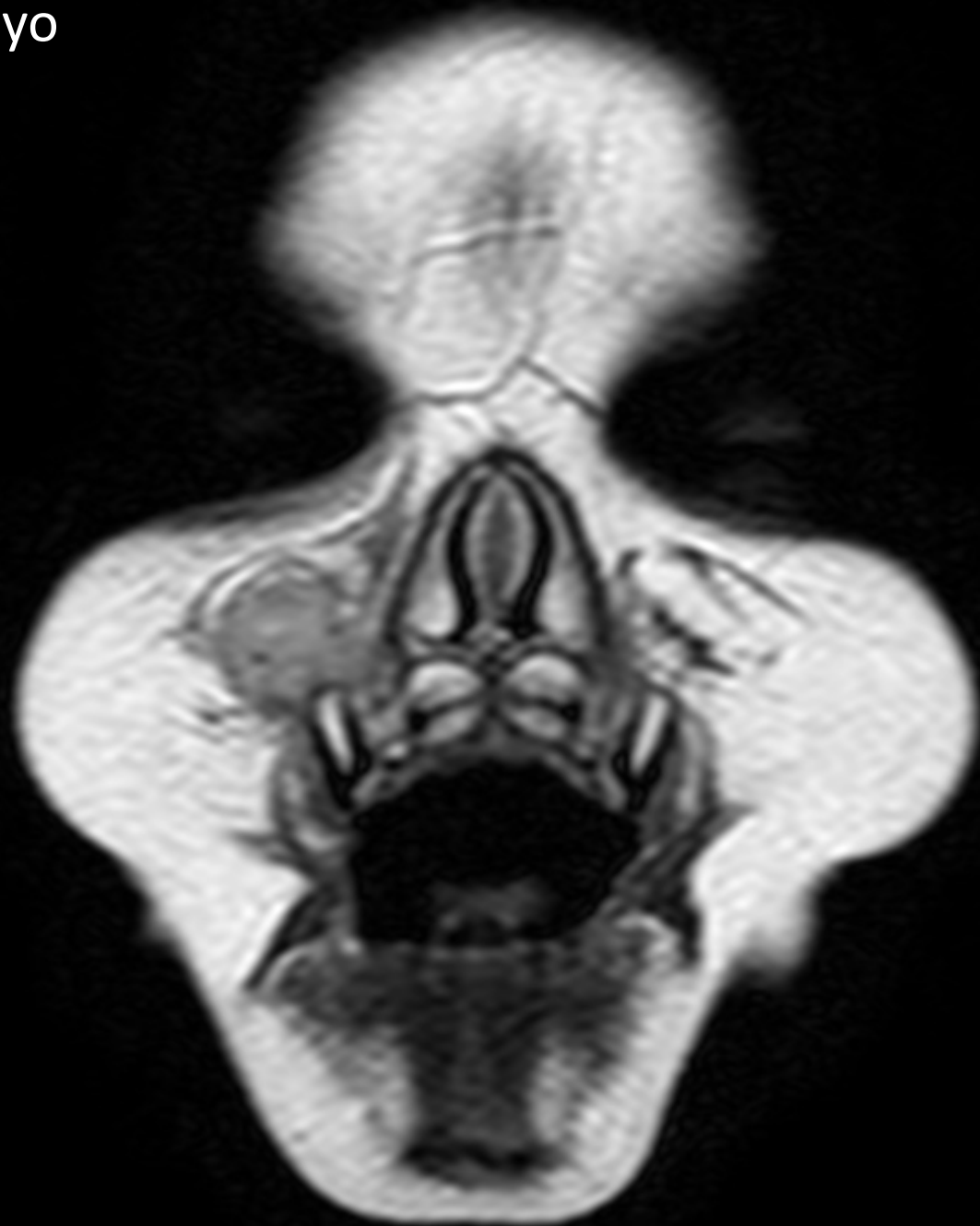Benign vascular tumors 1	
Infantile hemangioma / Hemangioma of infancy	see details
Congenital hemangioma	GNAQ / GNA11
Rapidly involuting (RICH) *	
Non-involuting (NICH)	
Partially involuting (PICH)	
Tufted angioma * °	GNA14
Spindle-cell hemangioma	IDH1 / IDH2
Epithelioid hemangioma	FOS
Pyogenic granuloma (also known as lobular capillary hemangioma)	BRAF / RAS / GNA14
Others	see details

- Rare benign vascular tumors
- GLUT-1 negative
- Present and fully formed at birth
- **RICH**: Rapidly Involuting Congenital Hemangioma
- **NICH**: Non Involuting Congenital Hemangioma
- **PICH**: Partially Involuting Congenital Hemangioma
- Non-specific imaging features

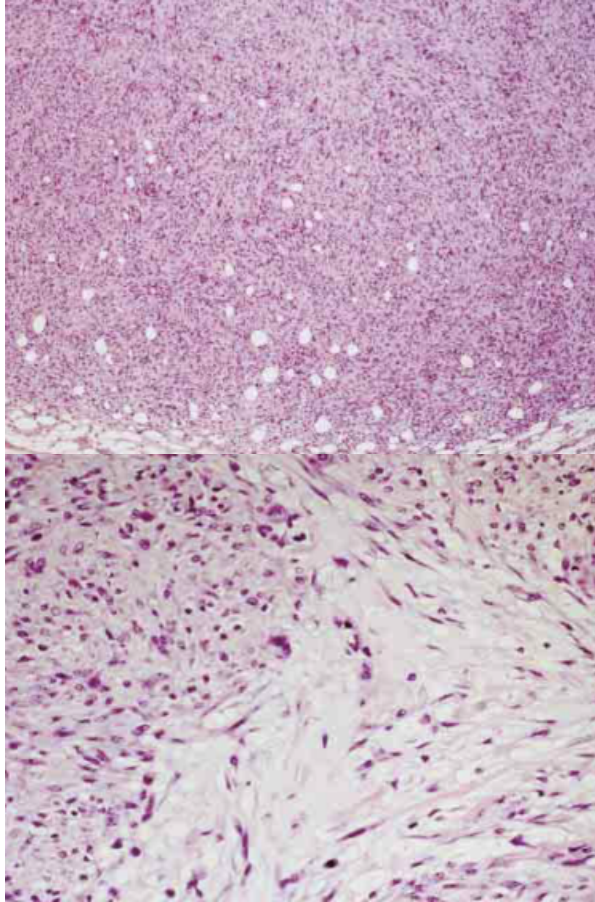
M, 1yo



M, 1yo

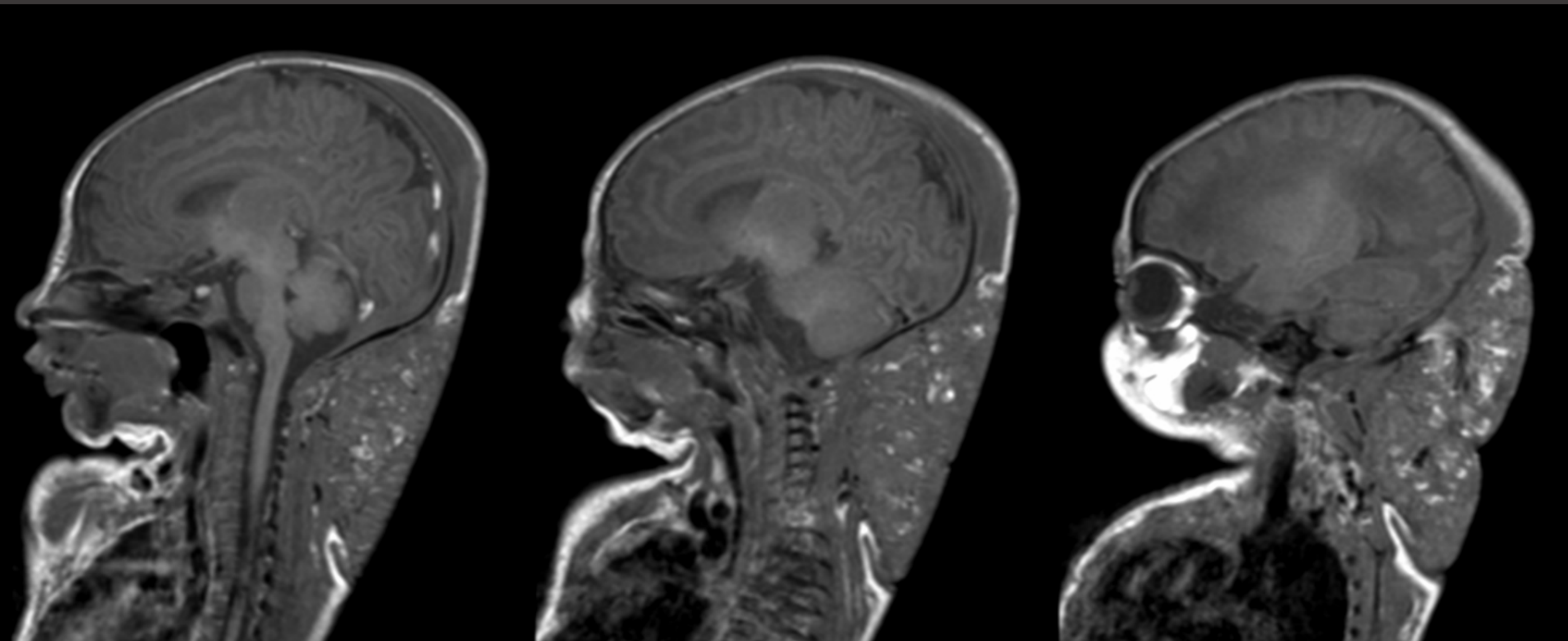


Nodular Fasciitis

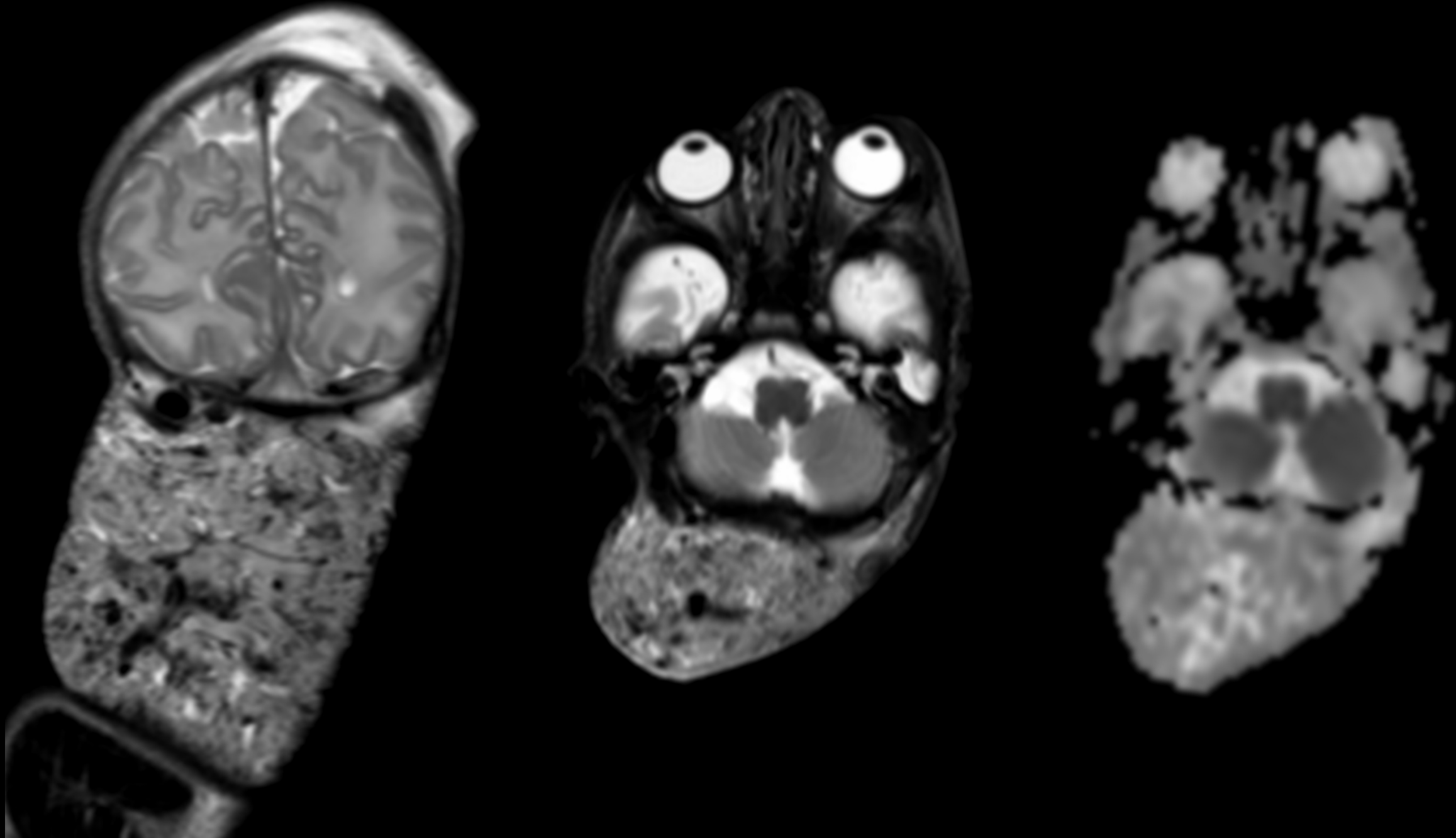


- Nodular hypercellular growth of fibroblasts and myofibroblasts
- Myxoid changes are often present
- Debated neoplastic nature
- Solid or cystic, depending on the predominant stromal elements
- Subcutaneous space or deep
- Round or ovoid, fascial tail sign

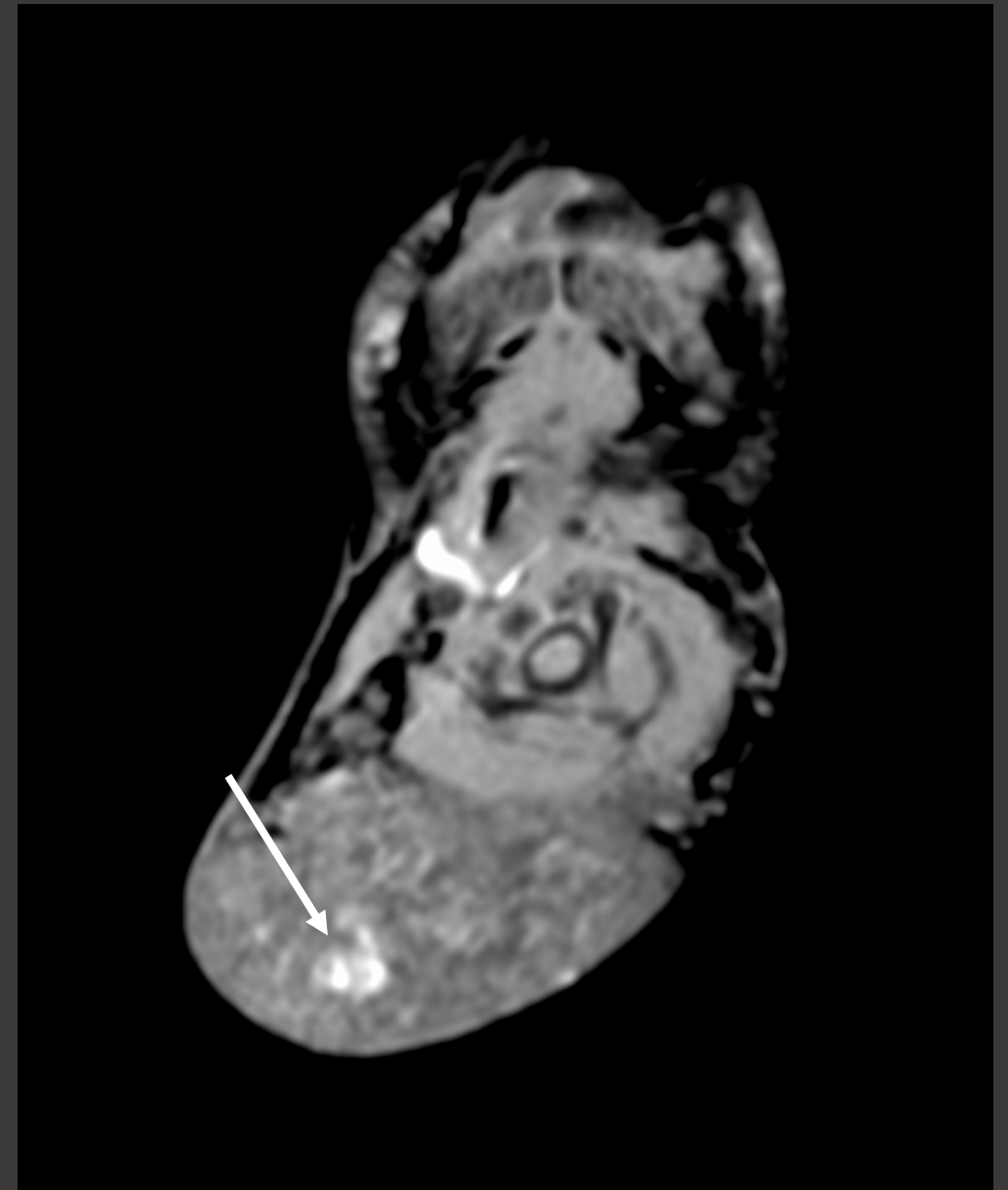
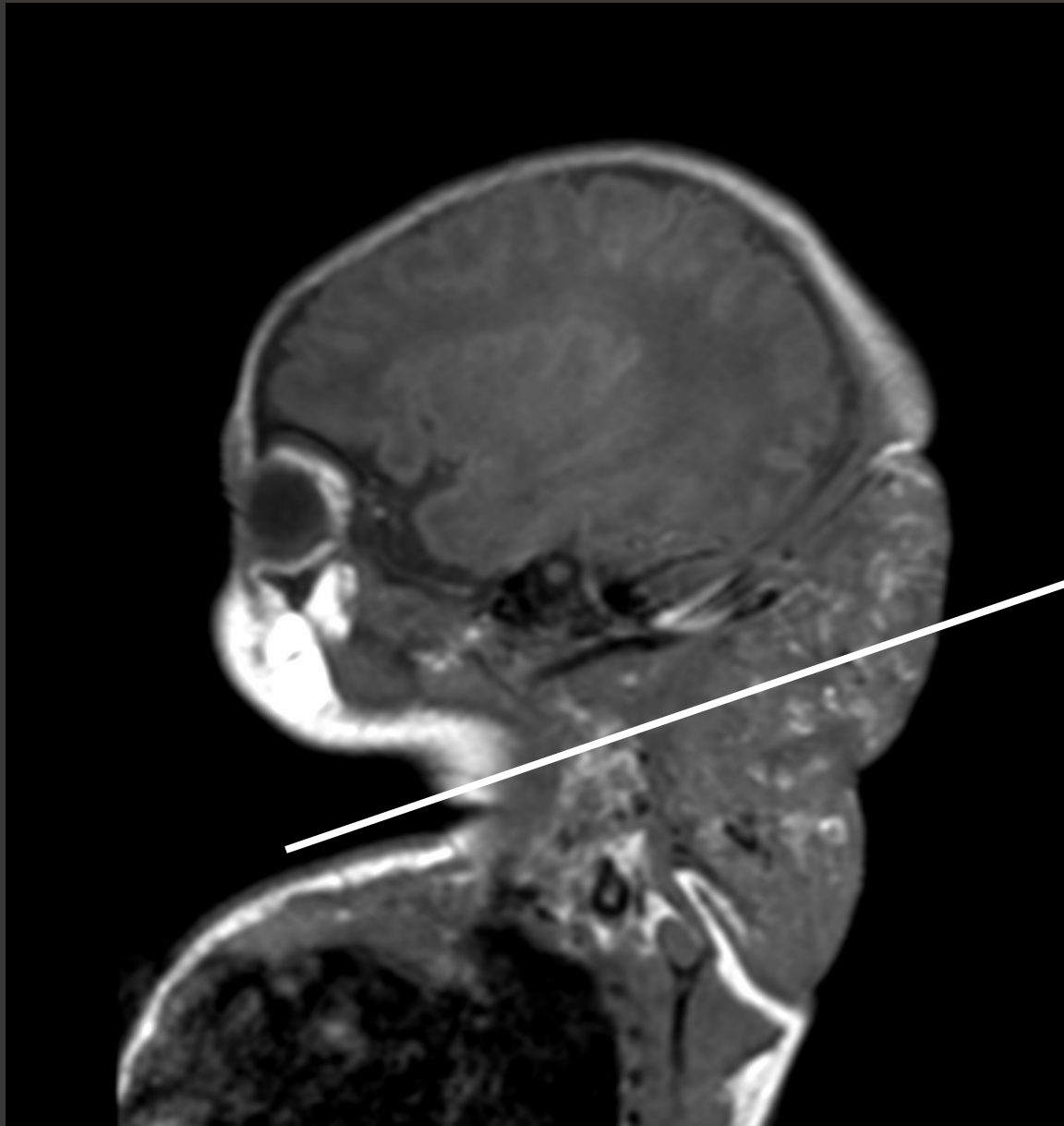
M, 1do



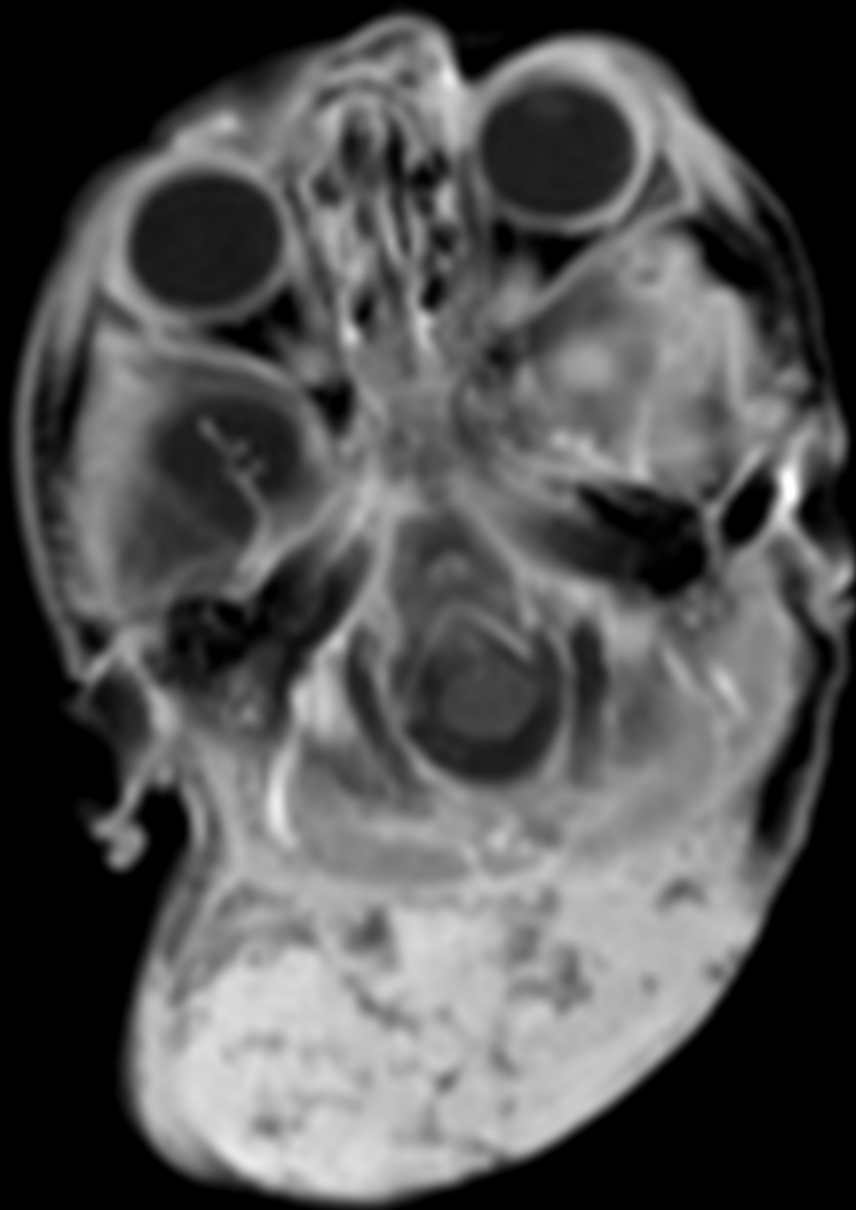
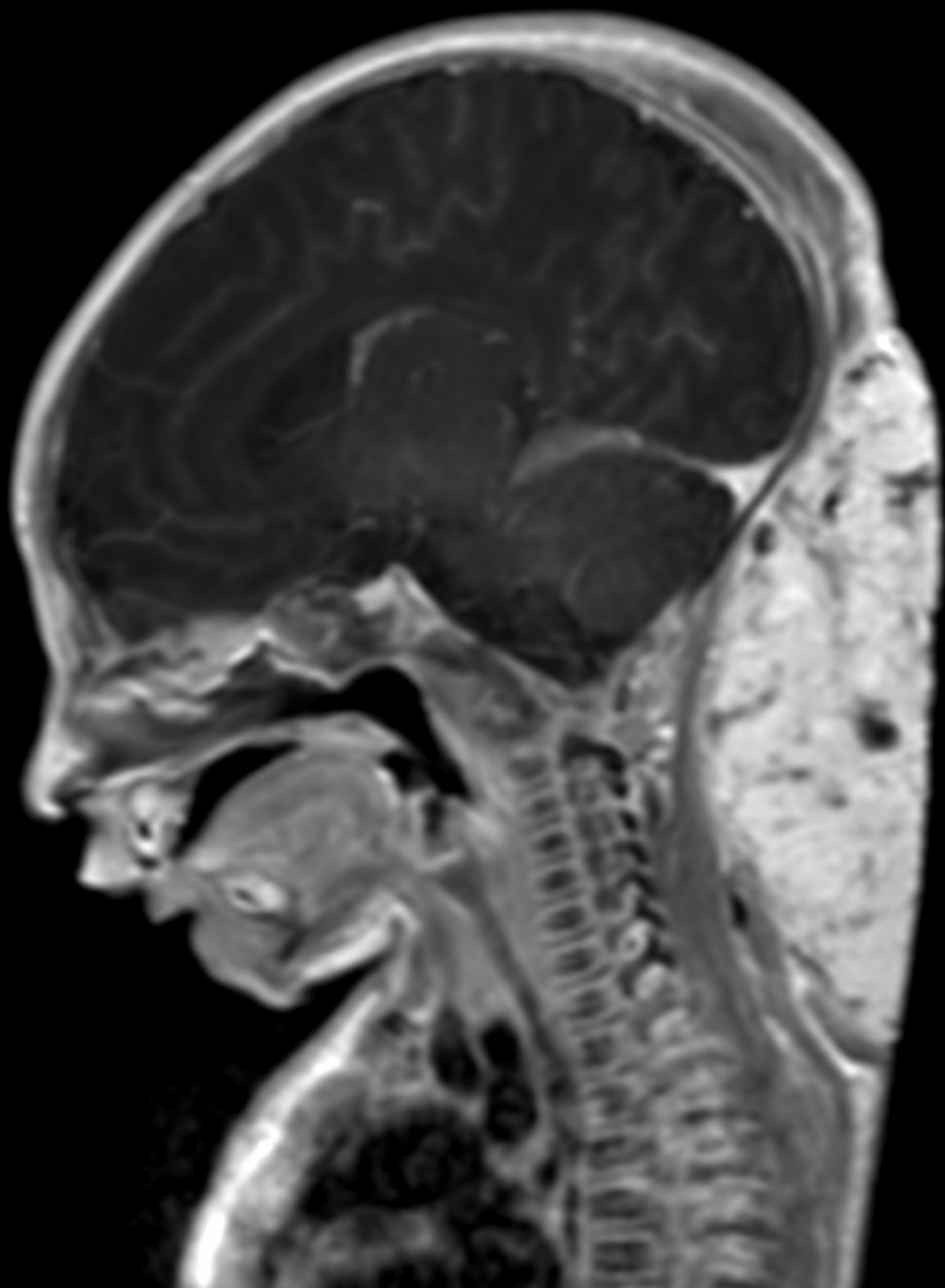
M, 1do



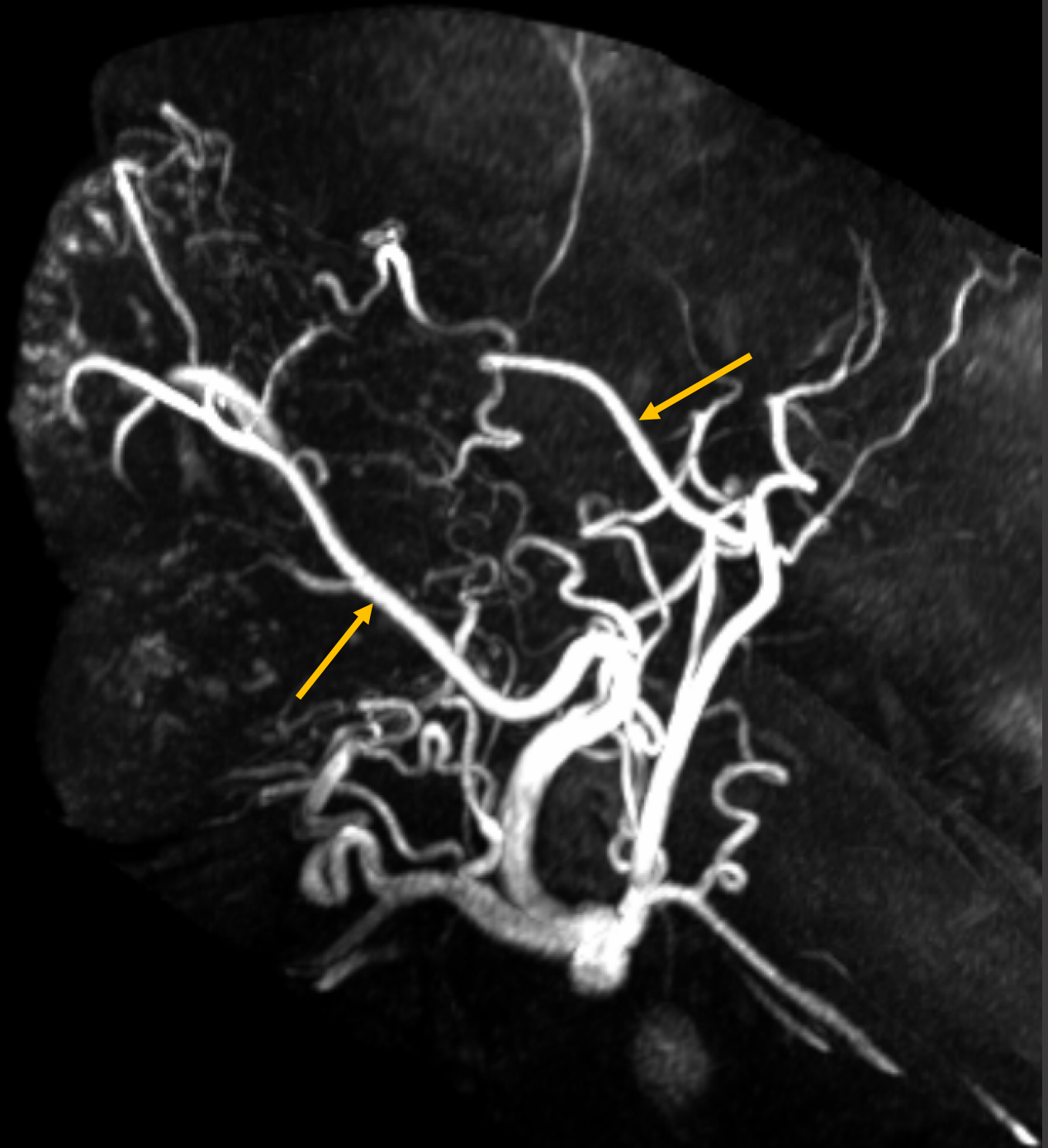M, 1do



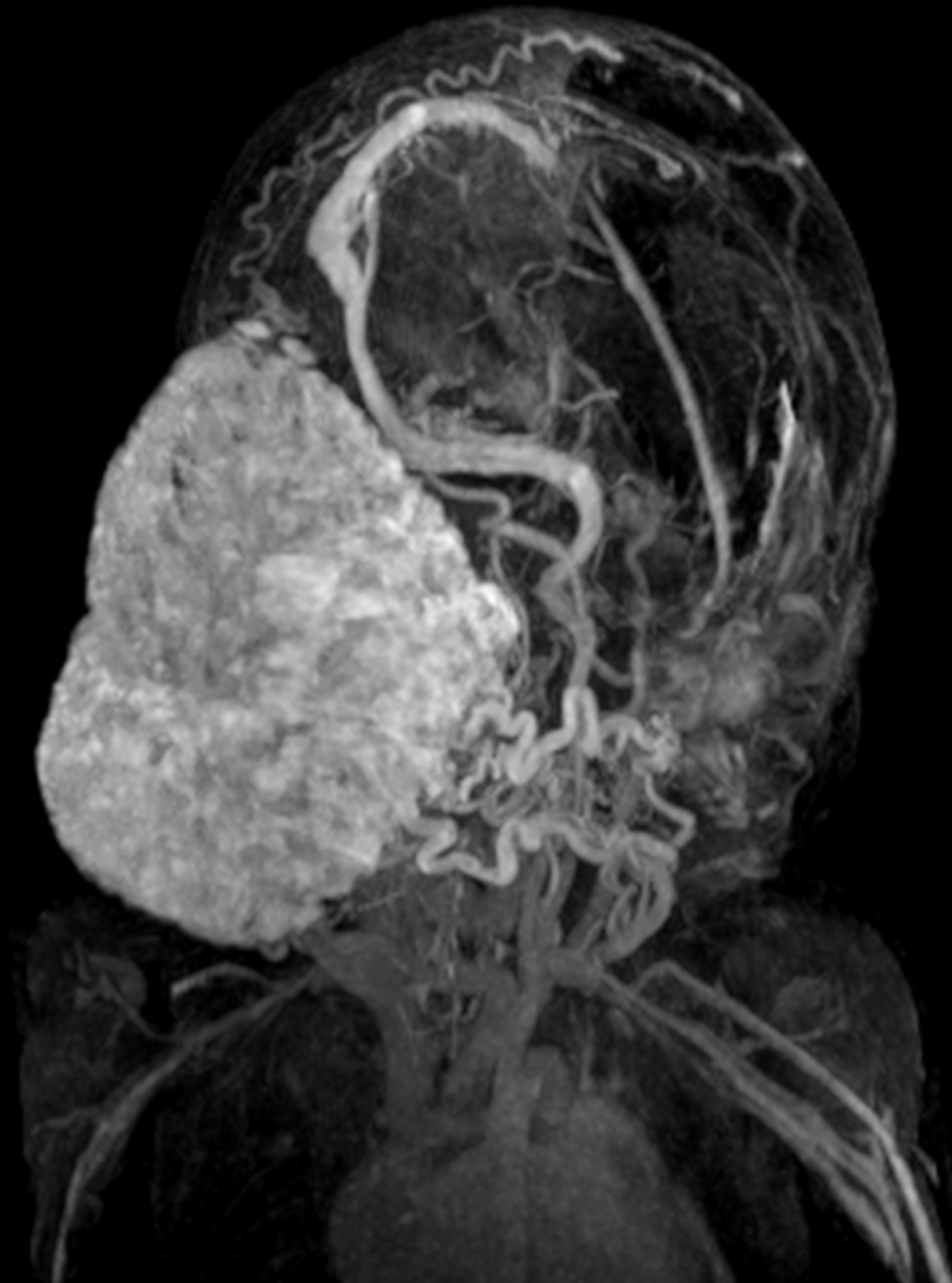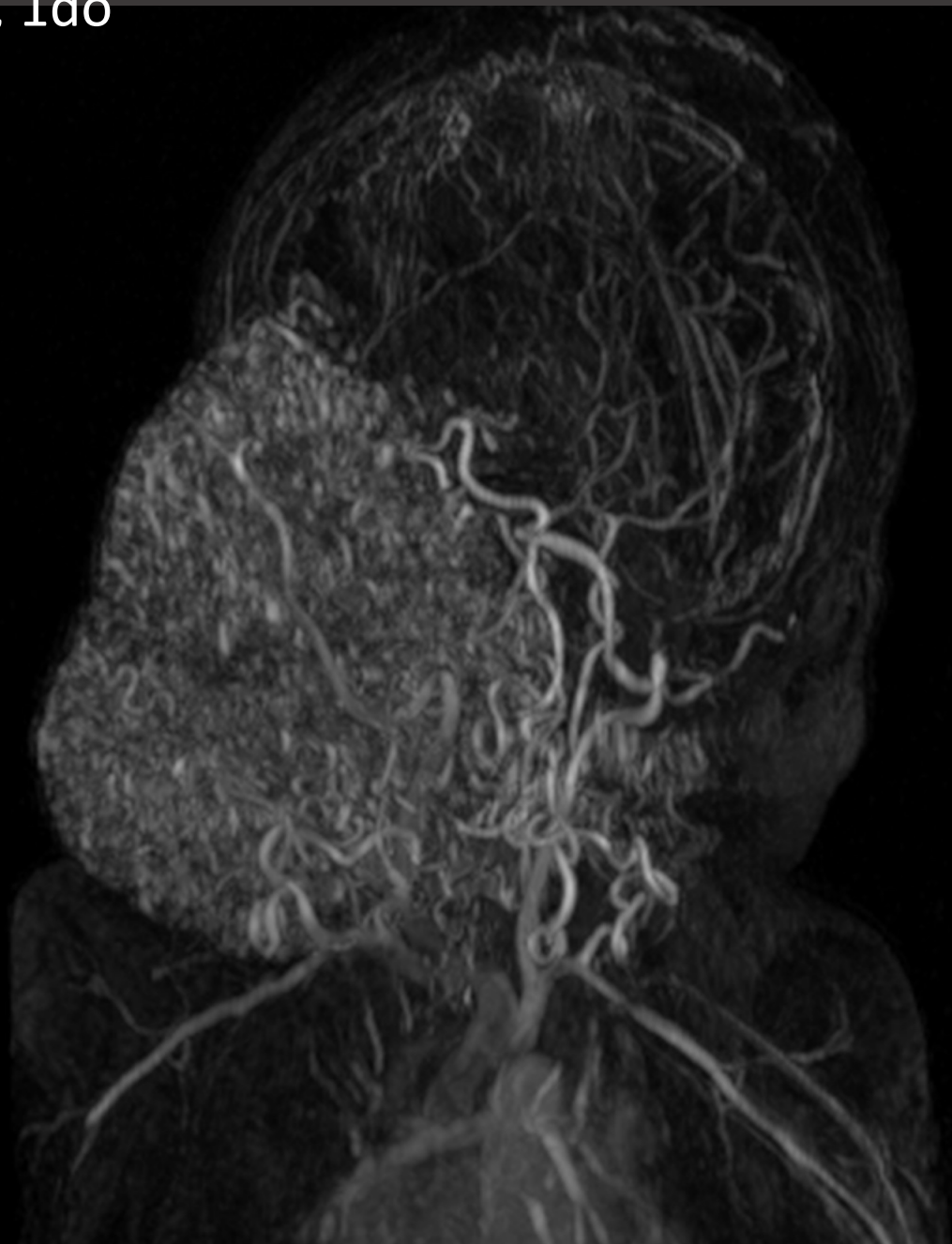
M, 1do

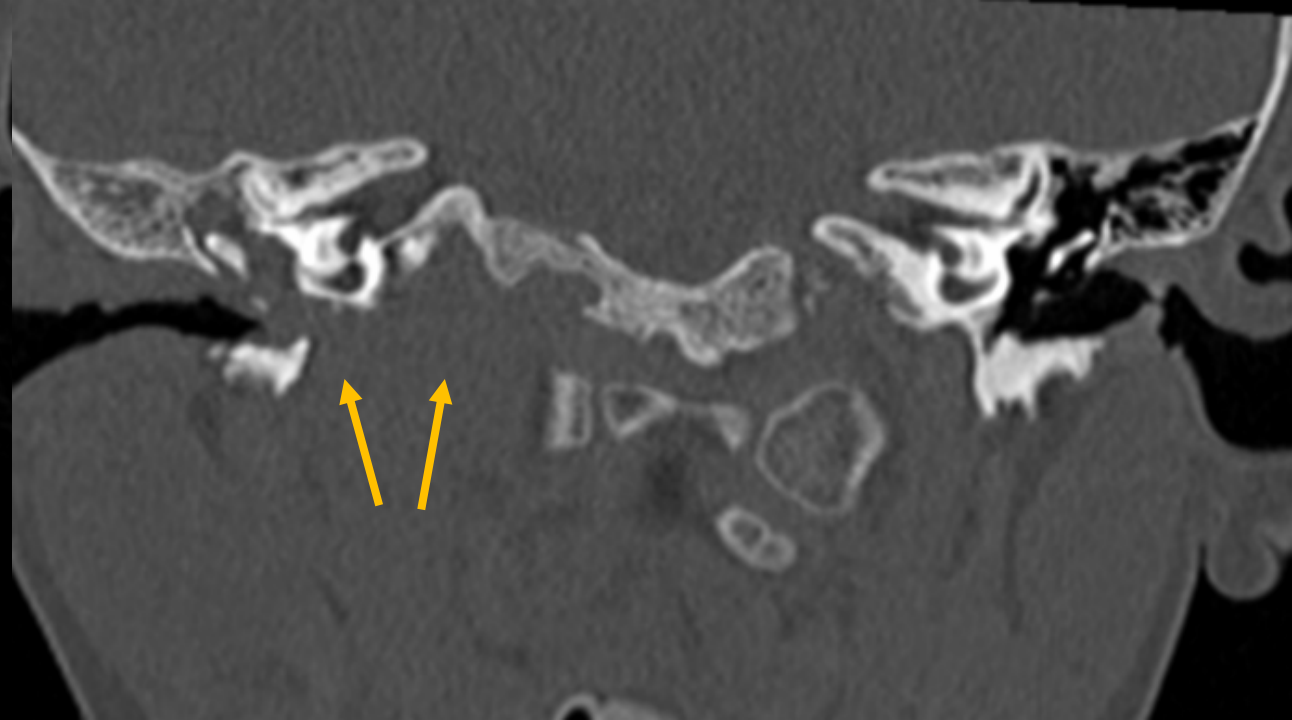
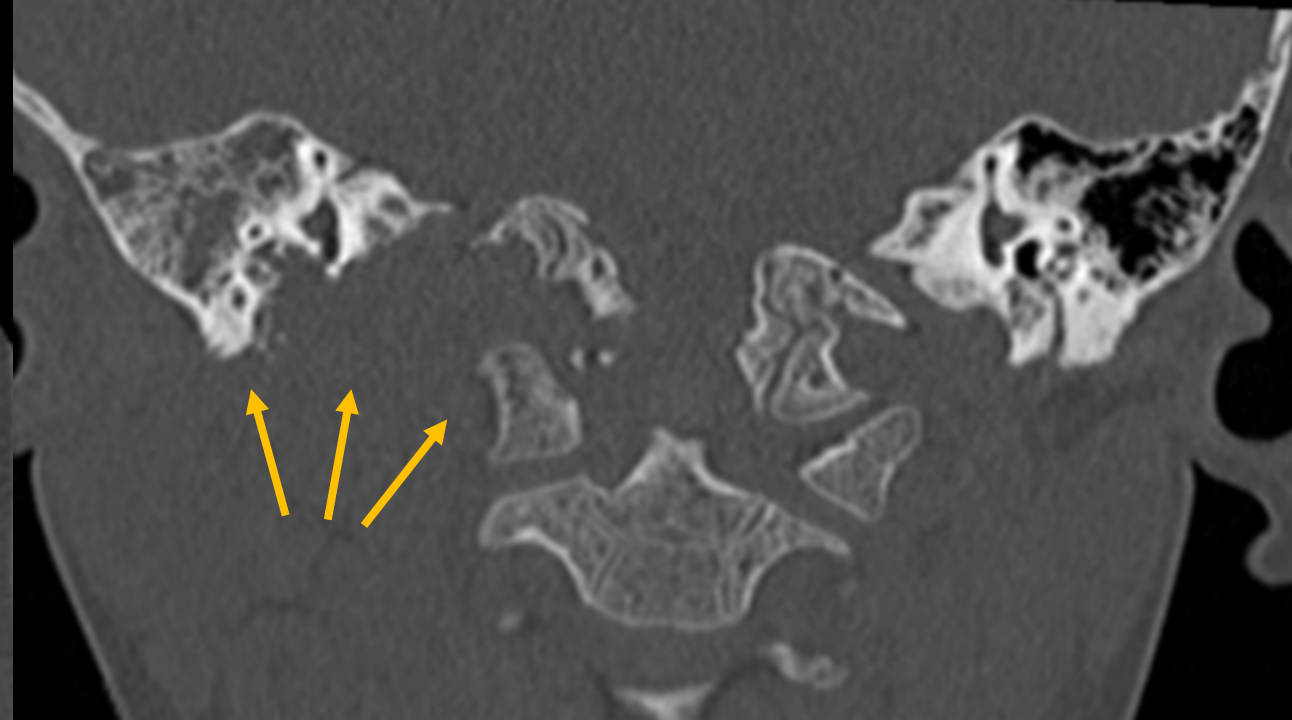
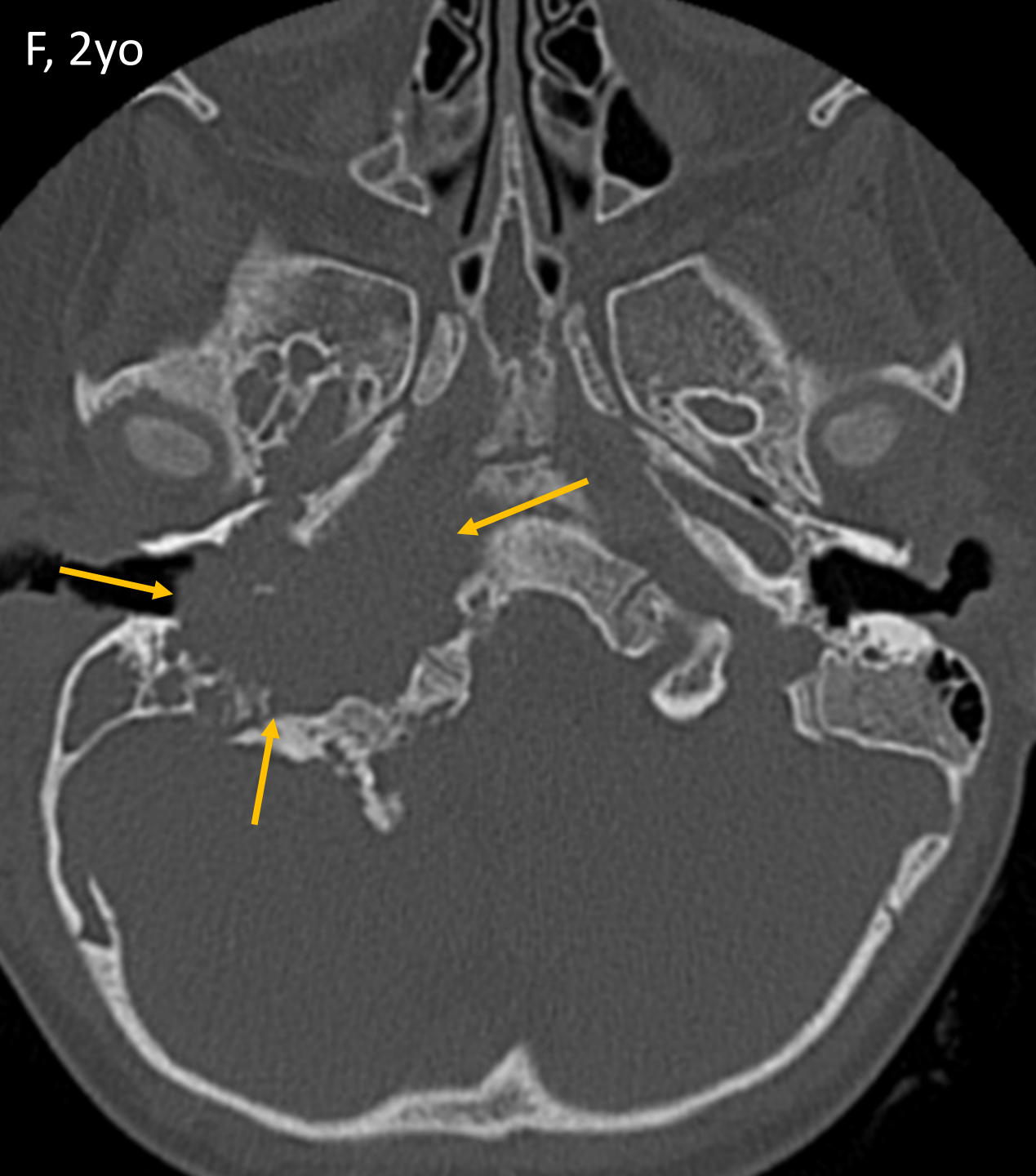


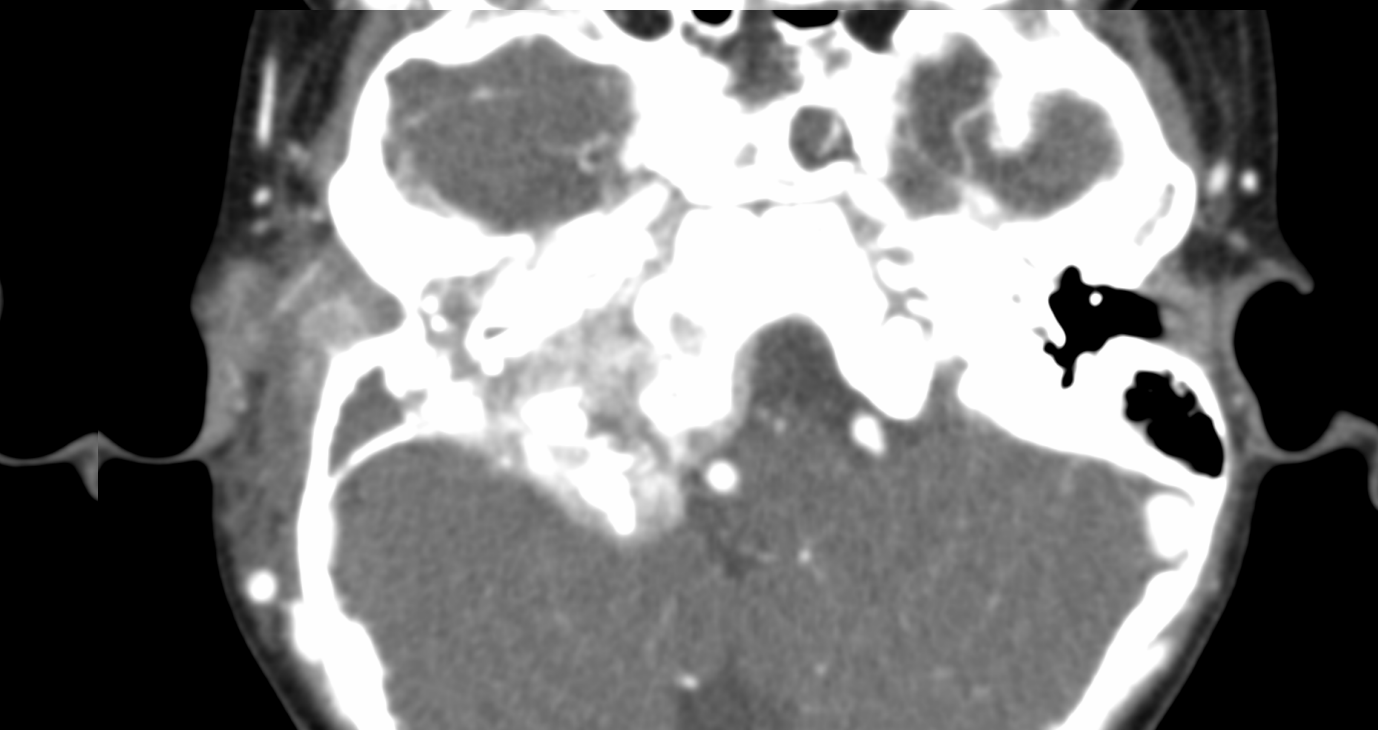
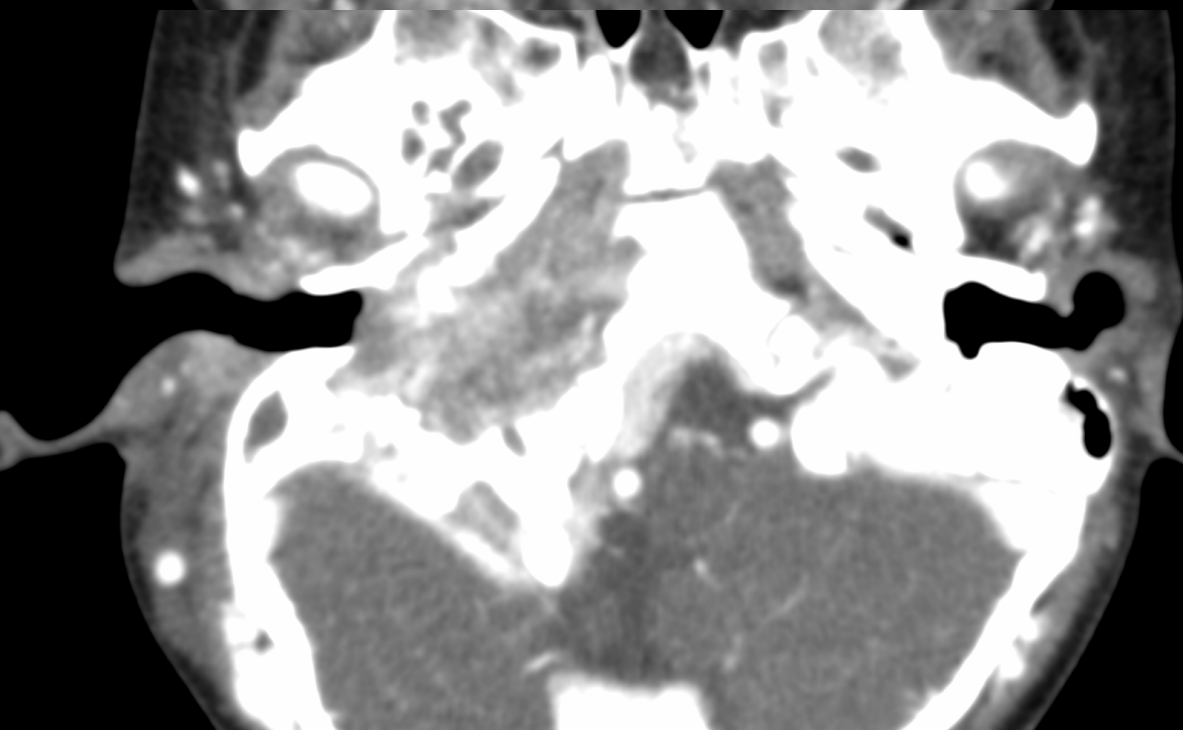
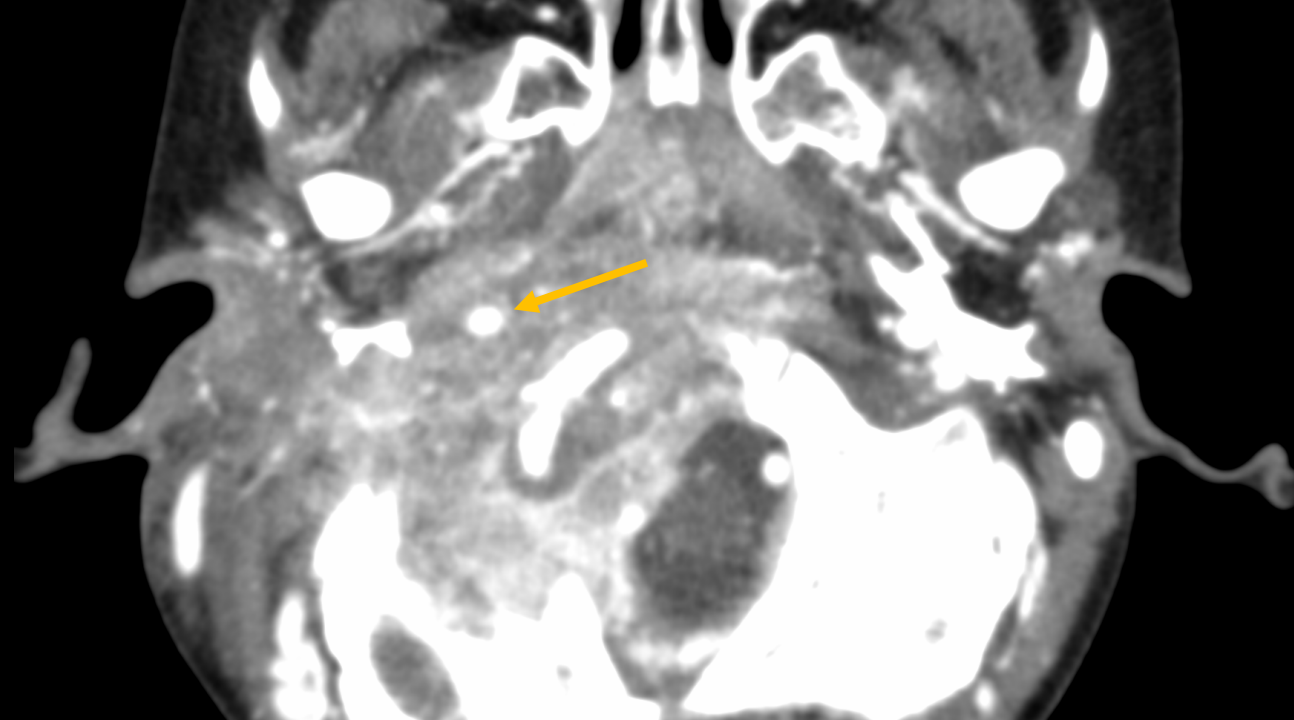
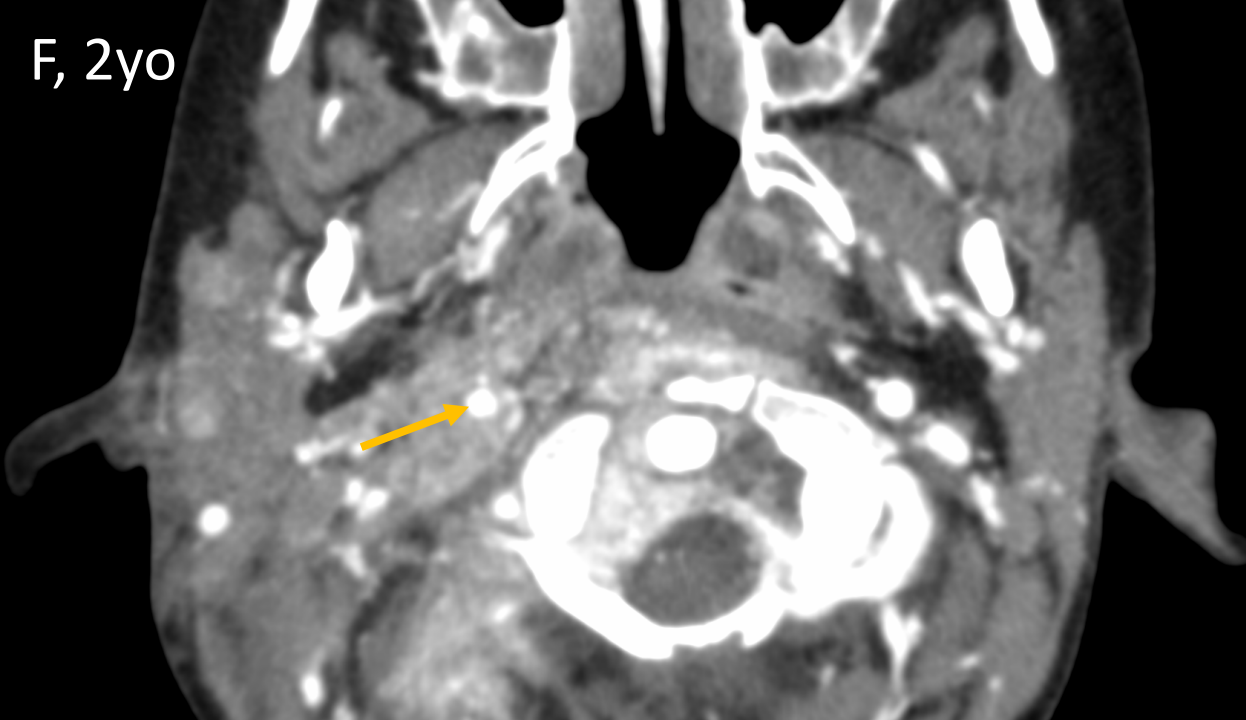
M, 1do

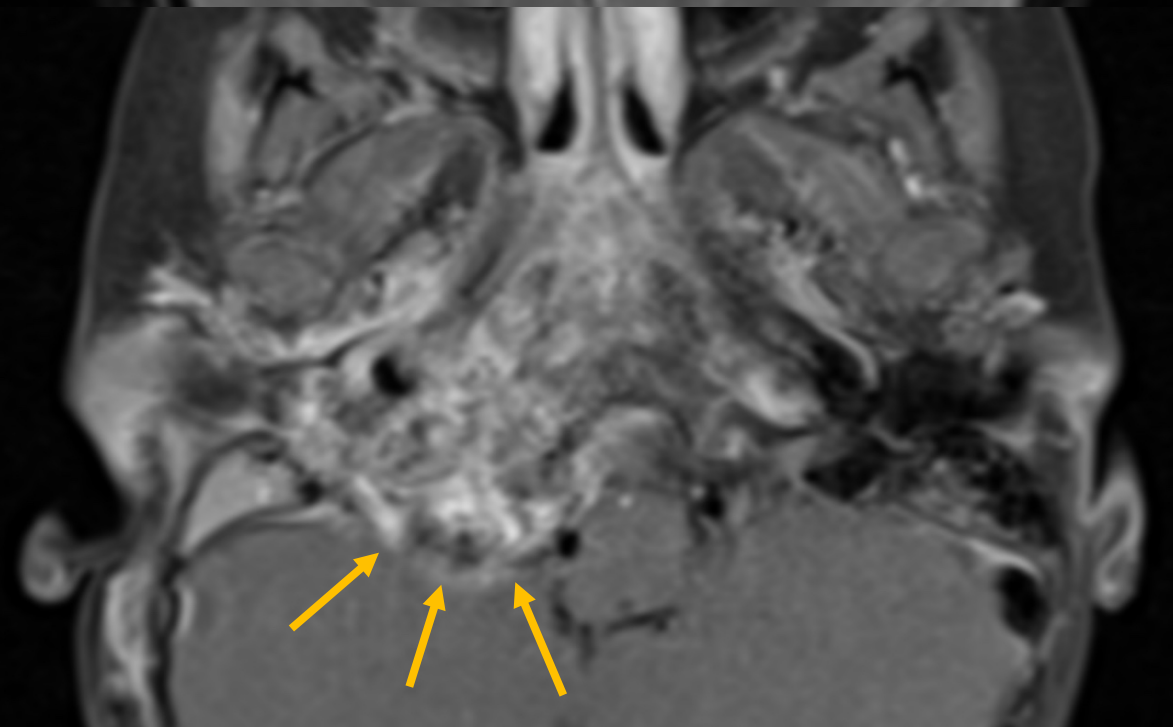
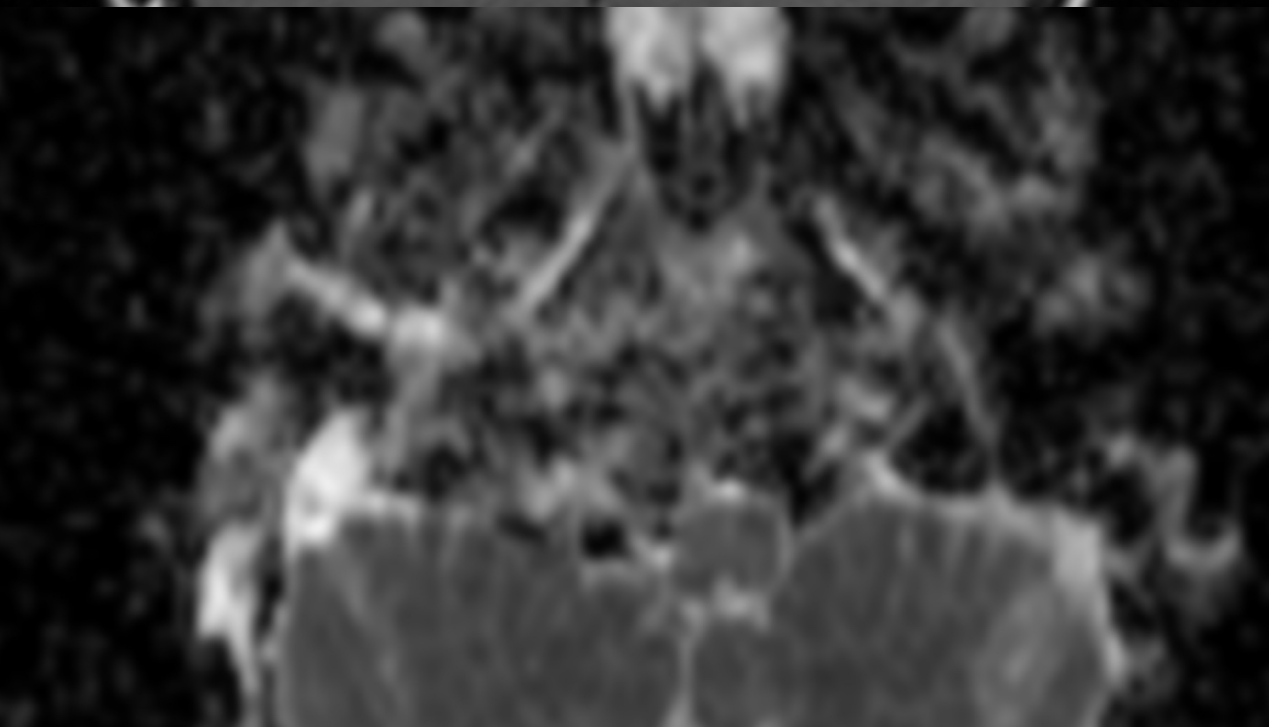
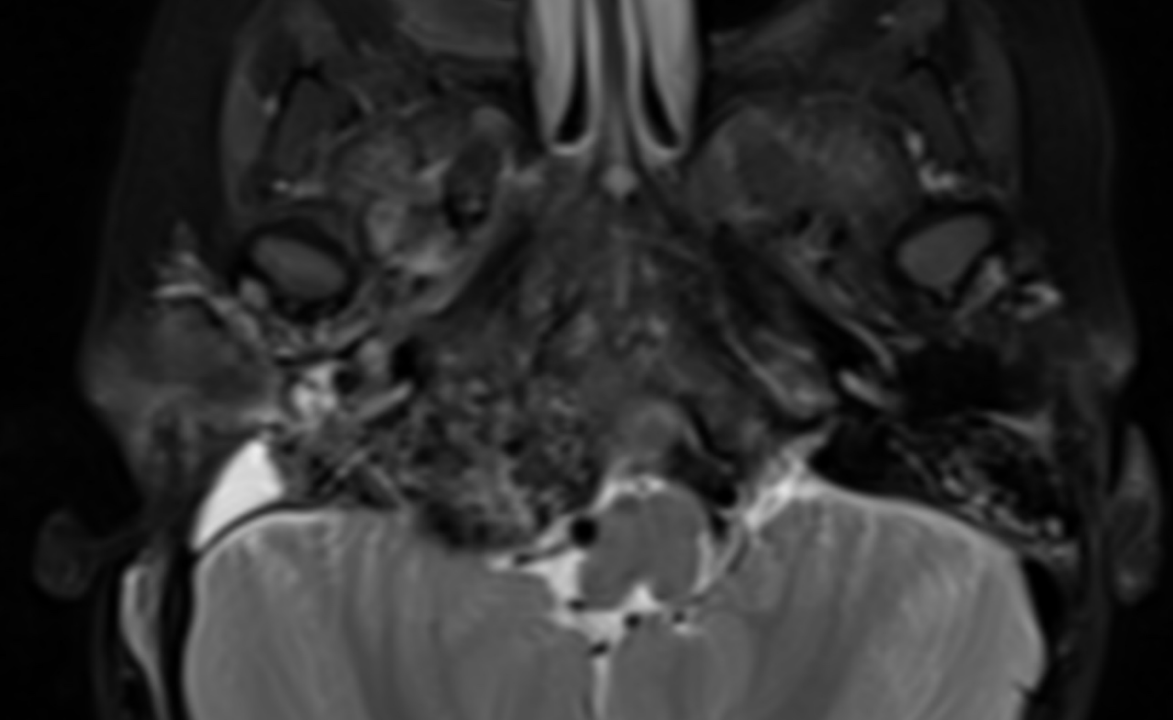
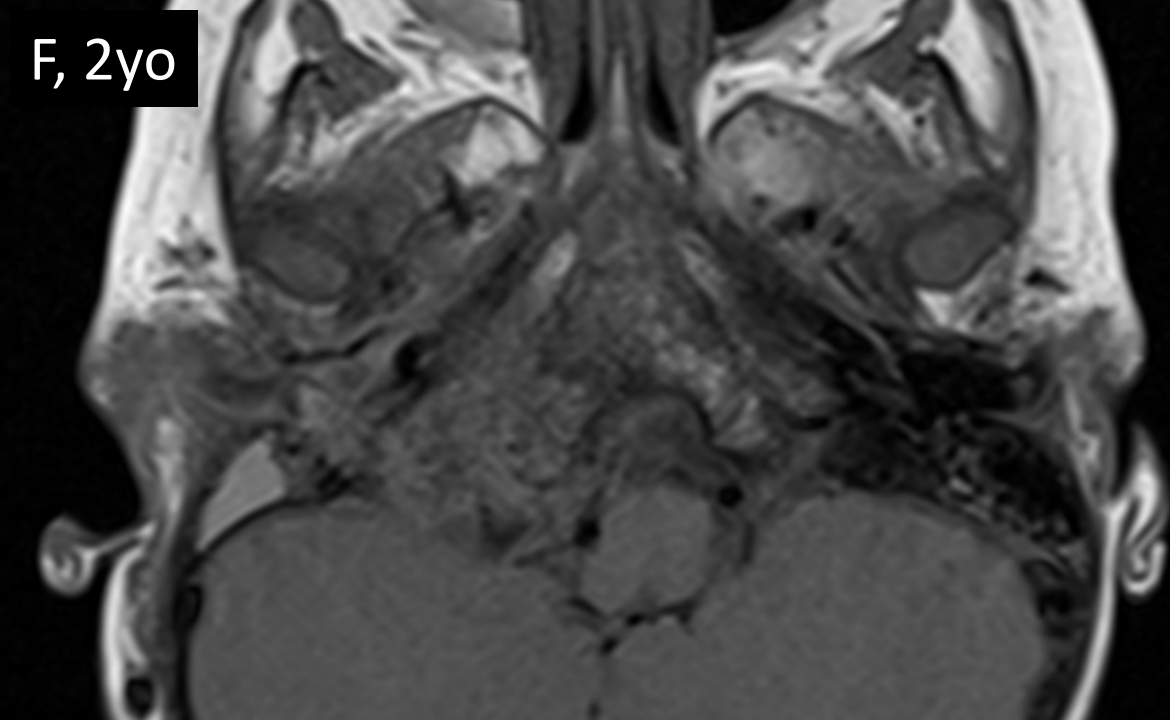


M, 1do







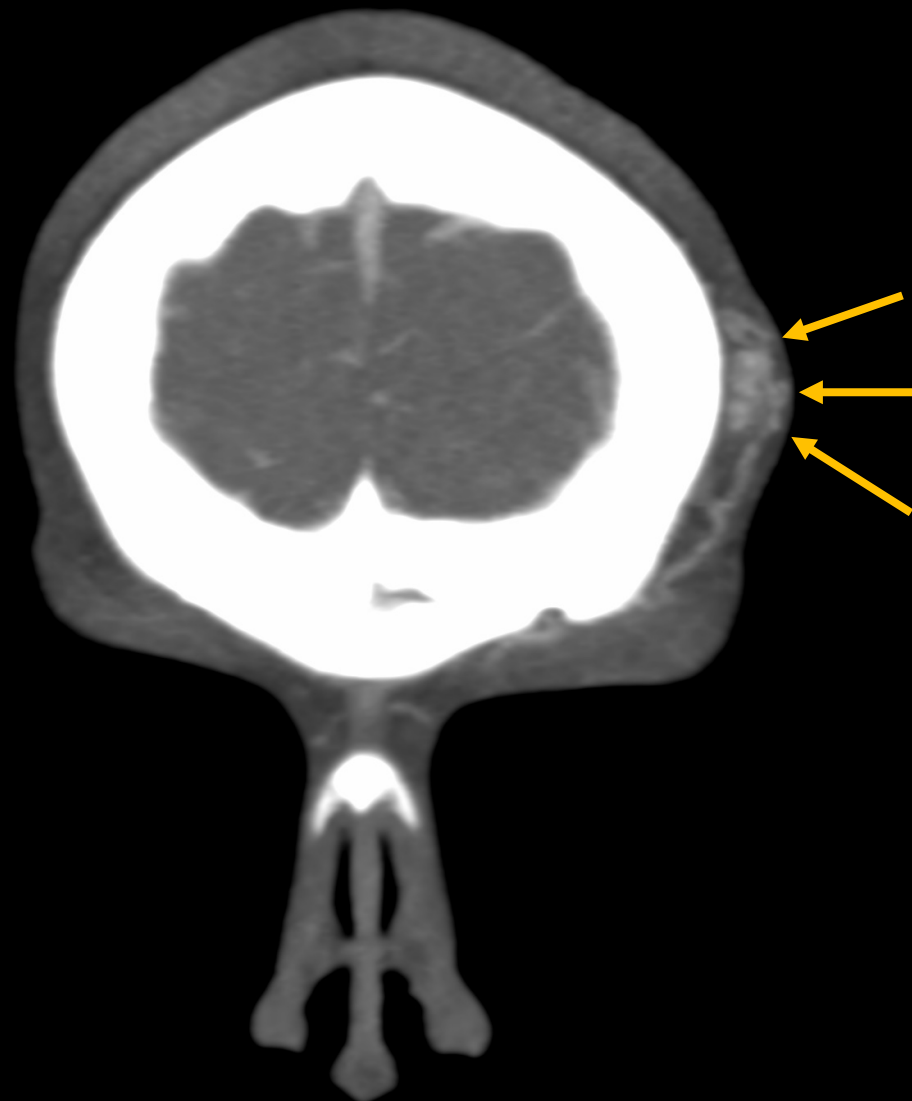
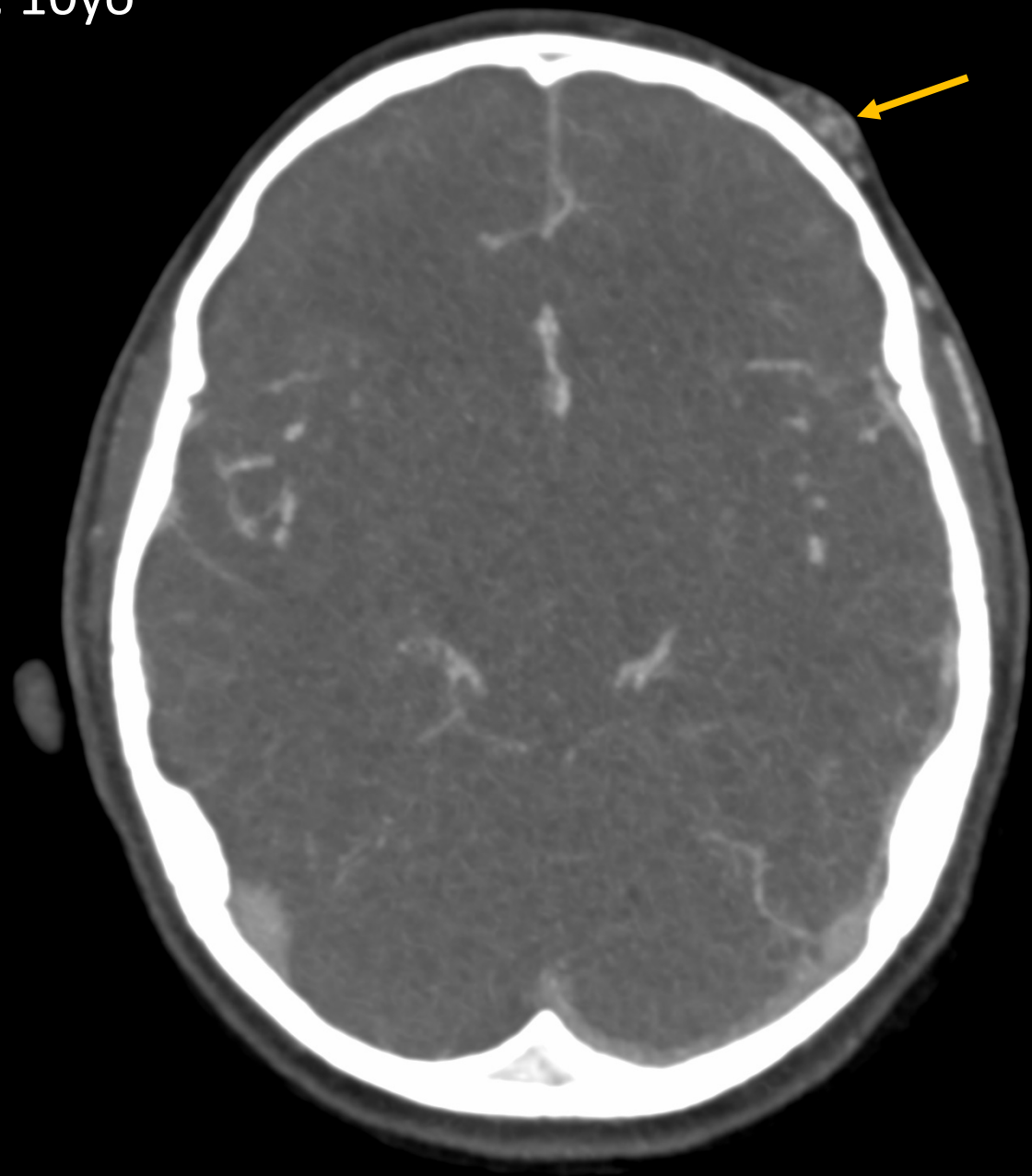


Kaposiform Hemangioendothelioma

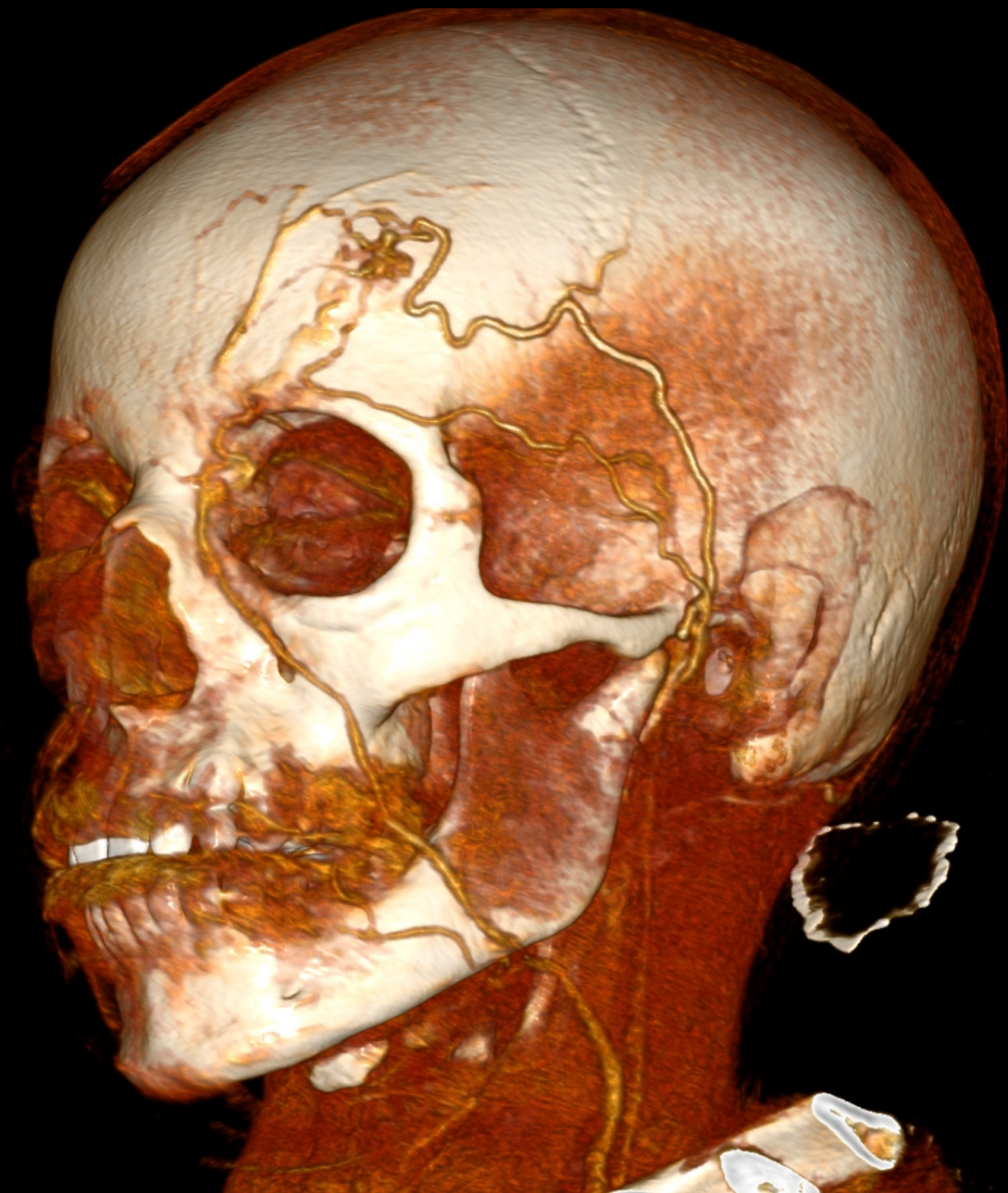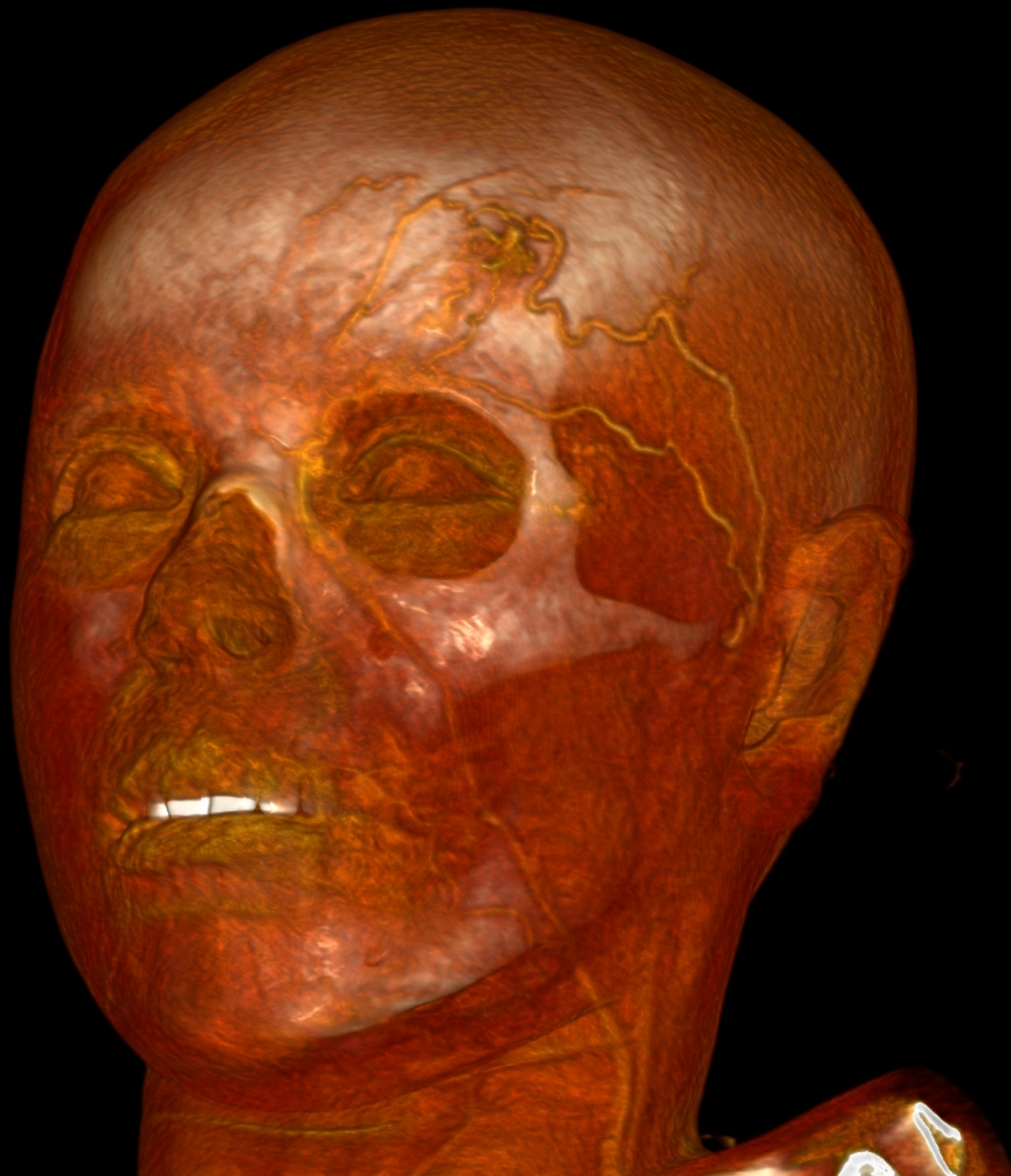
Locally aggressive or borderline vascular tumors	
Kaposiform hemangioendothelioma * °	GNA14
Retiform hemangioendothelioma	
Papillary intralymphatic angioendothelioma (PILA), Dabska tumor	
Composite hemangioendothelioma	
Pseudomyogenic hemangioendothelioma	FOSB
Polymorphous hemangioendothelioma	
Hemangioendothelioma not otherwise specified	
Kaposi sarcoma	
Others	
Malignant vascular tumors	
Angiosarcoma	(Post radiation) MYC
Epithelioid hemangioendothelioma	CAMTA1 / TFE3
Others	

- Borderline vascular tumor
- Ill-defined, invasive, fat stranding
- >50% associated with Kassabach-Merritt syndrome

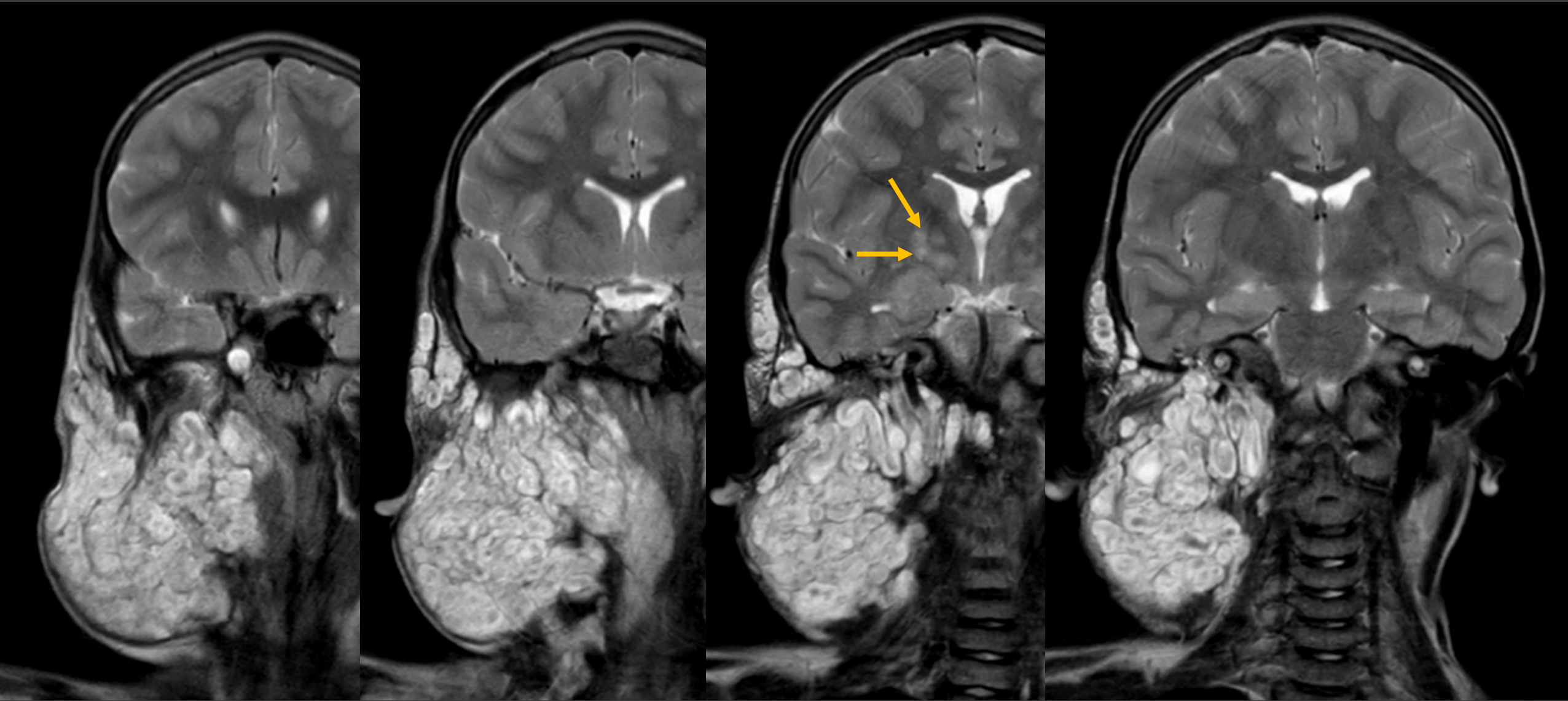
F, 10yo



F, 10yo



F, 7yo



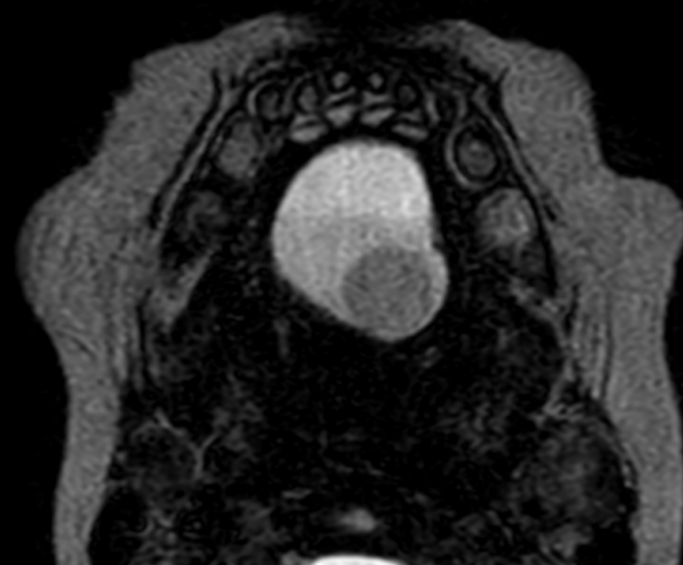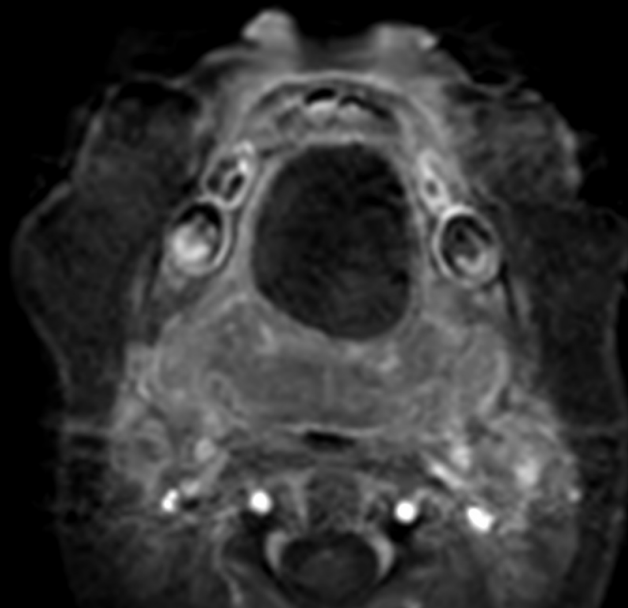
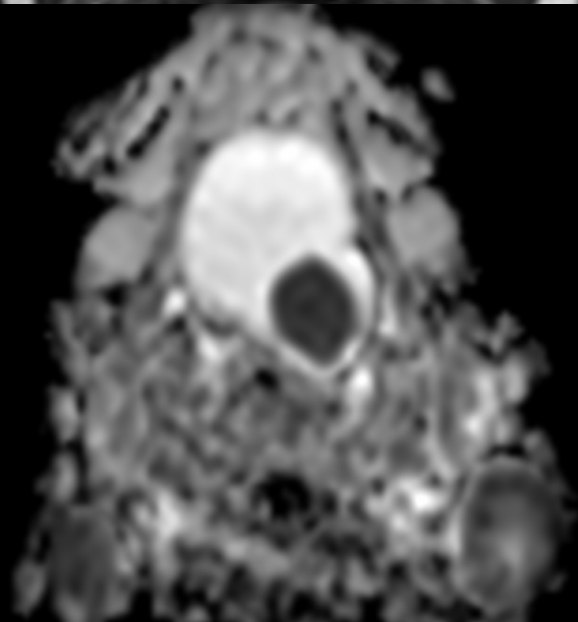
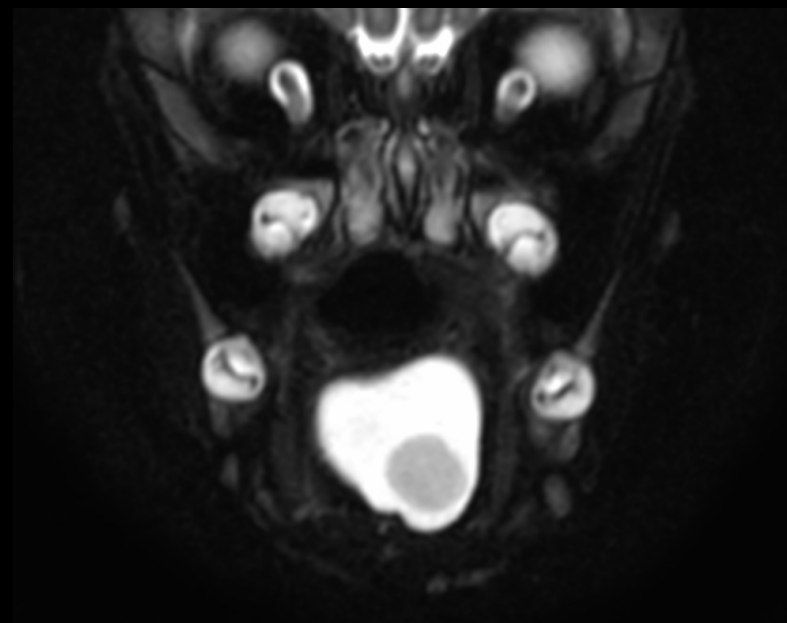
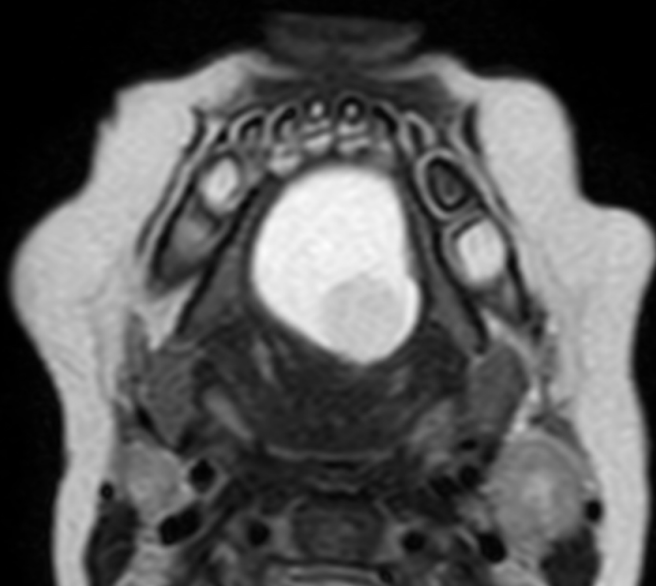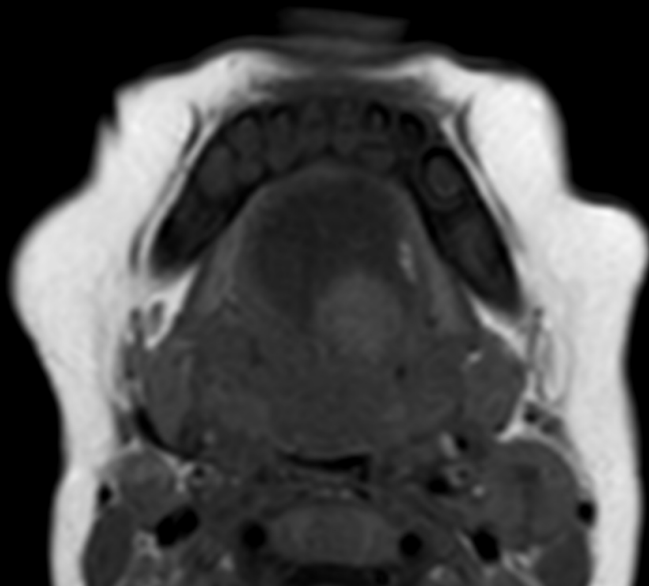
Challenging cases showing mimics and pitfalls

Vascular anomalies

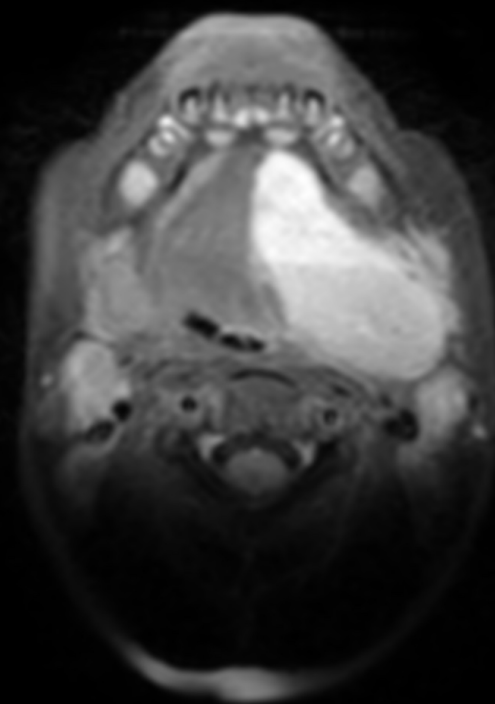
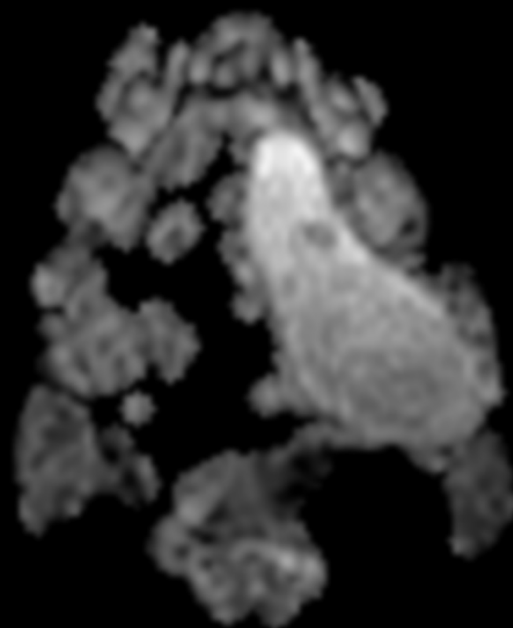
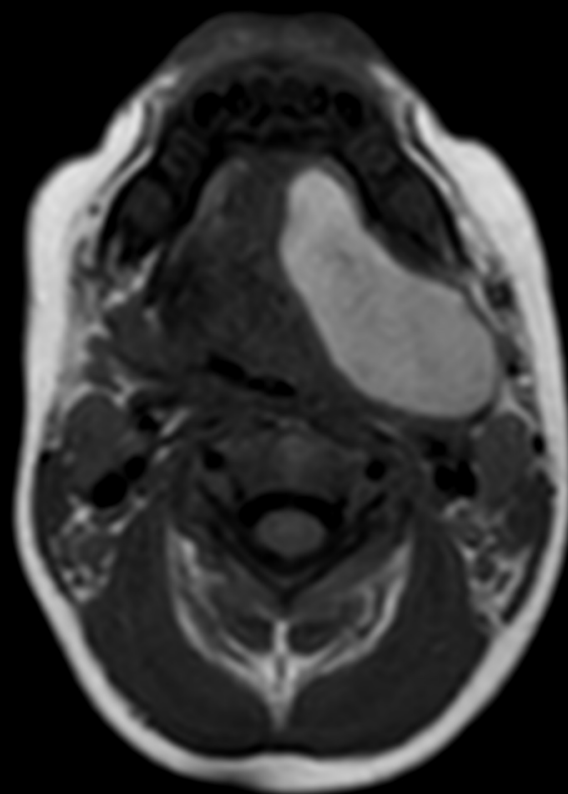
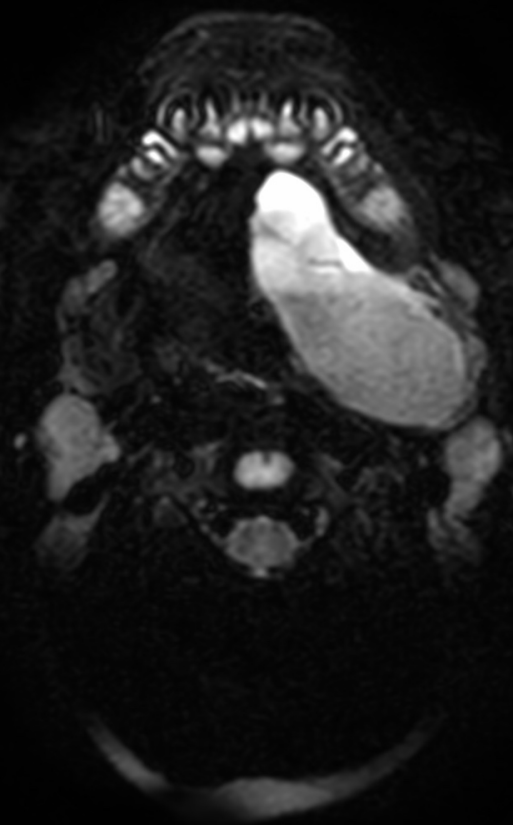
Cystic lesions

Solid lesions

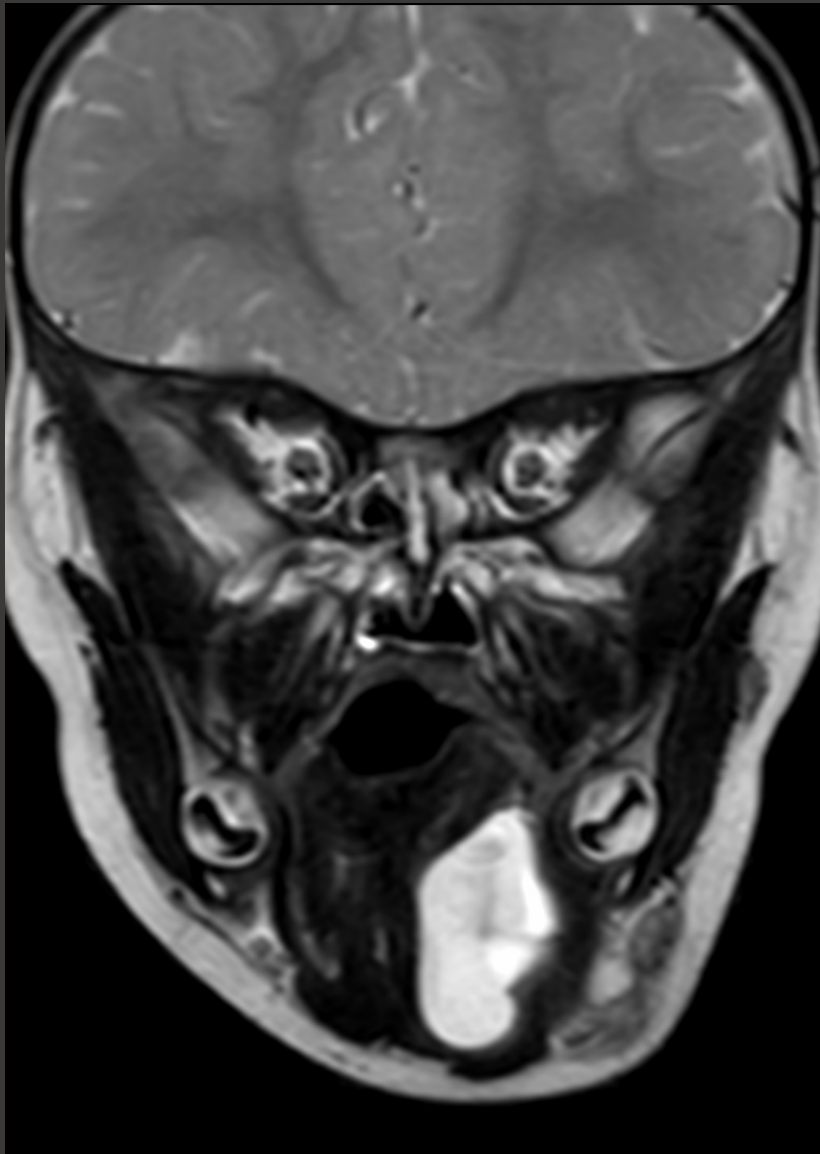
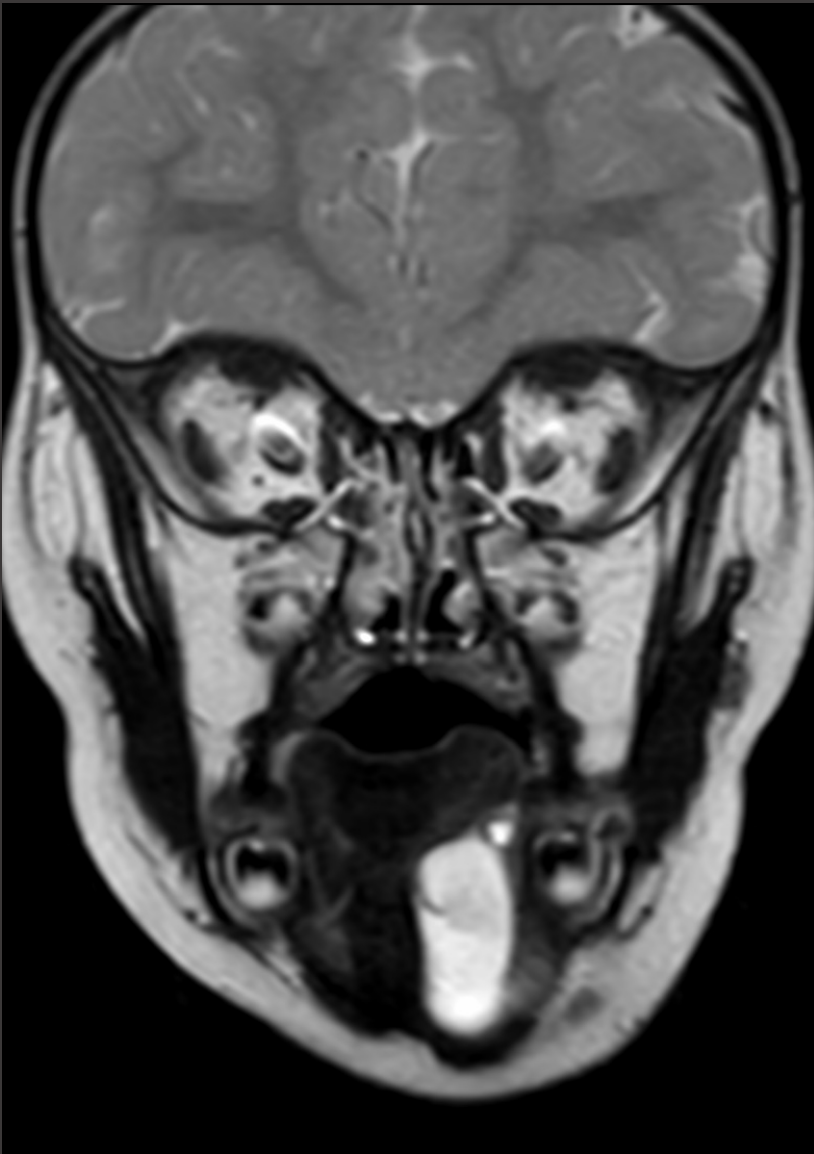
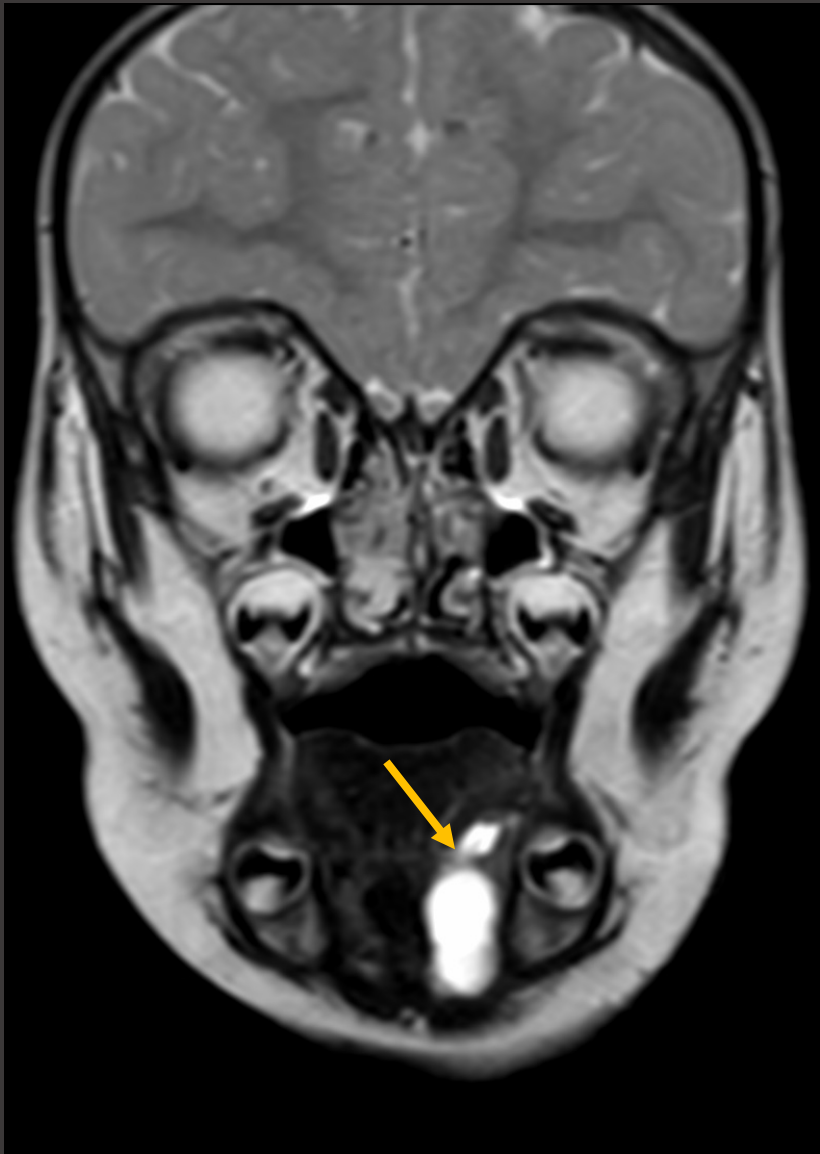M, 6mo



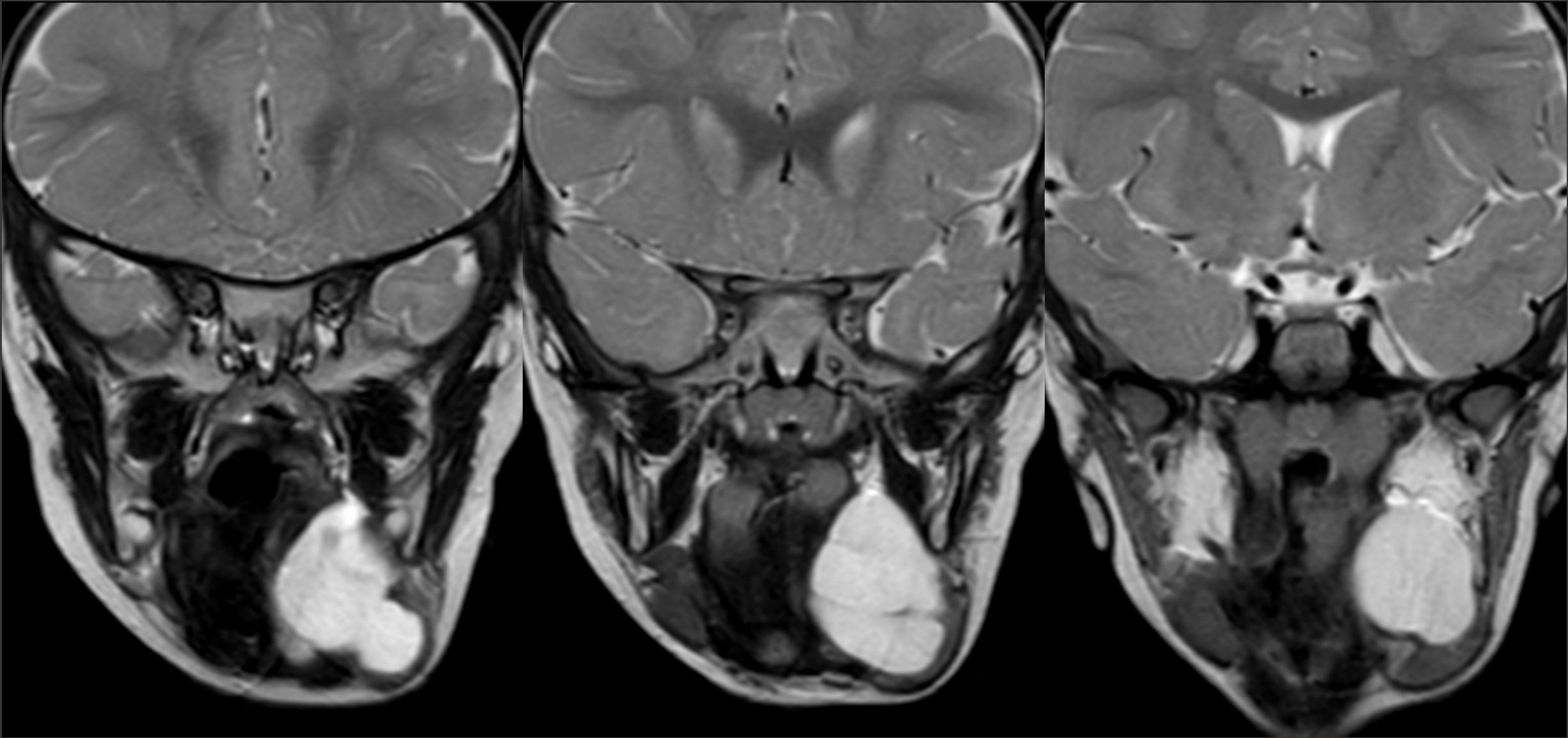
M, 15mo

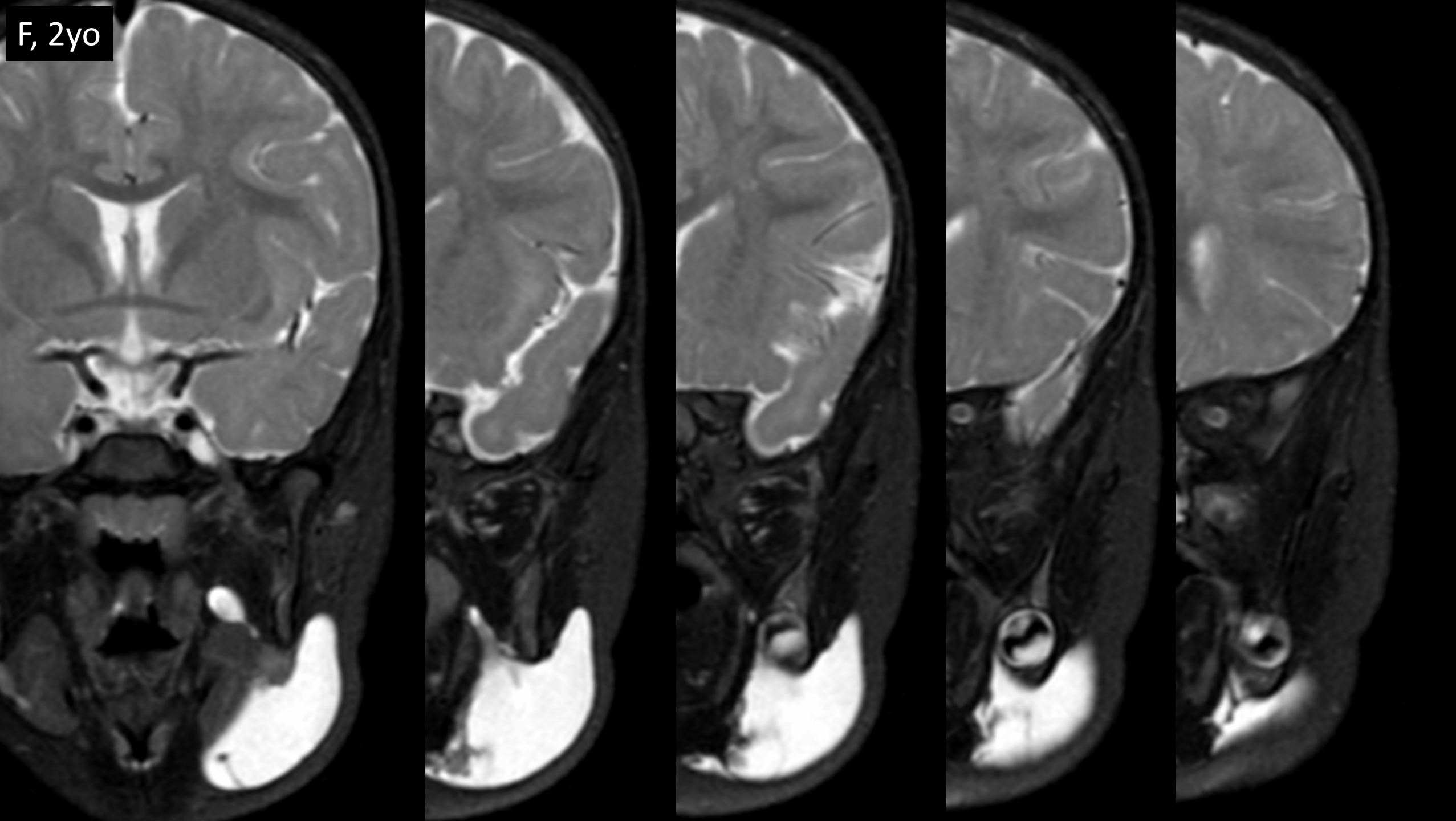


M, 15mo

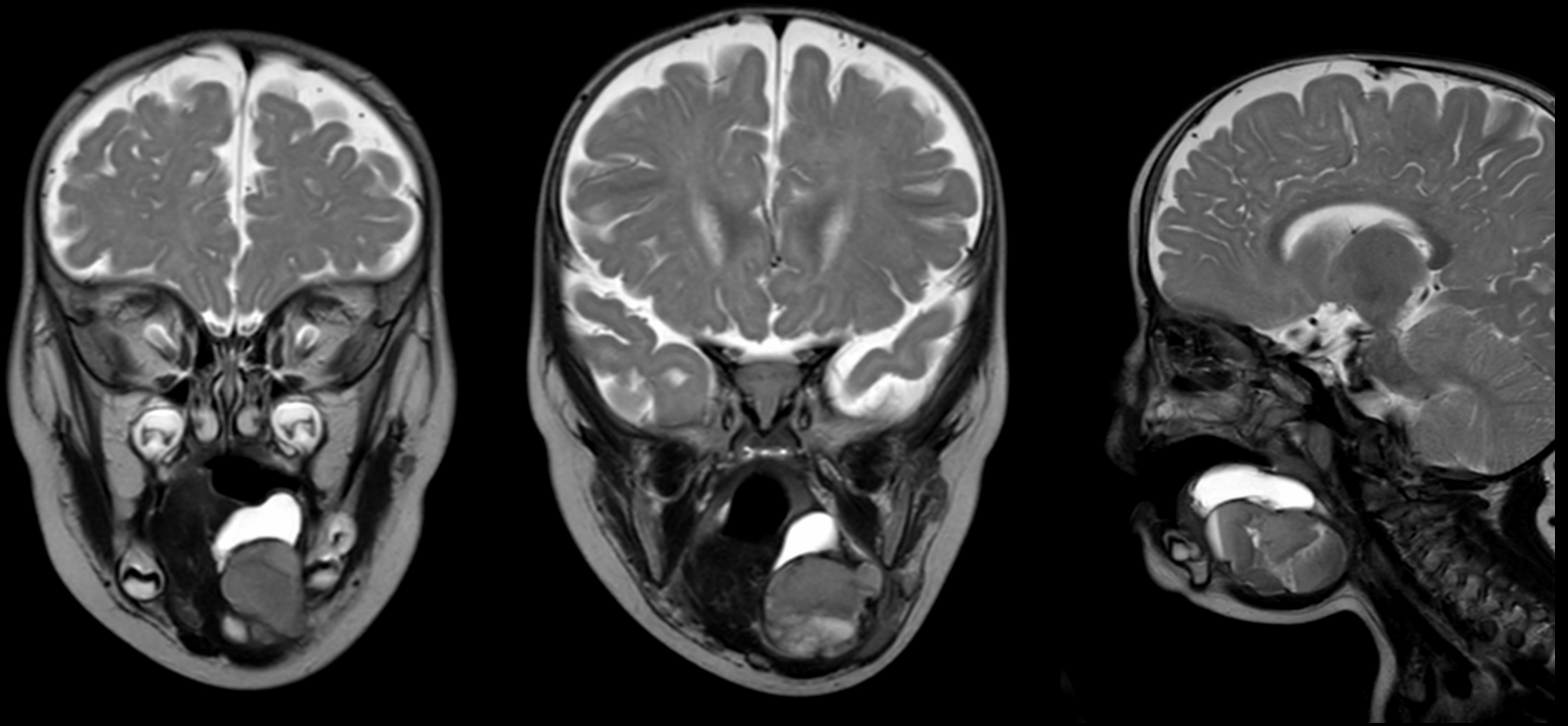


M, 15mo



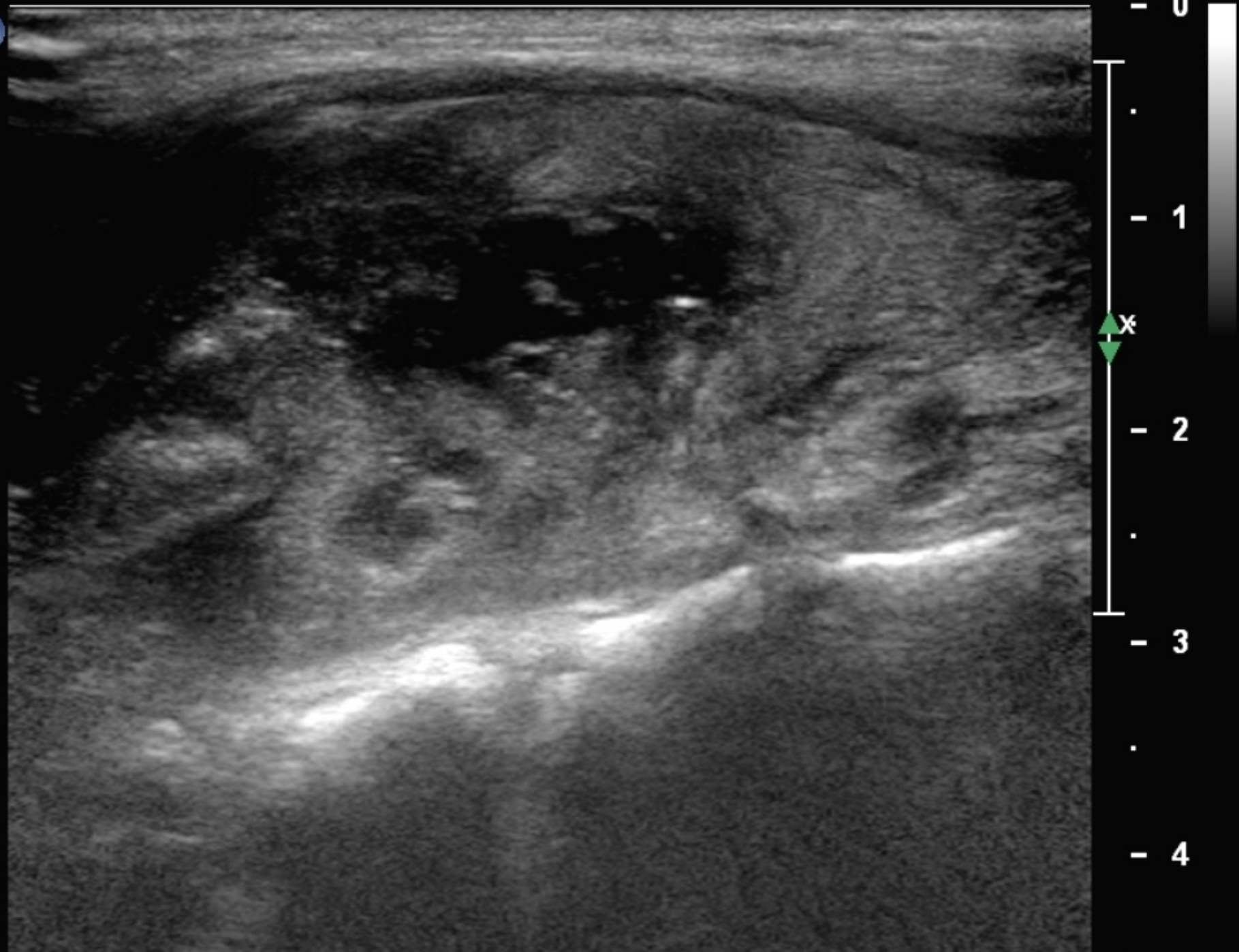


M, 15mo

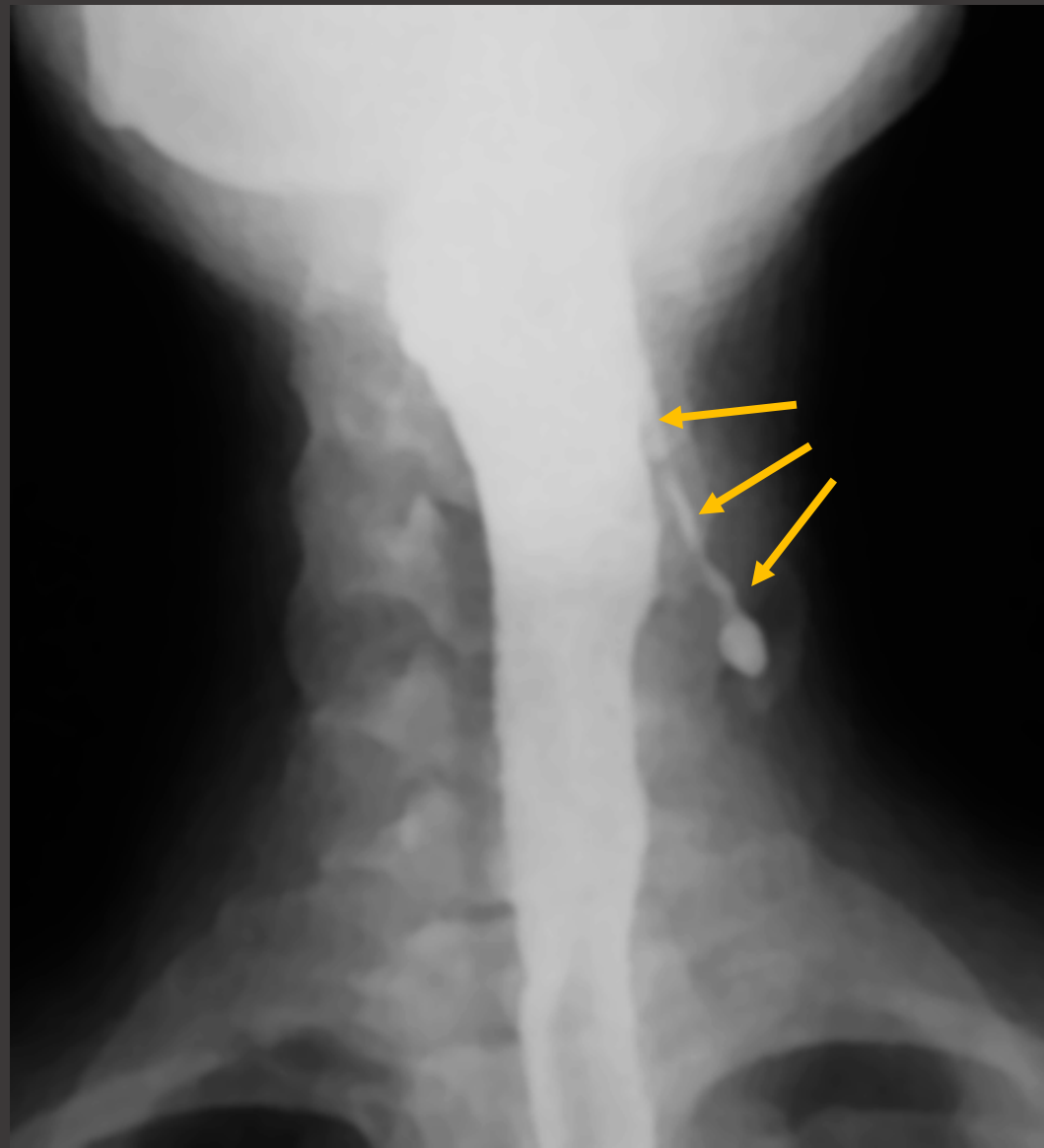
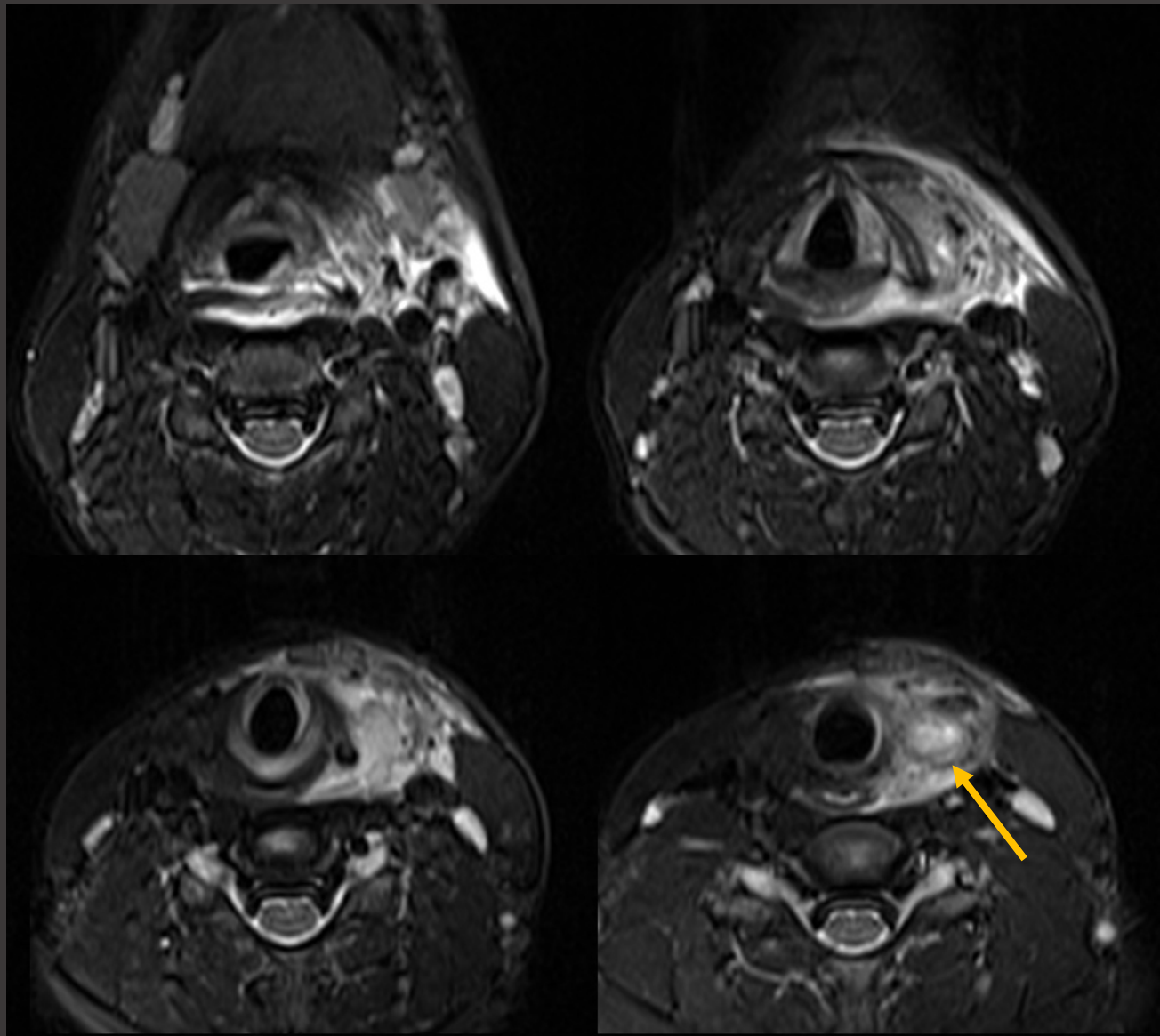


F, 12yo

P



F, 12yo



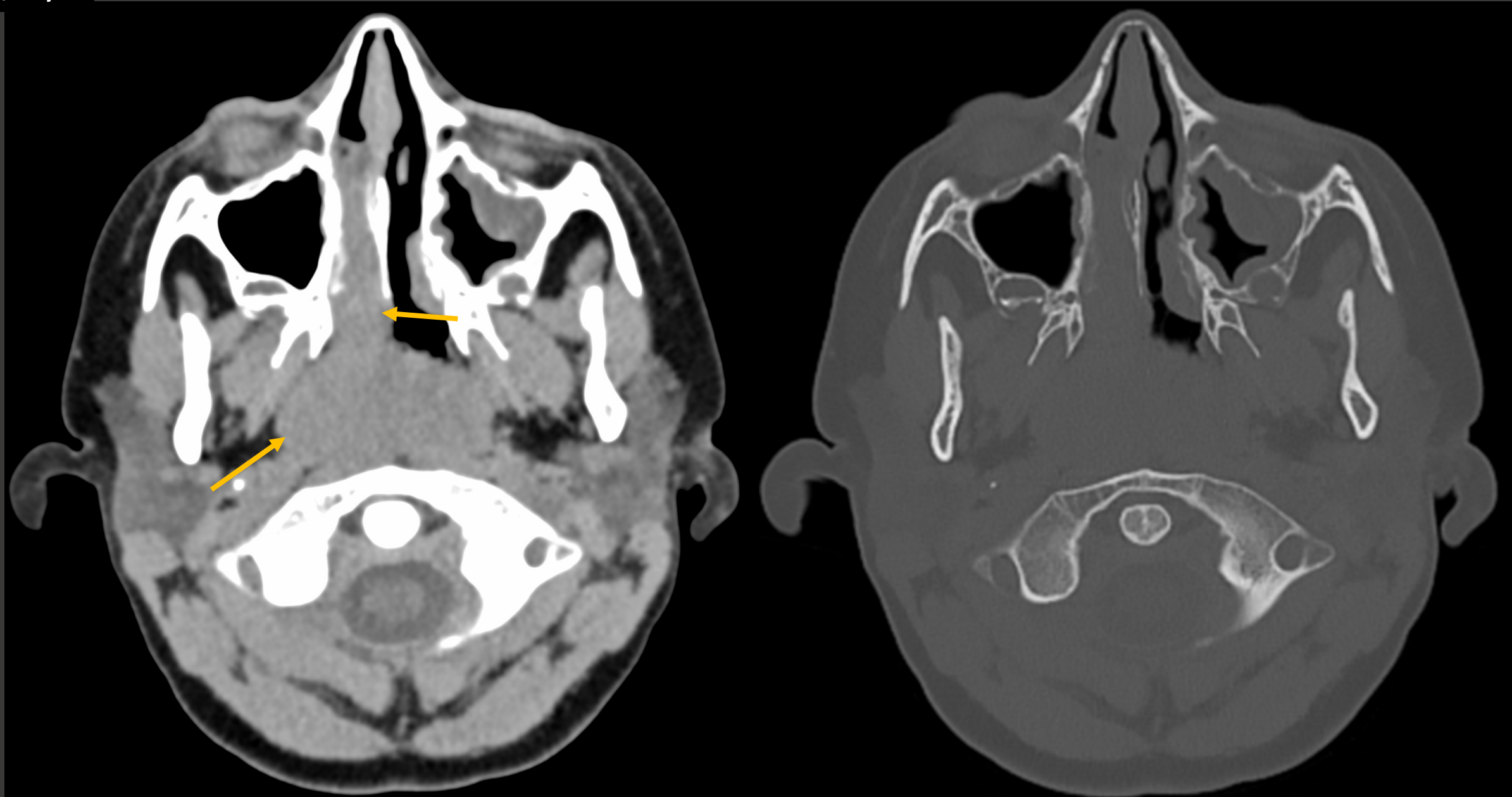
Challenging cases showing mimics and pitfalls

Vascular anomalies

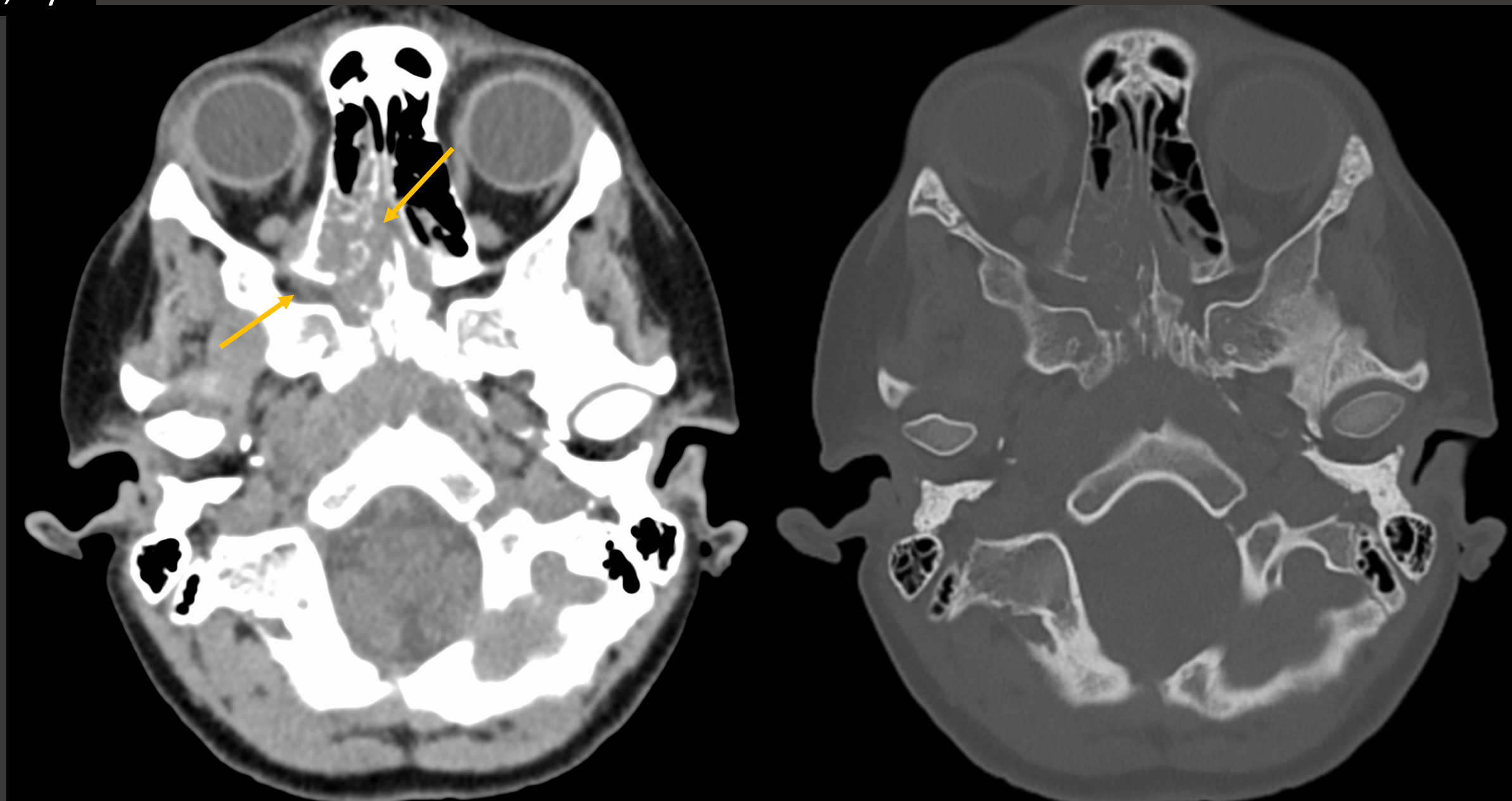
Cystic lesions

Solid lesions

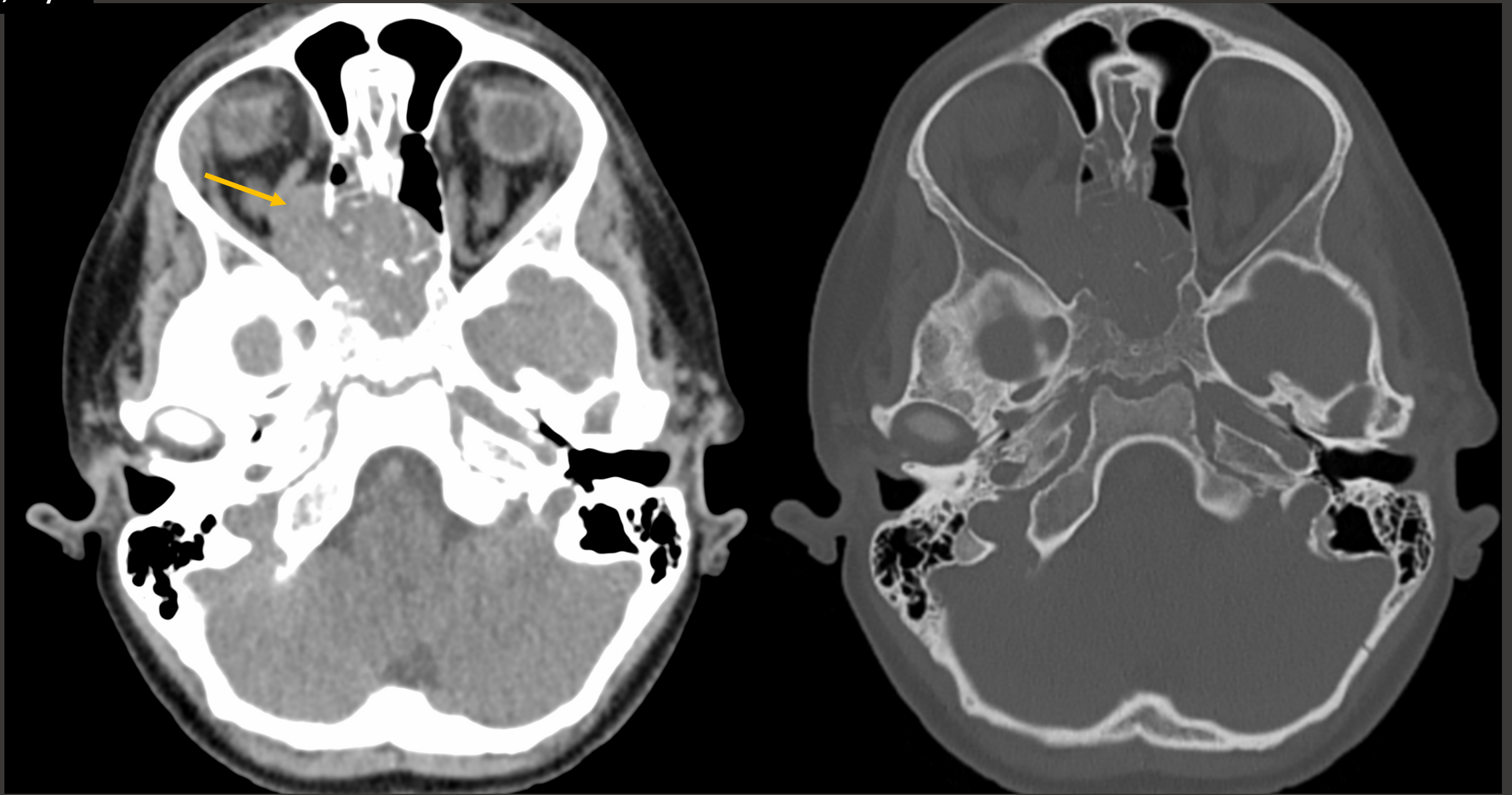
M, 8yo



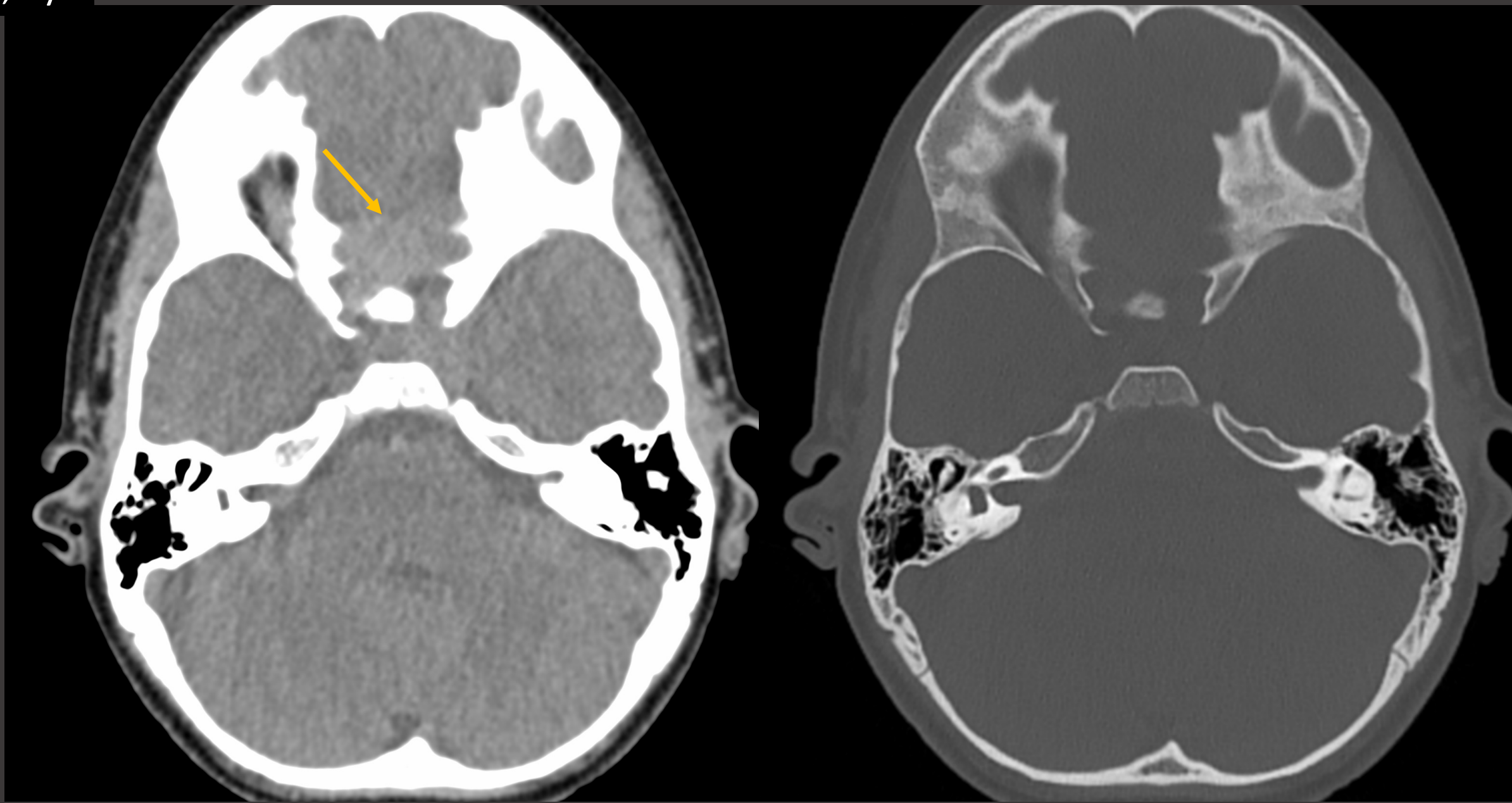
M, 8yo



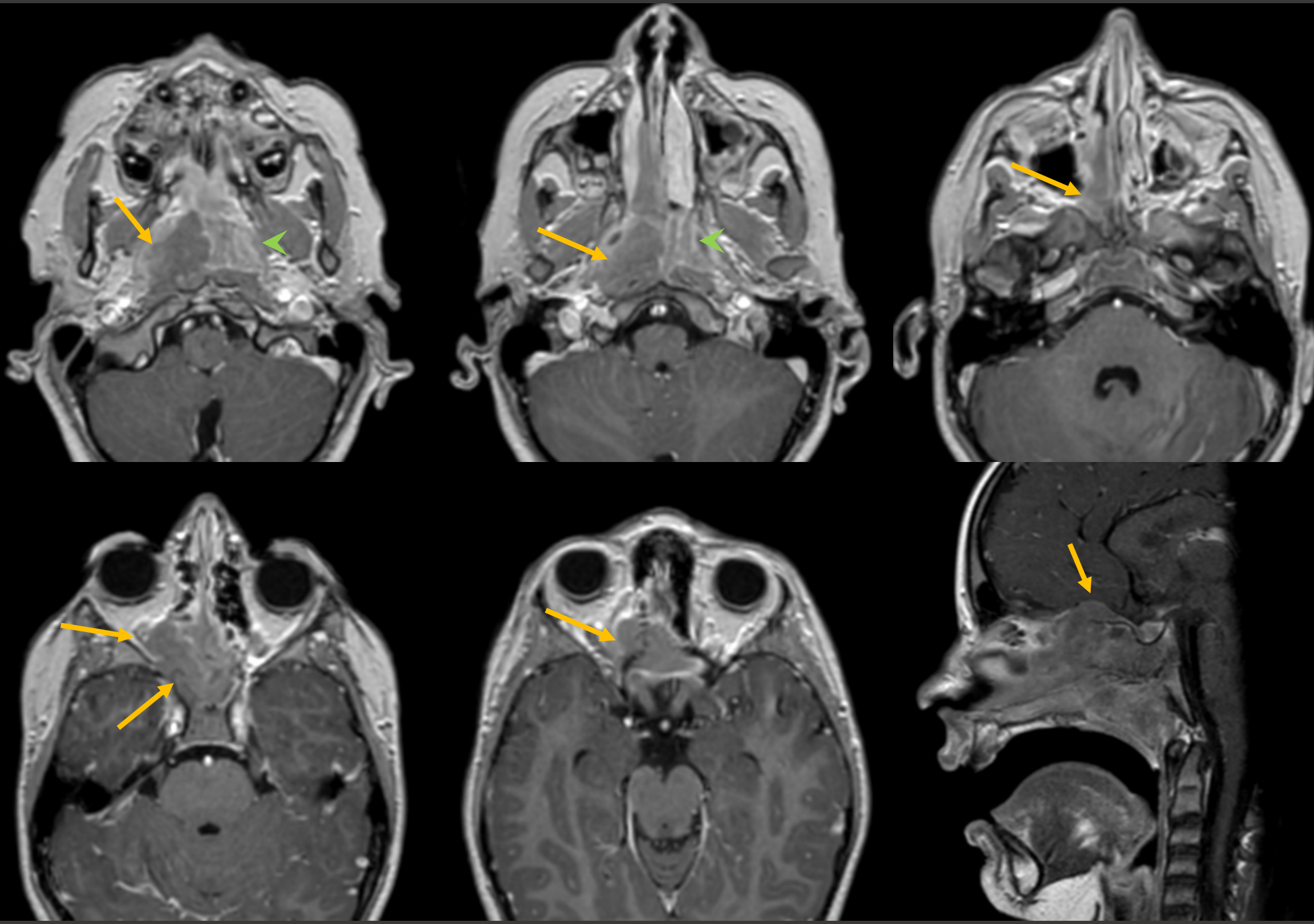
M, 8yo



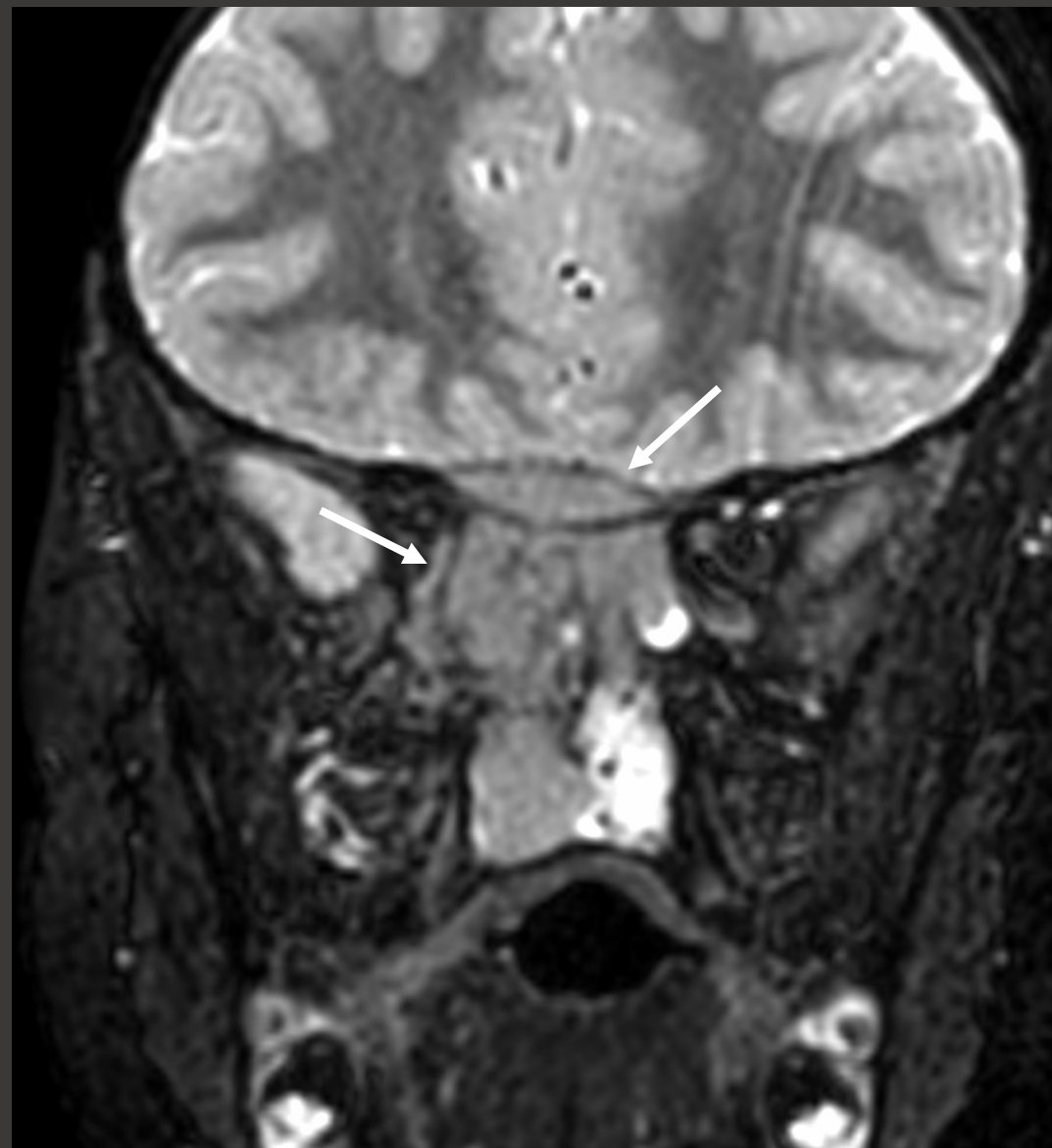
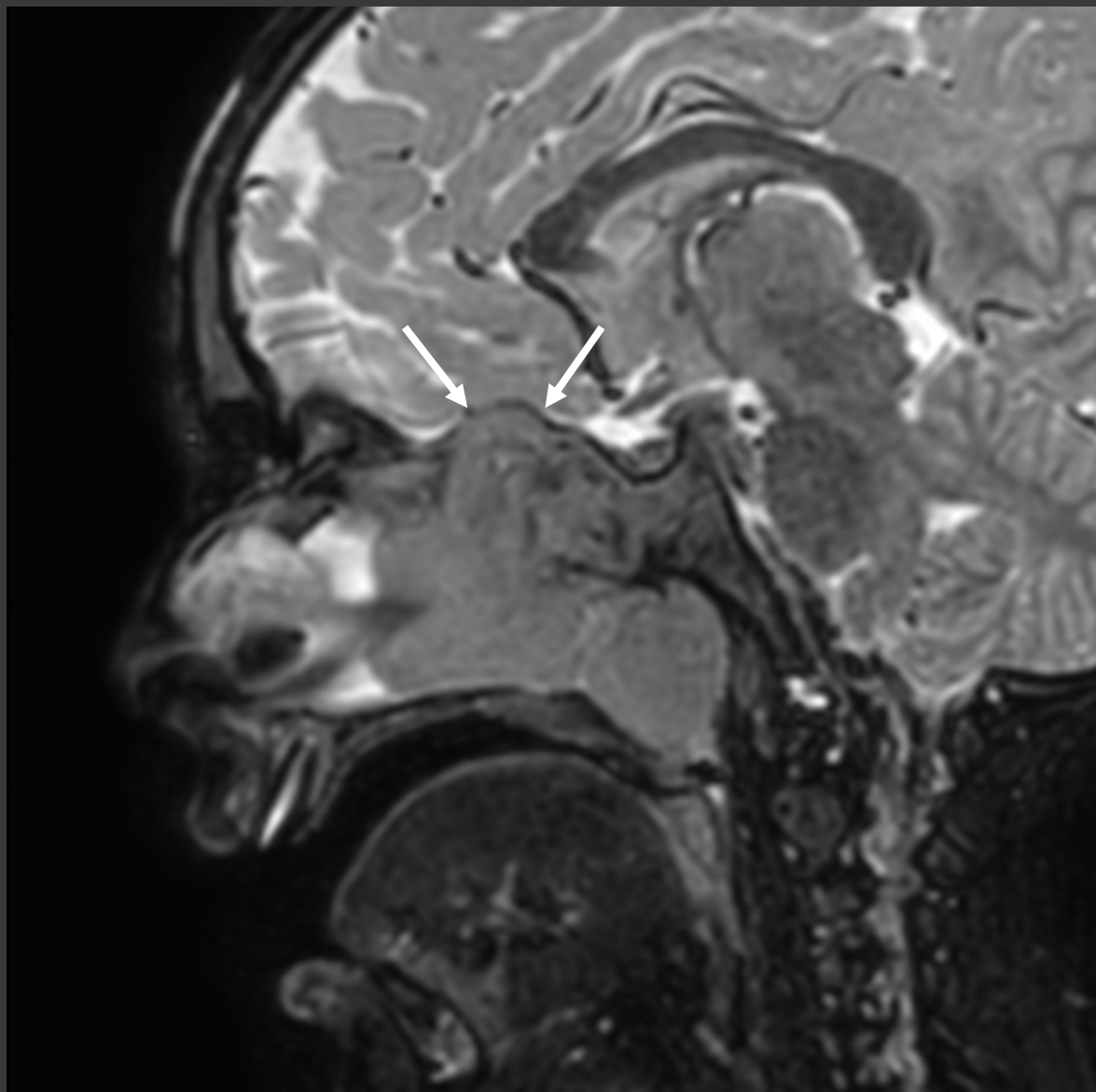
M, 8yo



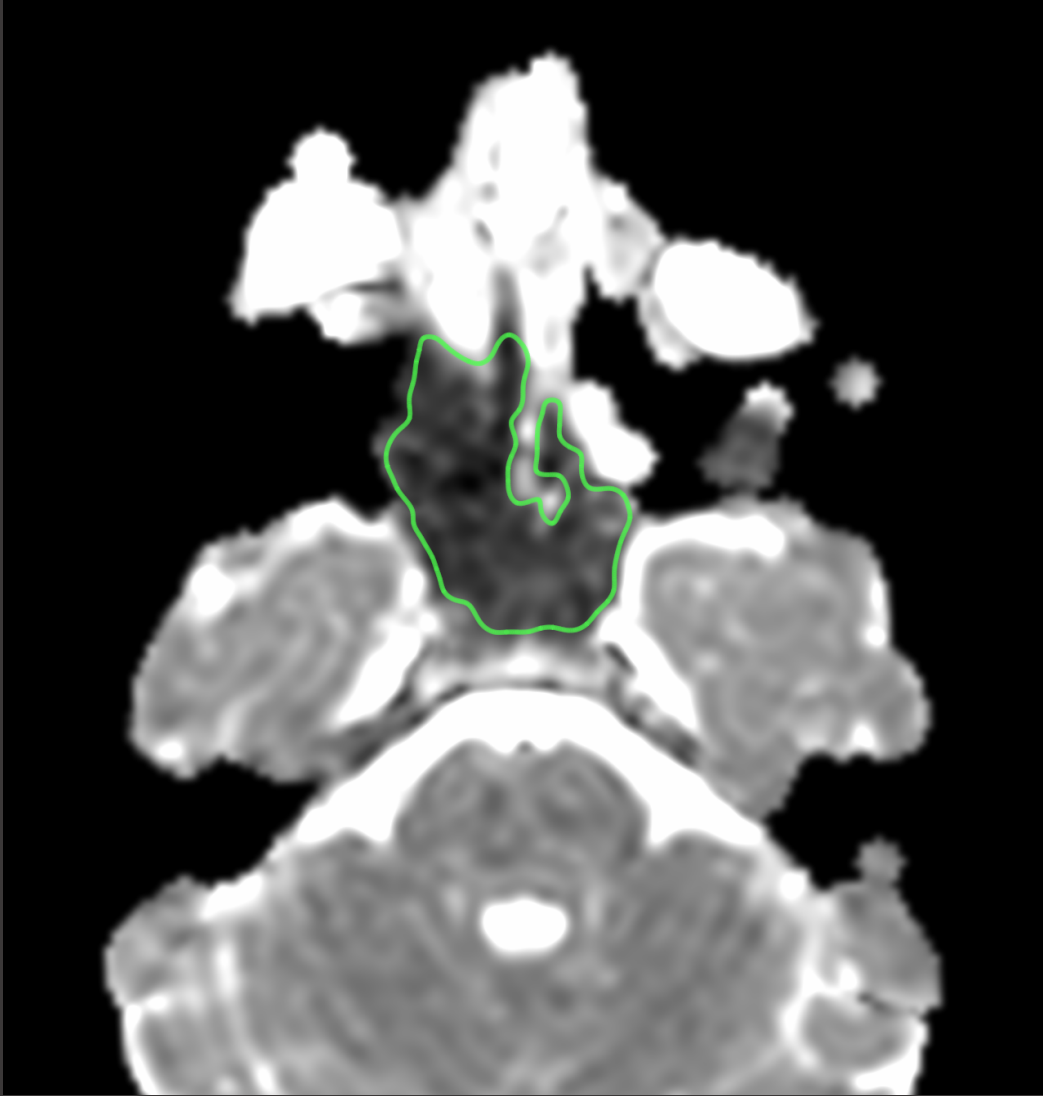
M, 8yo



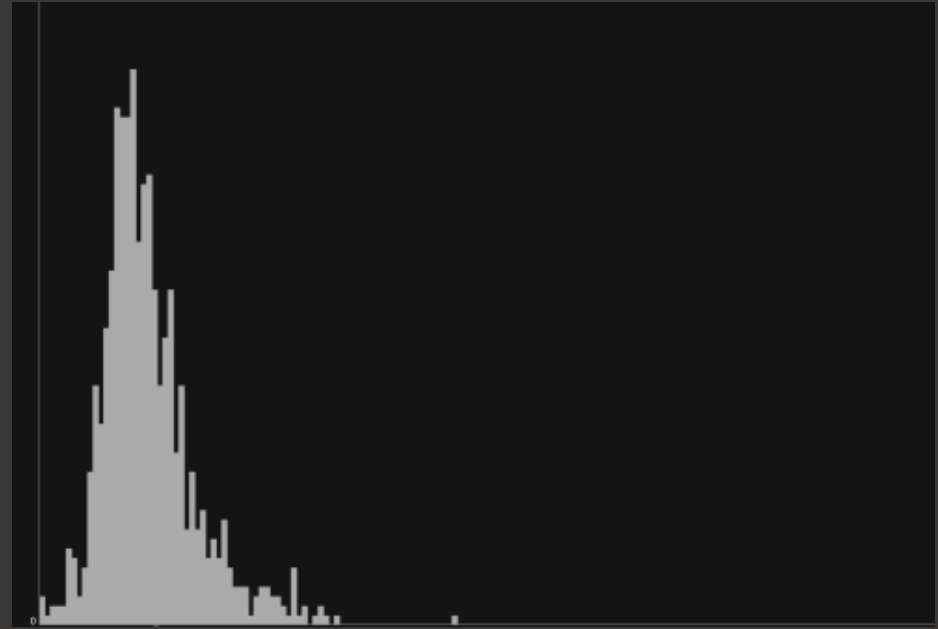
M, 8yo



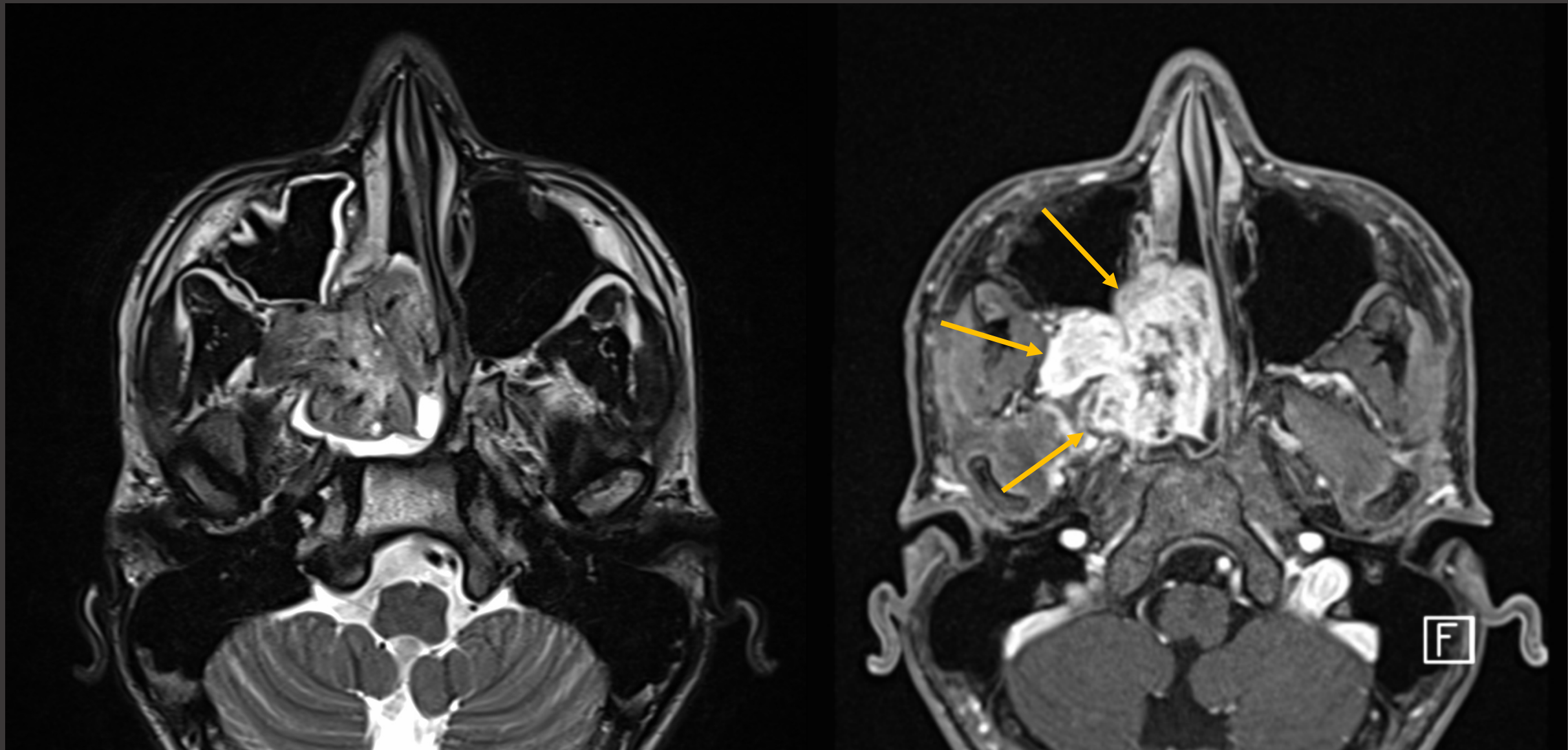
M, 8yo



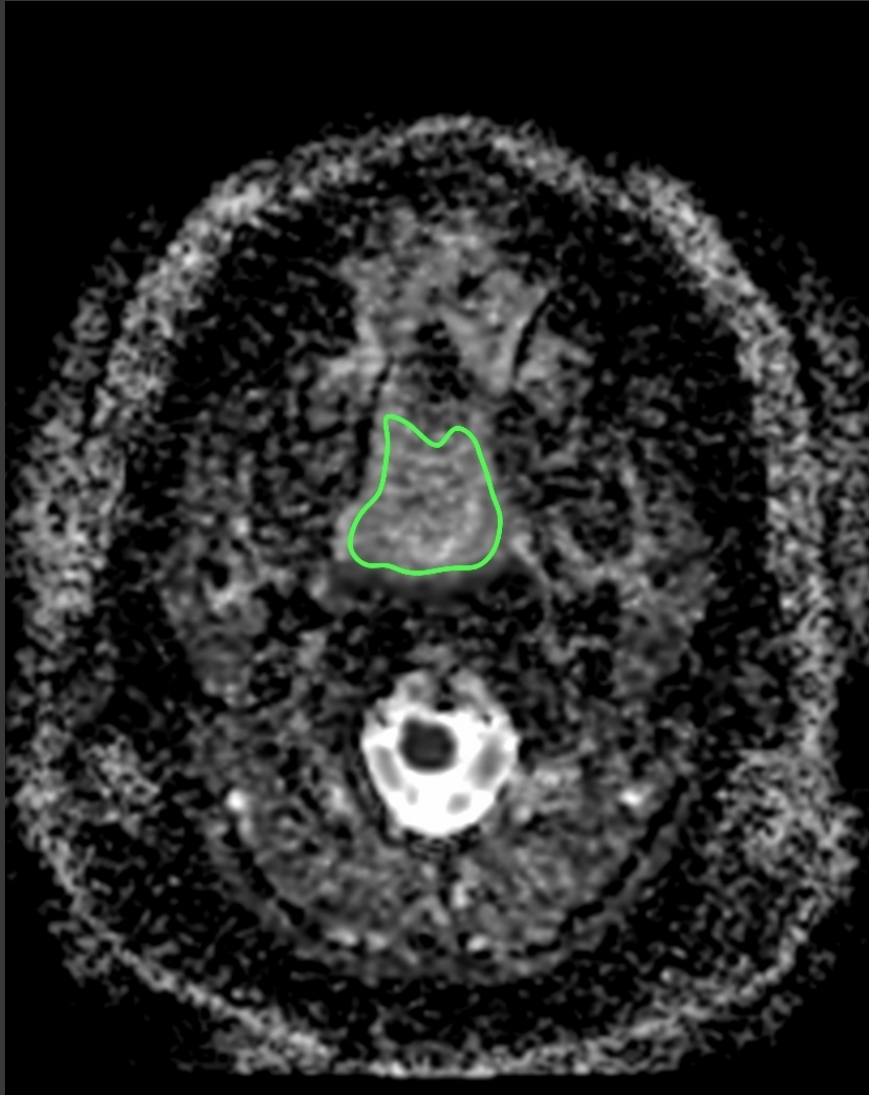
$0.44 \times 10^{-3} \text{ mm}^2/\text{s}$



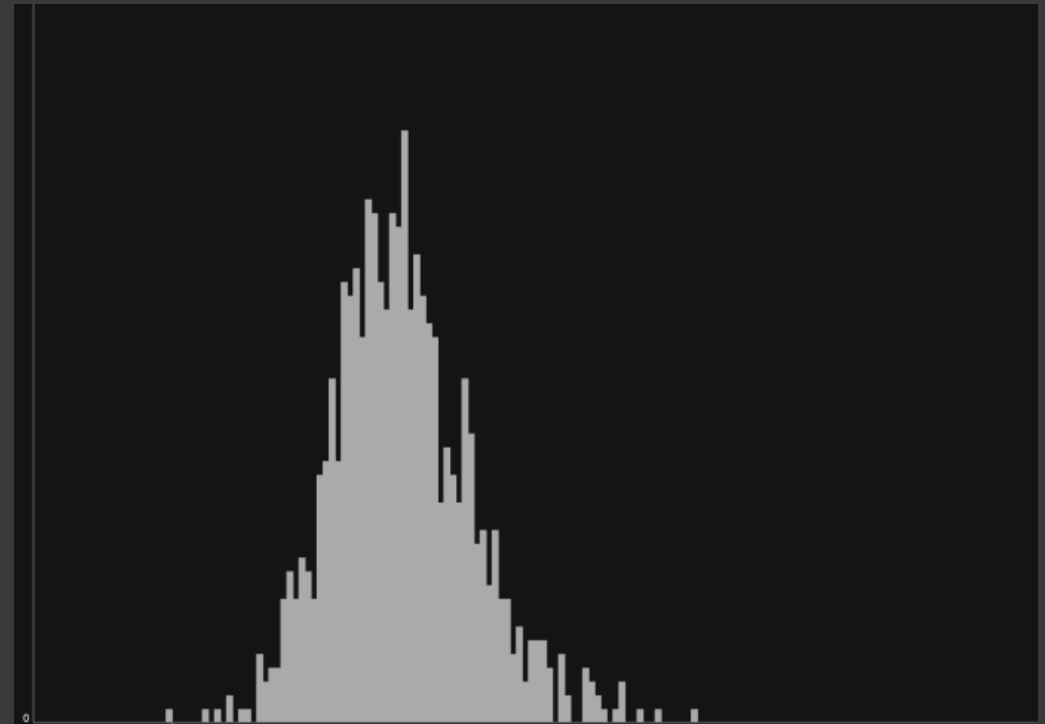
M, 12yo



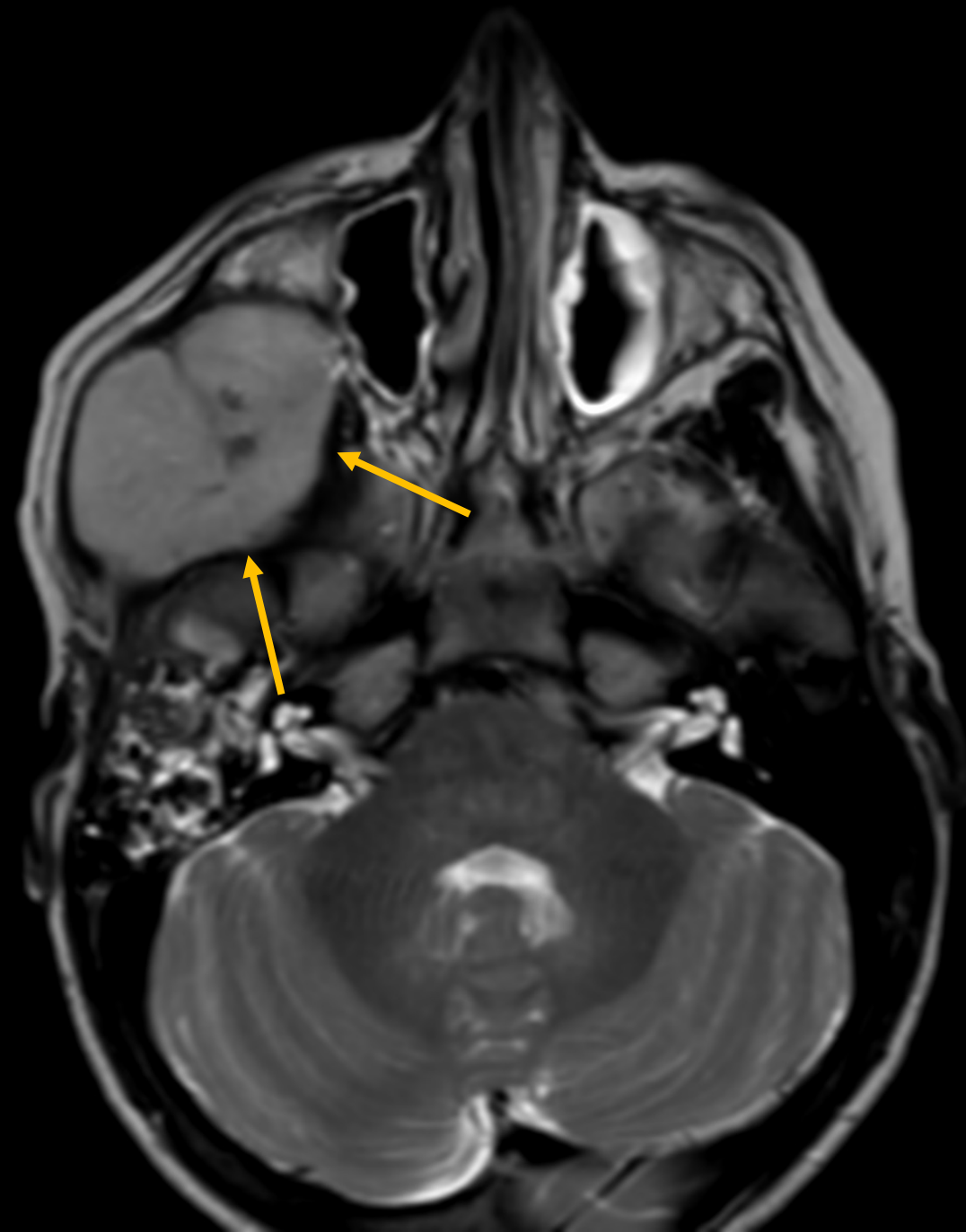
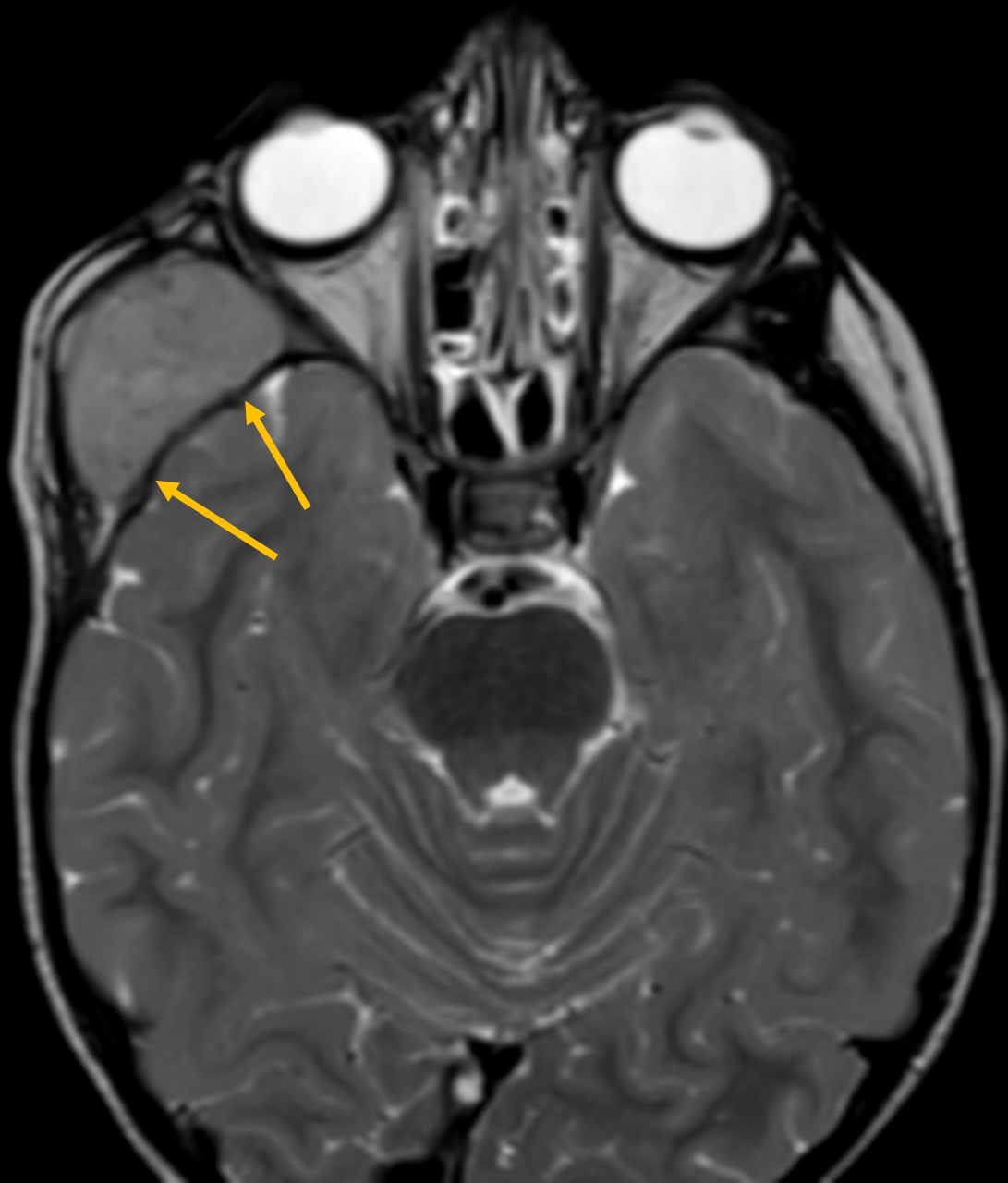M, 12yo



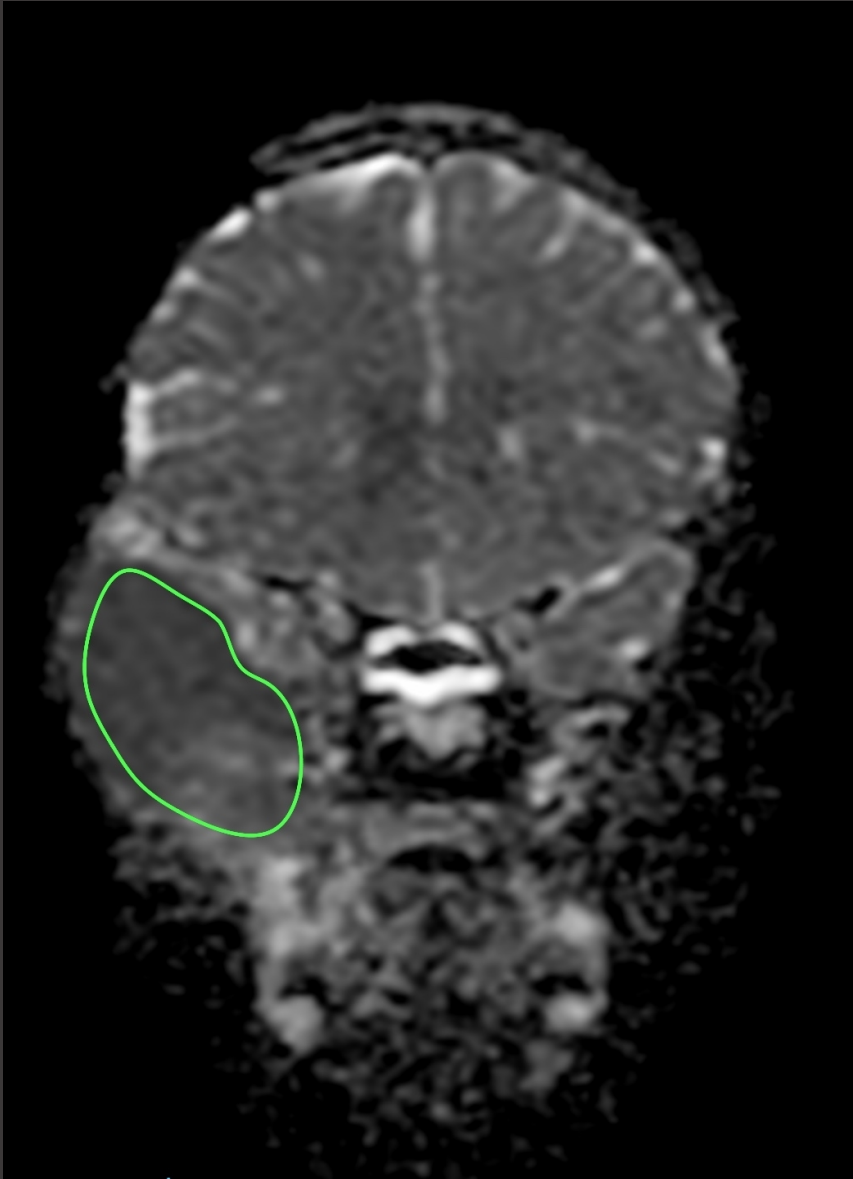
$1.92 \times 10^{-3} \text{ mm}^2/\text{s}$



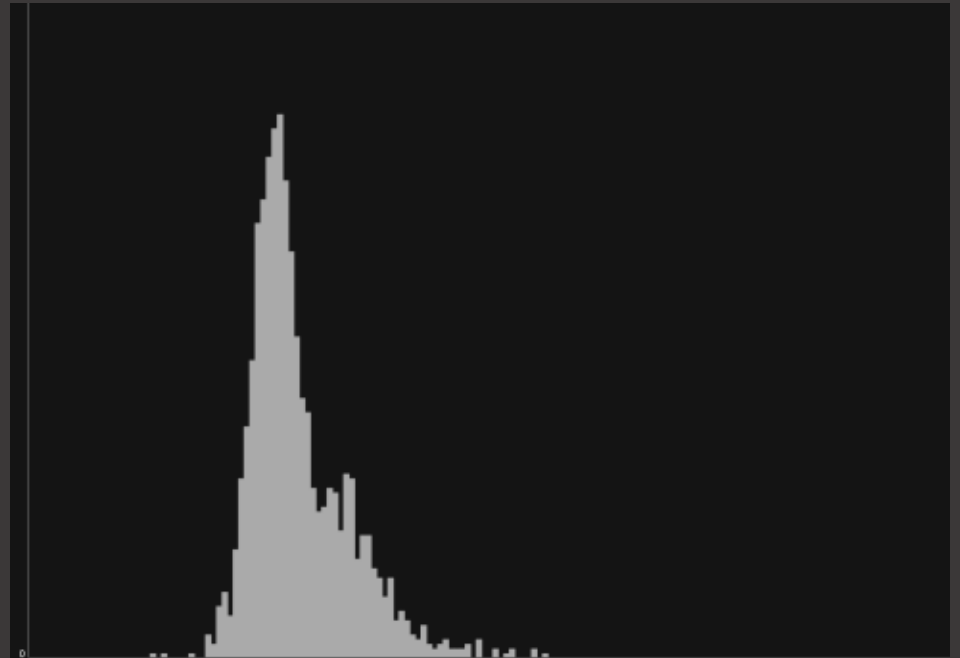
M, 5yo



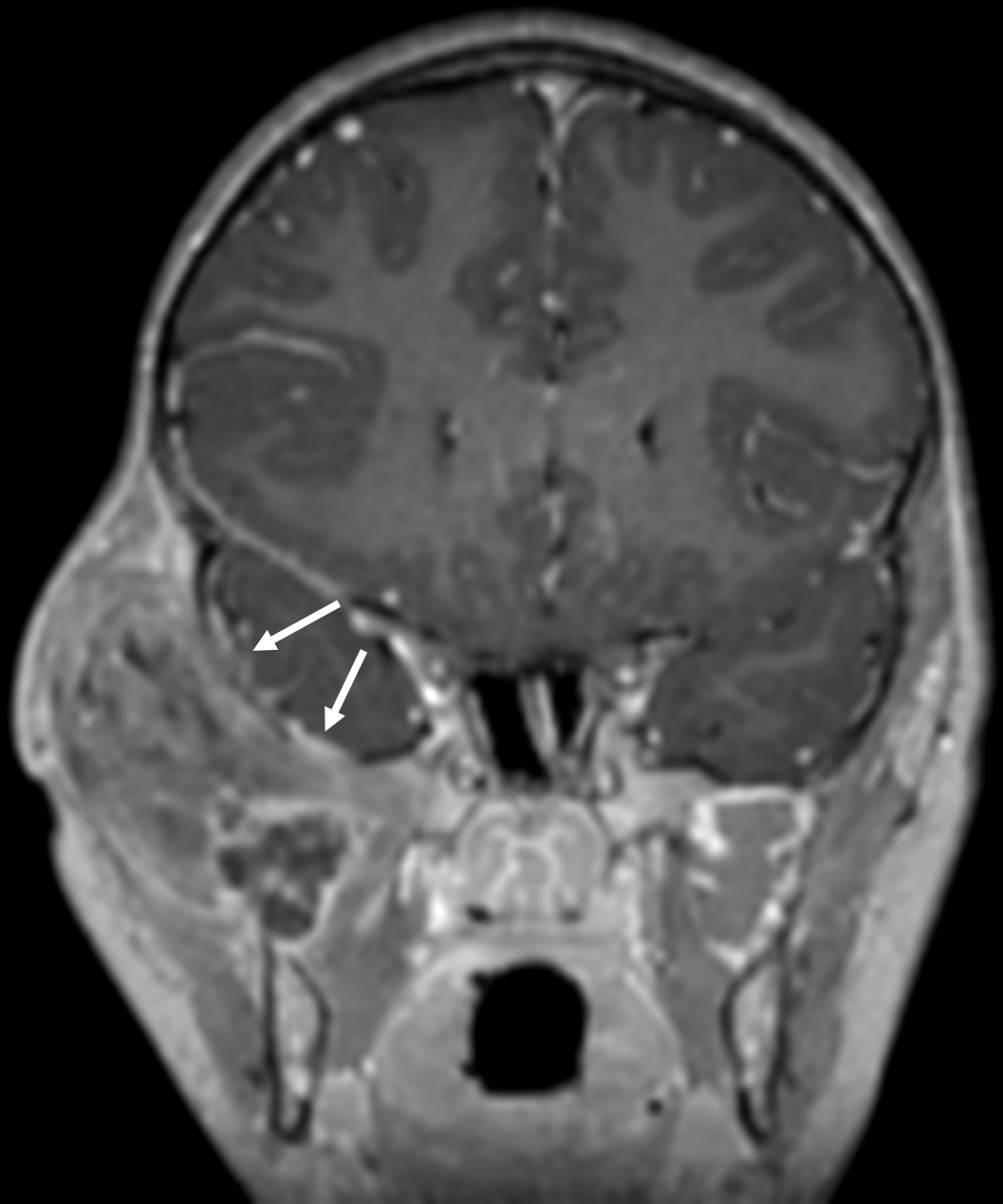
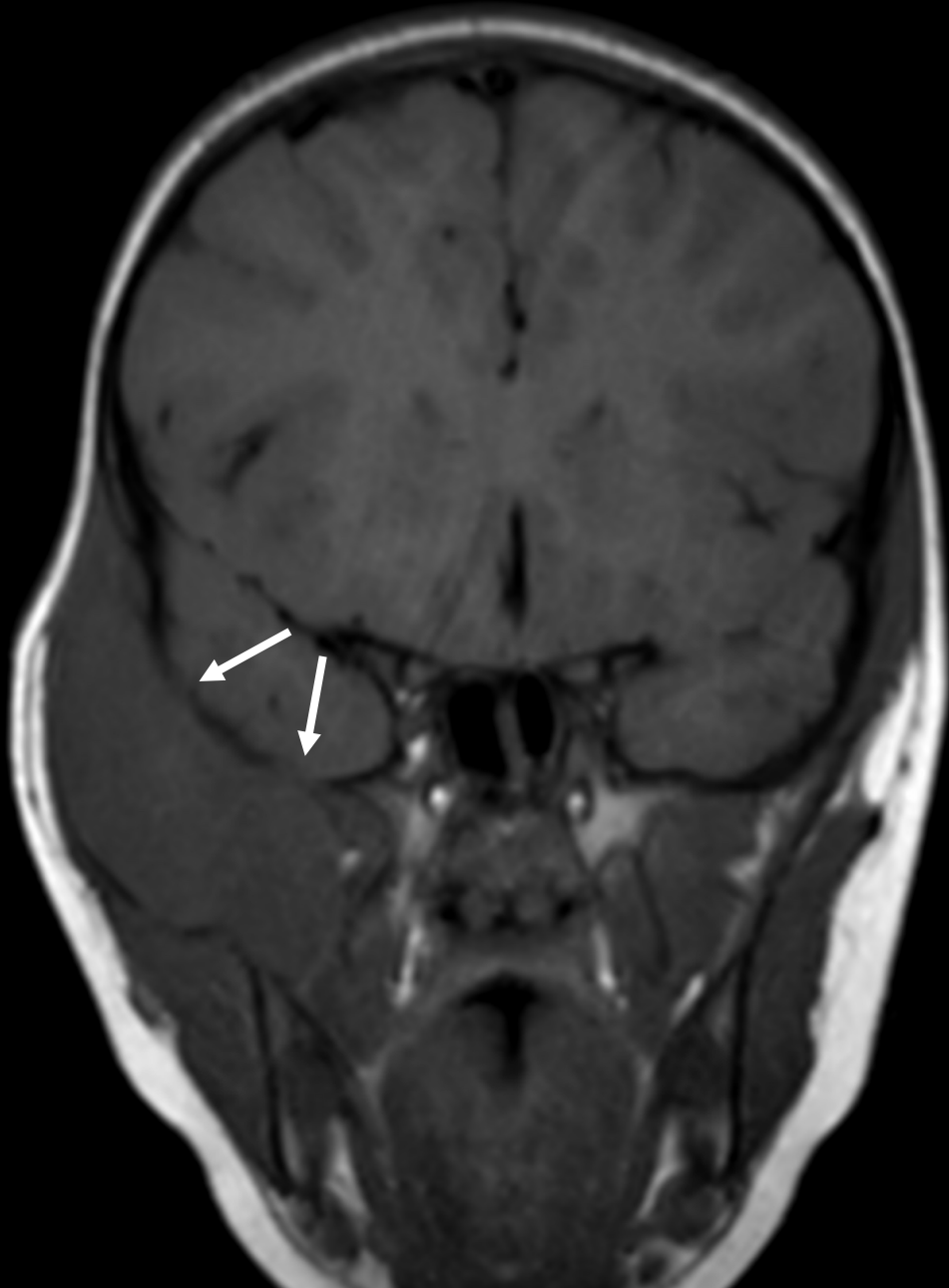
M, 5yo



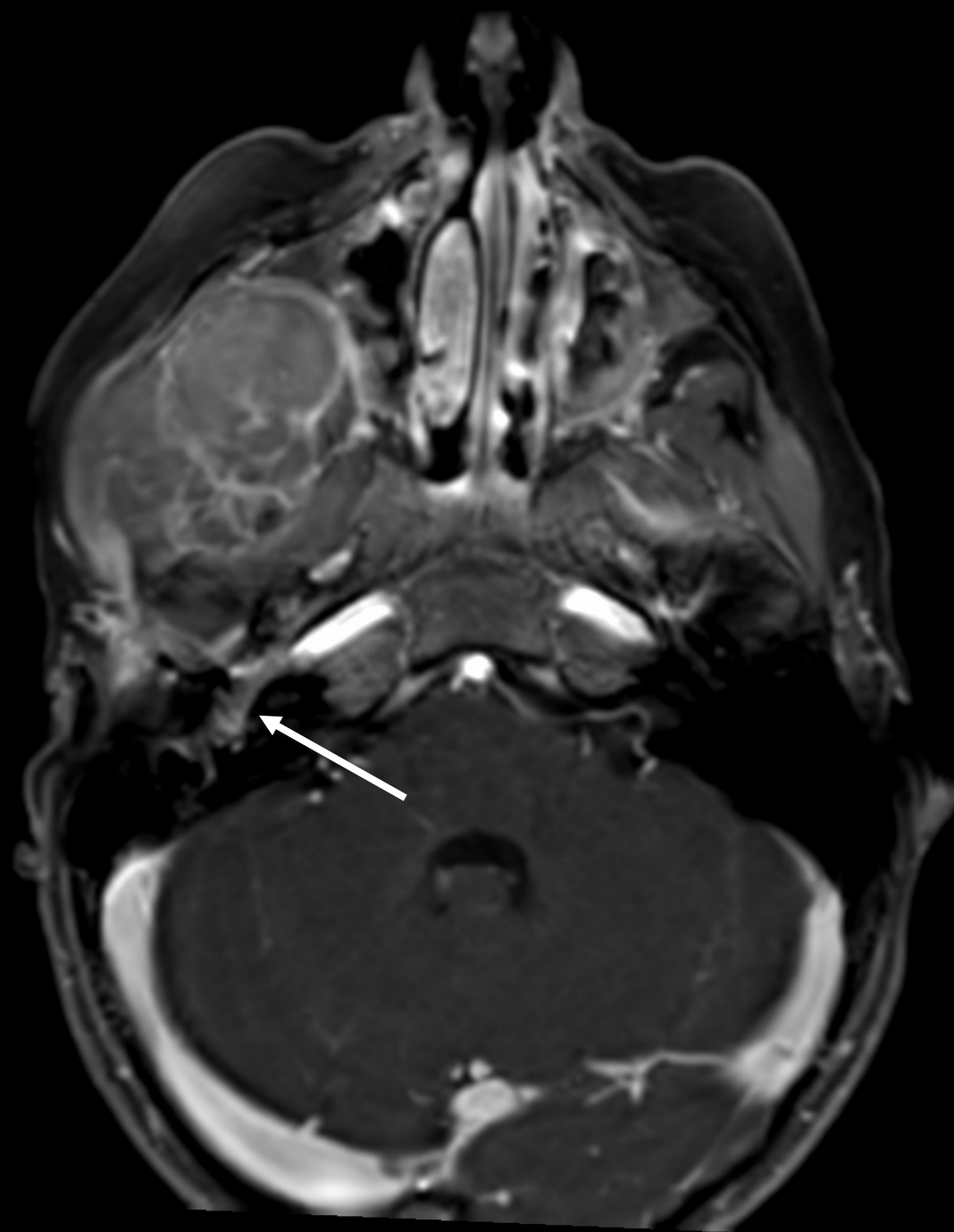
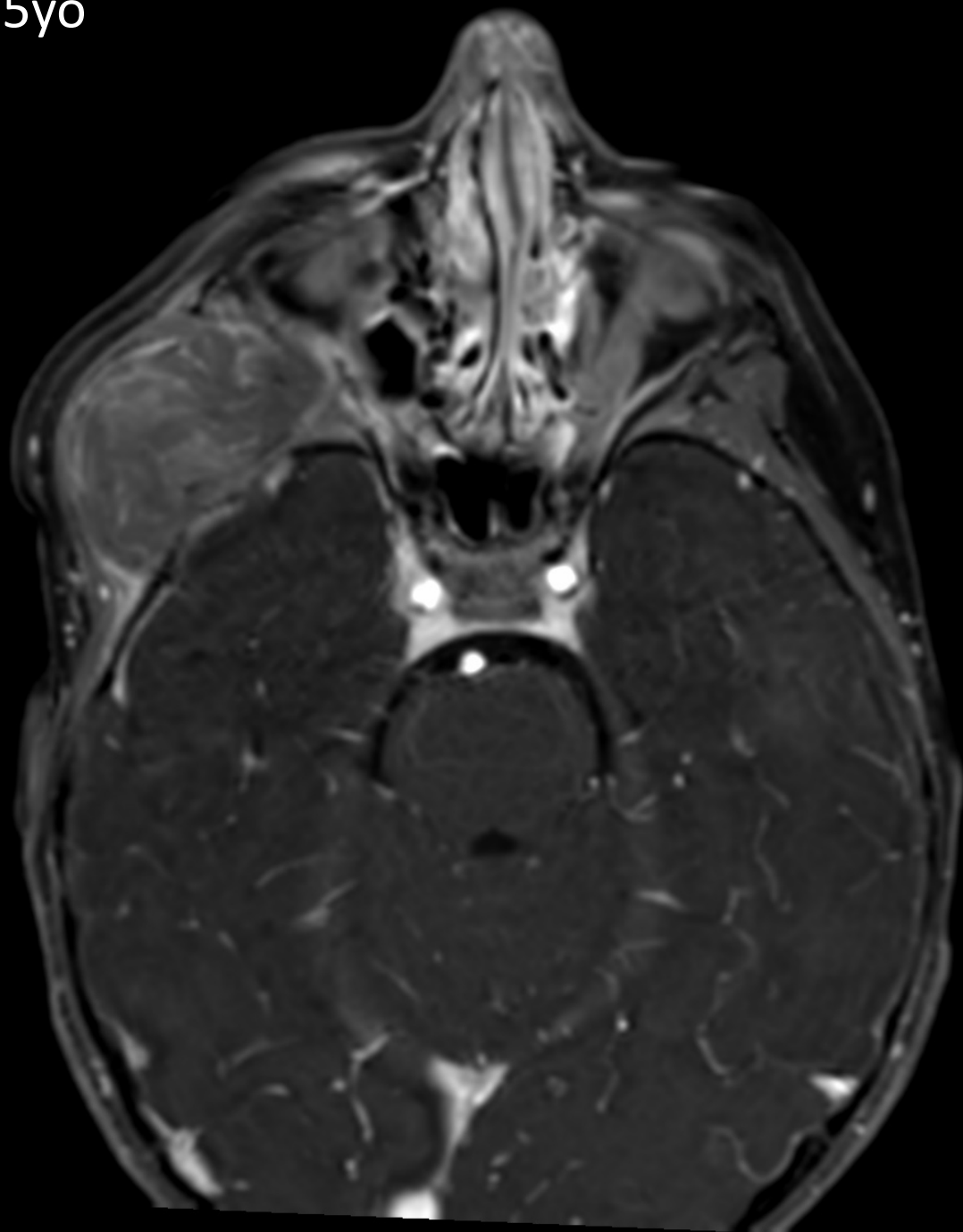
$0.90 \times 10^{-3} \text{ mm}^2/\text{s}$



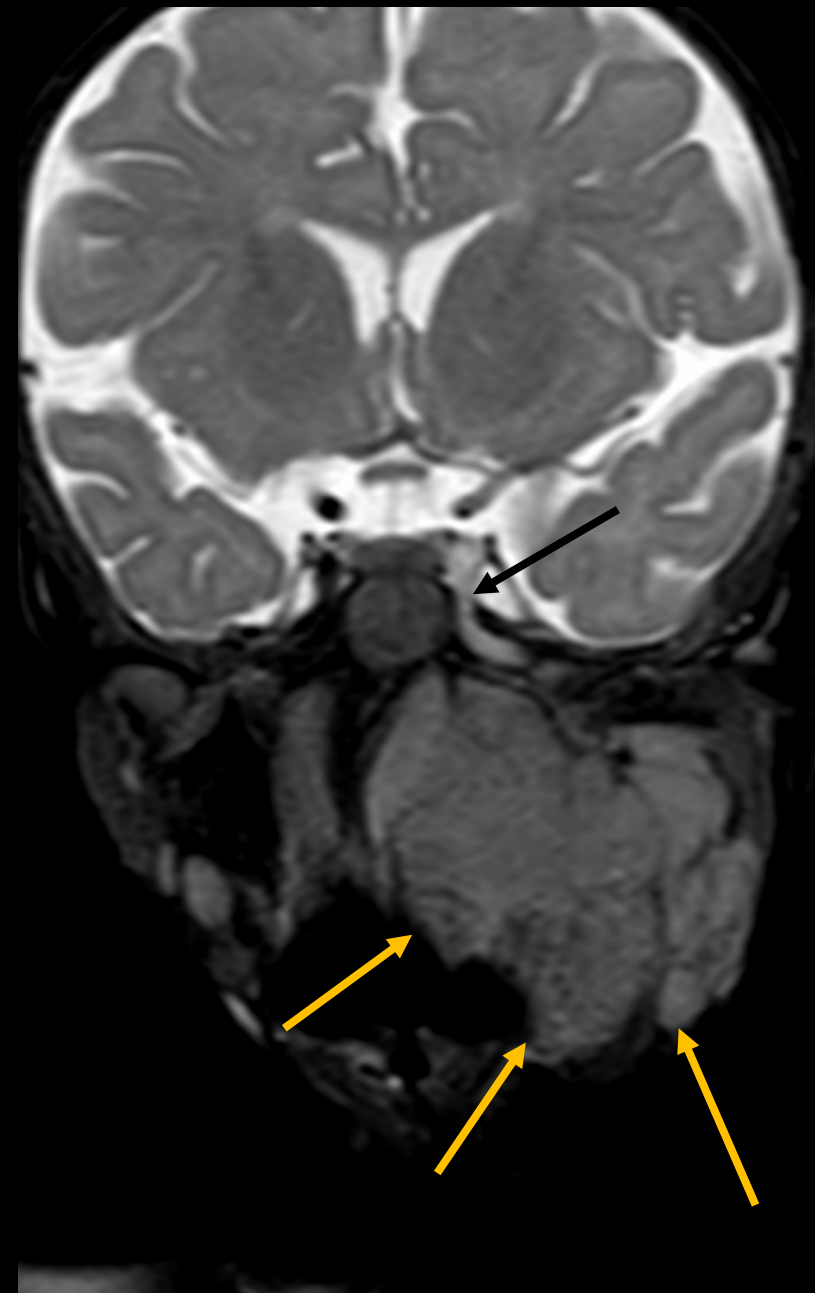
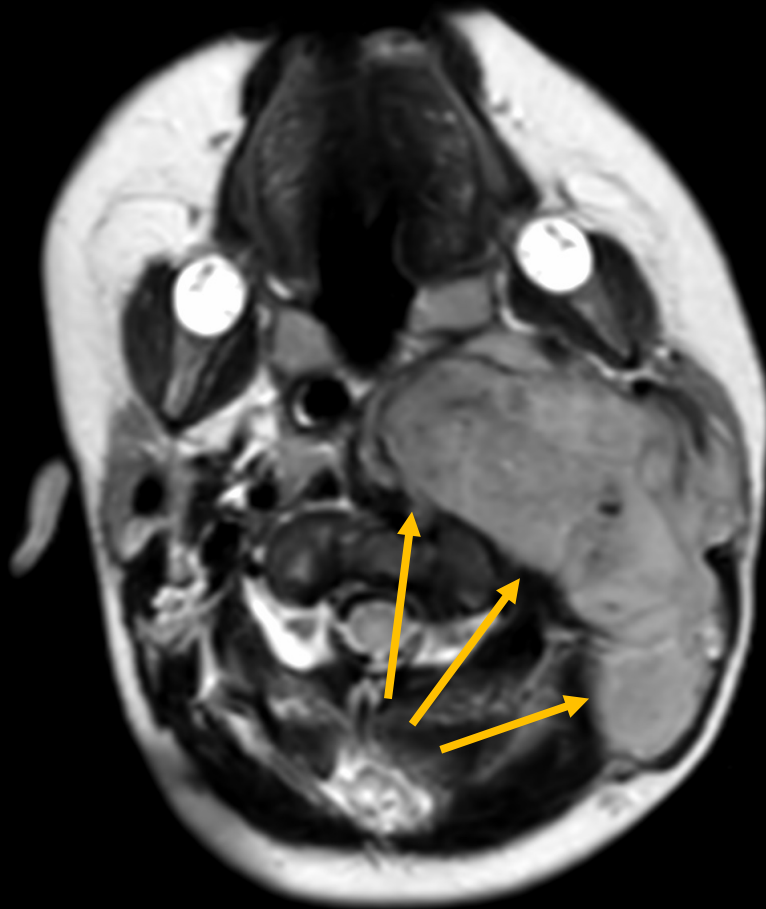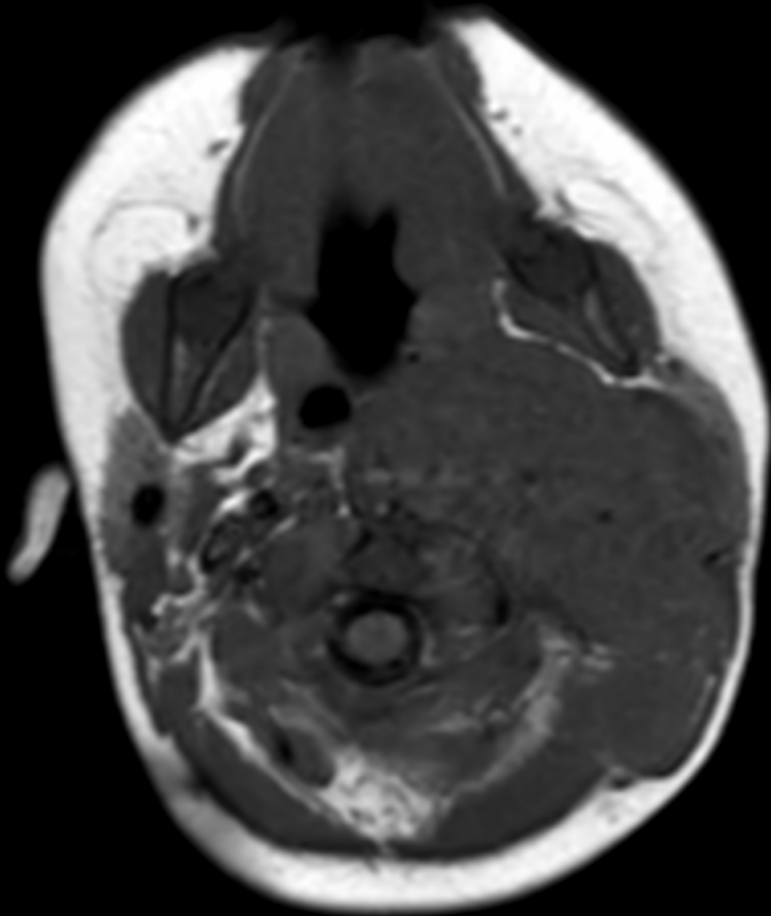
M, 5yo



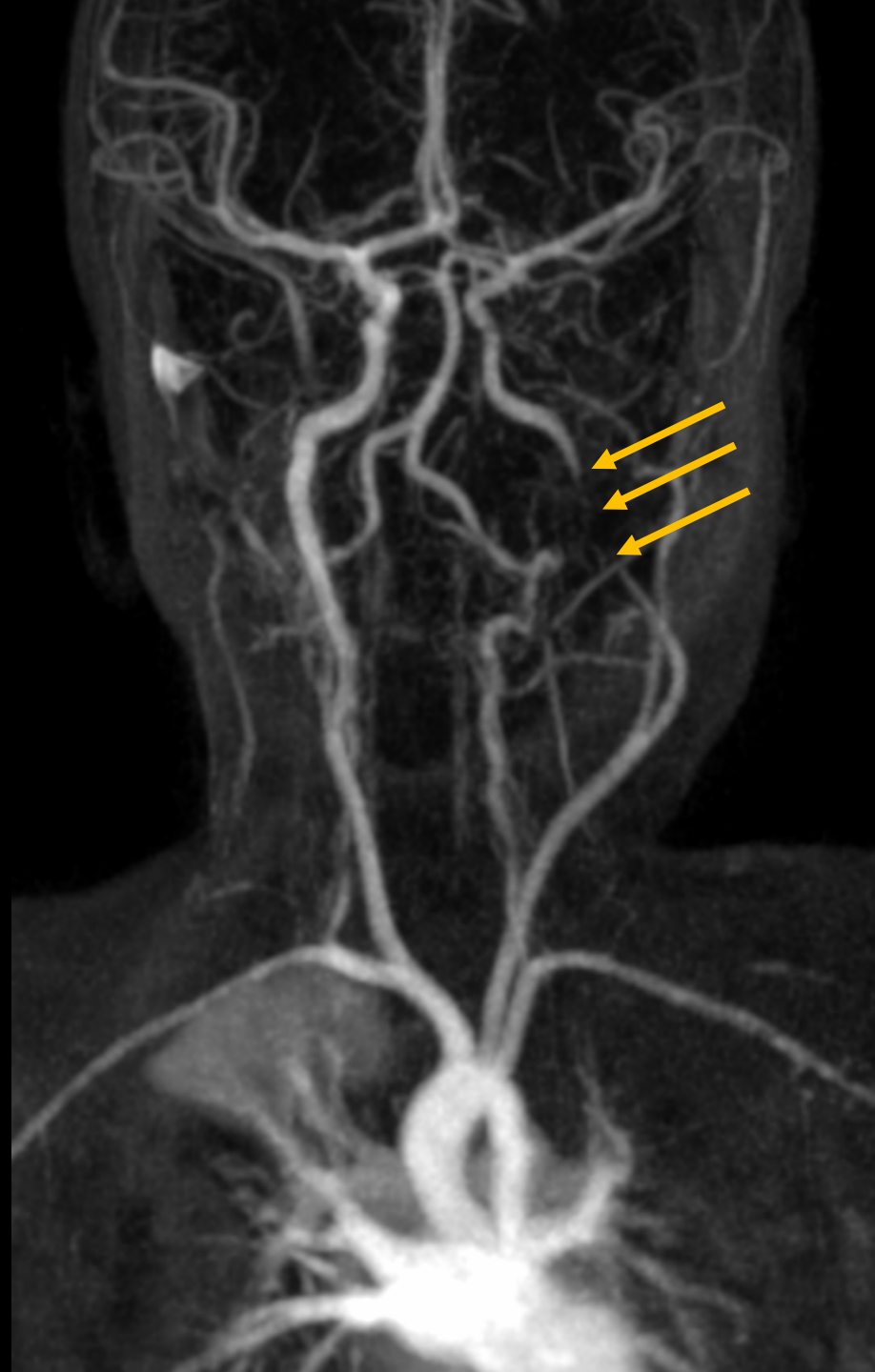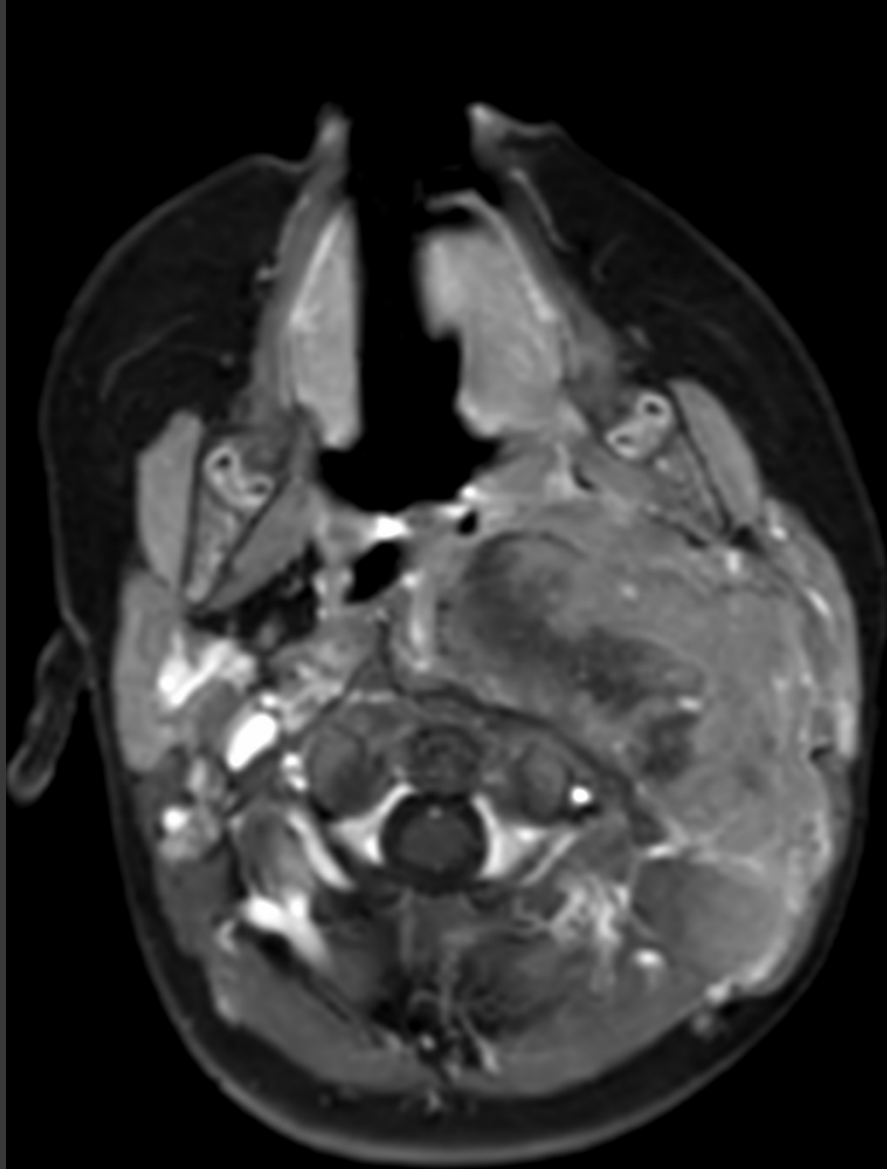
M, 5yo



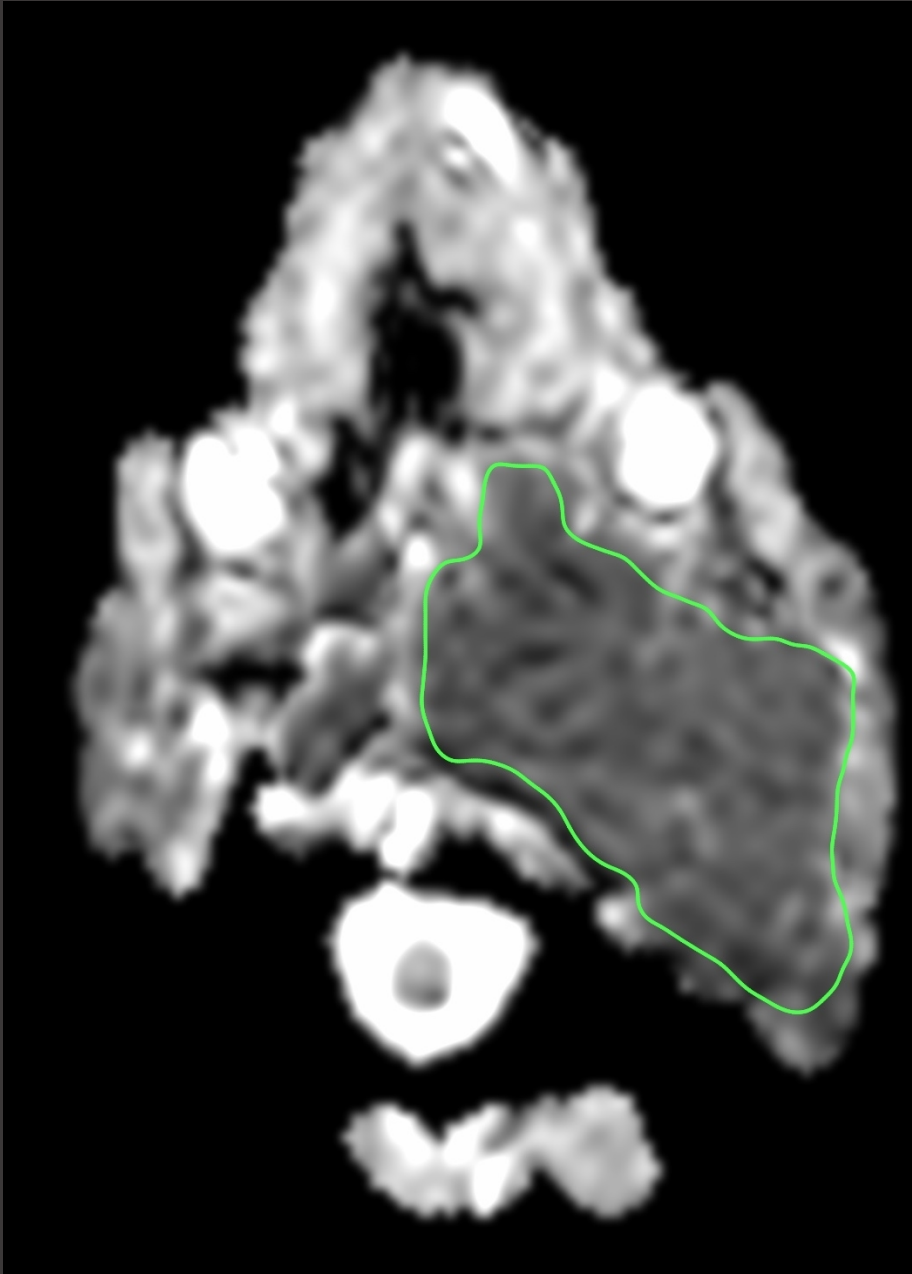
F, 8mo



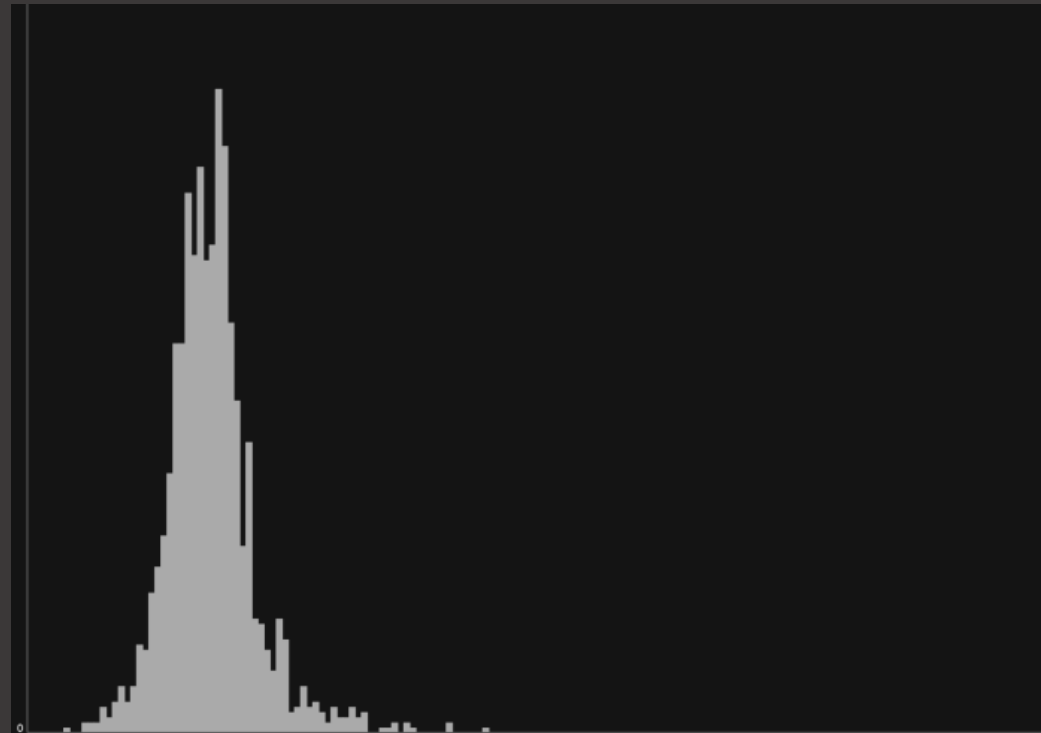
F, 8mo



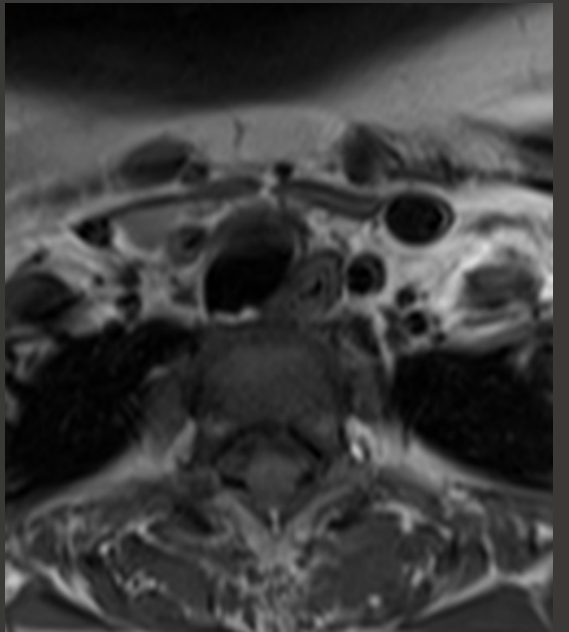
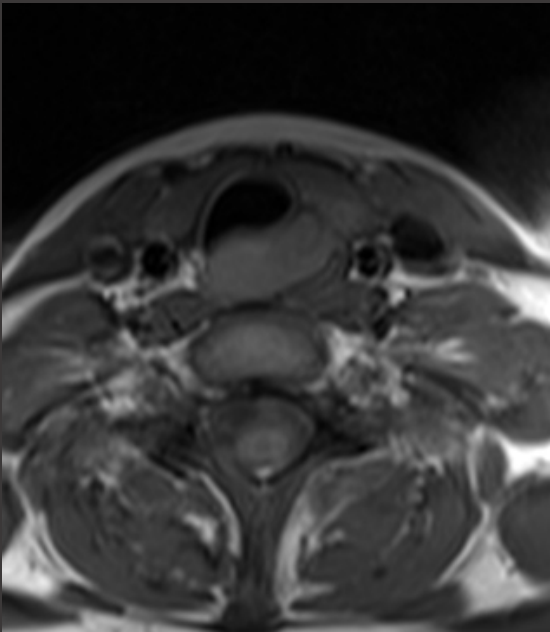
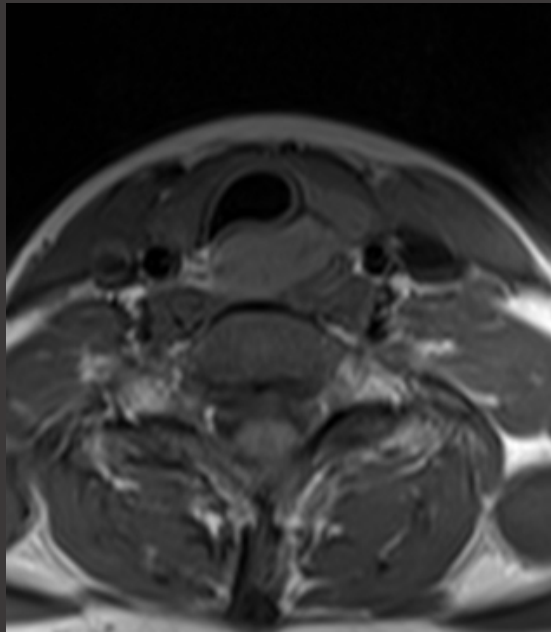
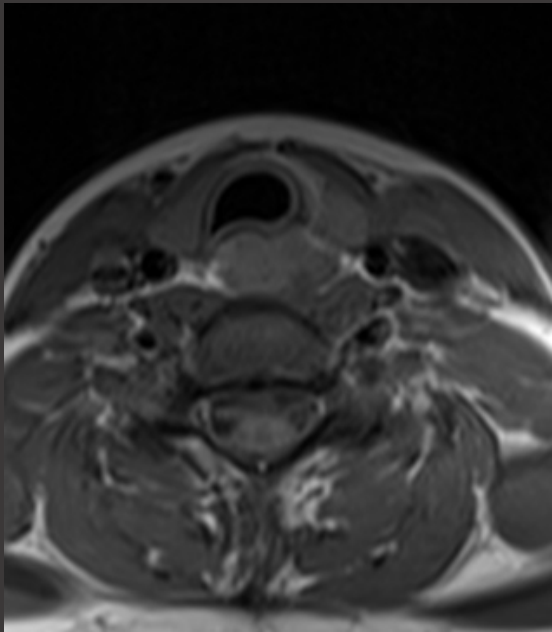
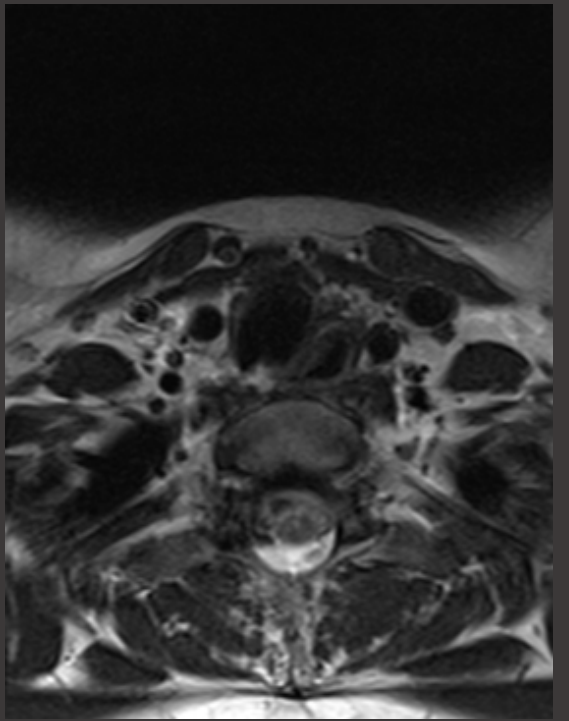
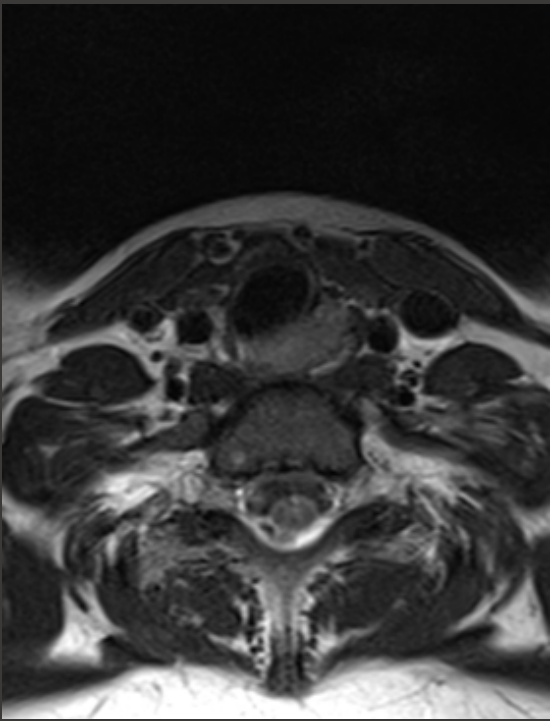
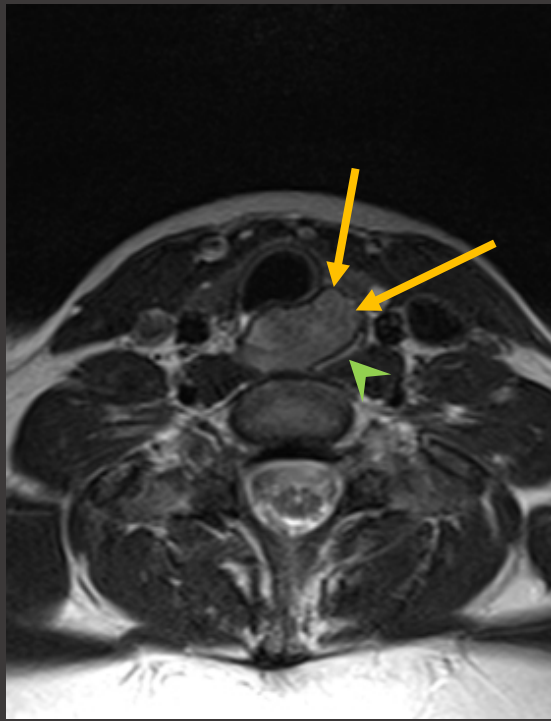
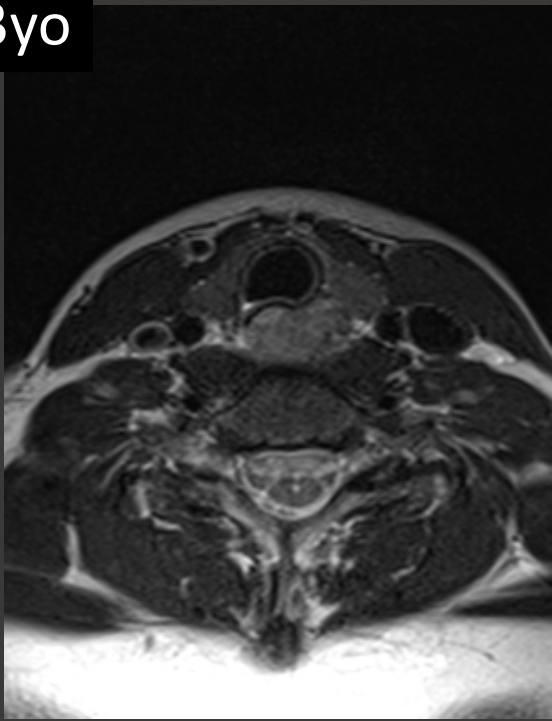
F, 8mo



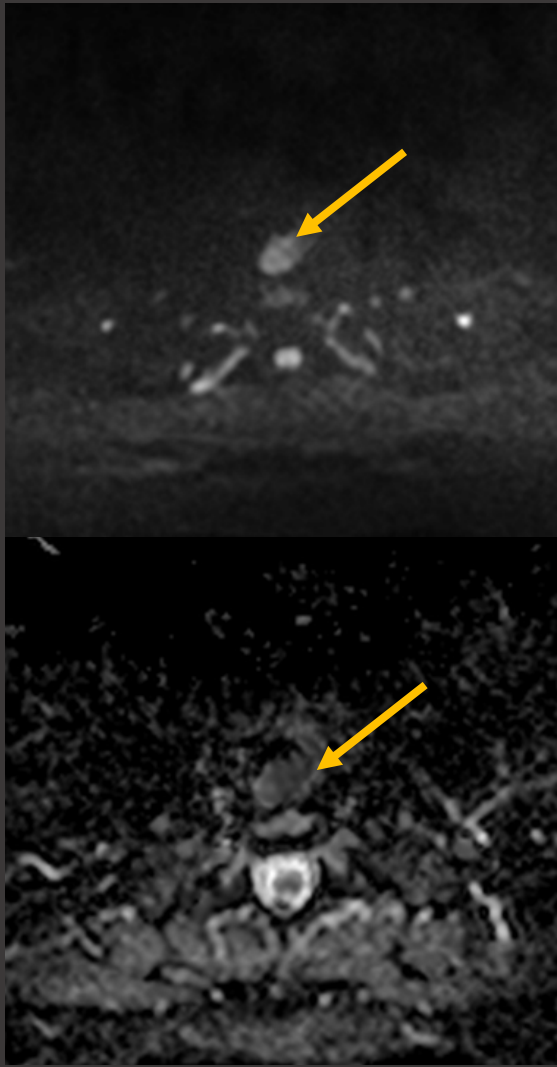
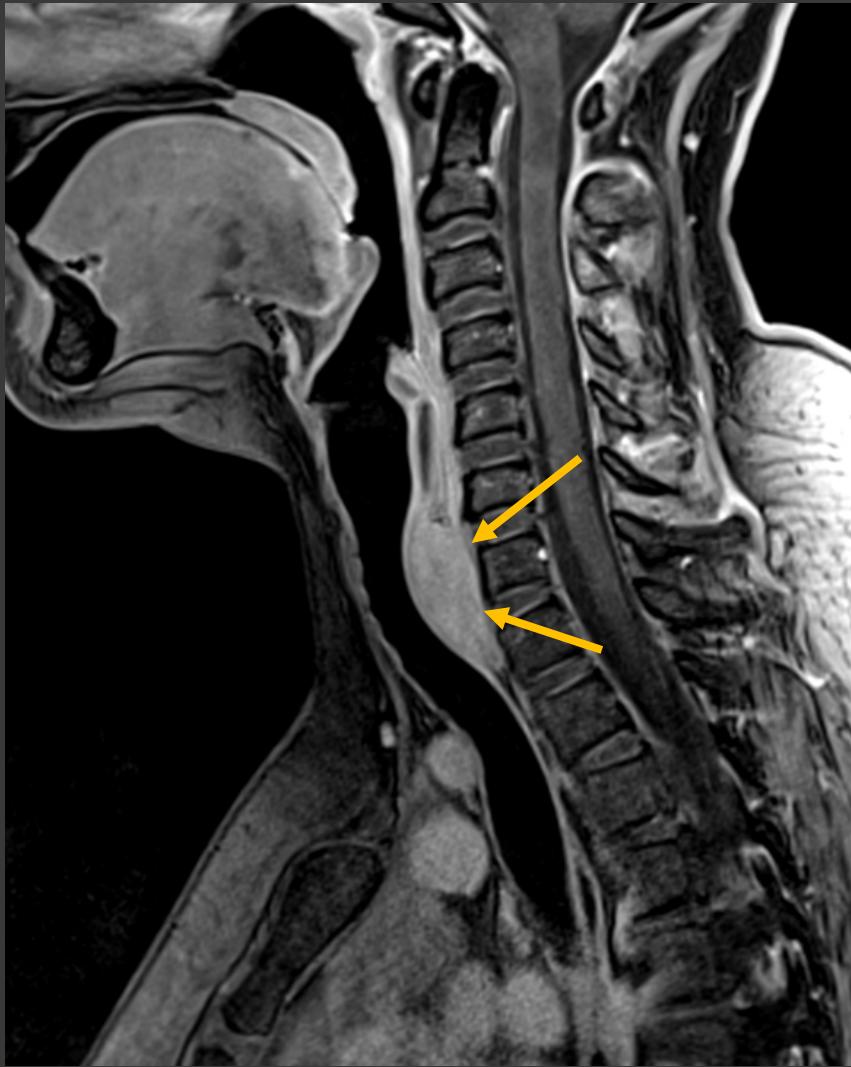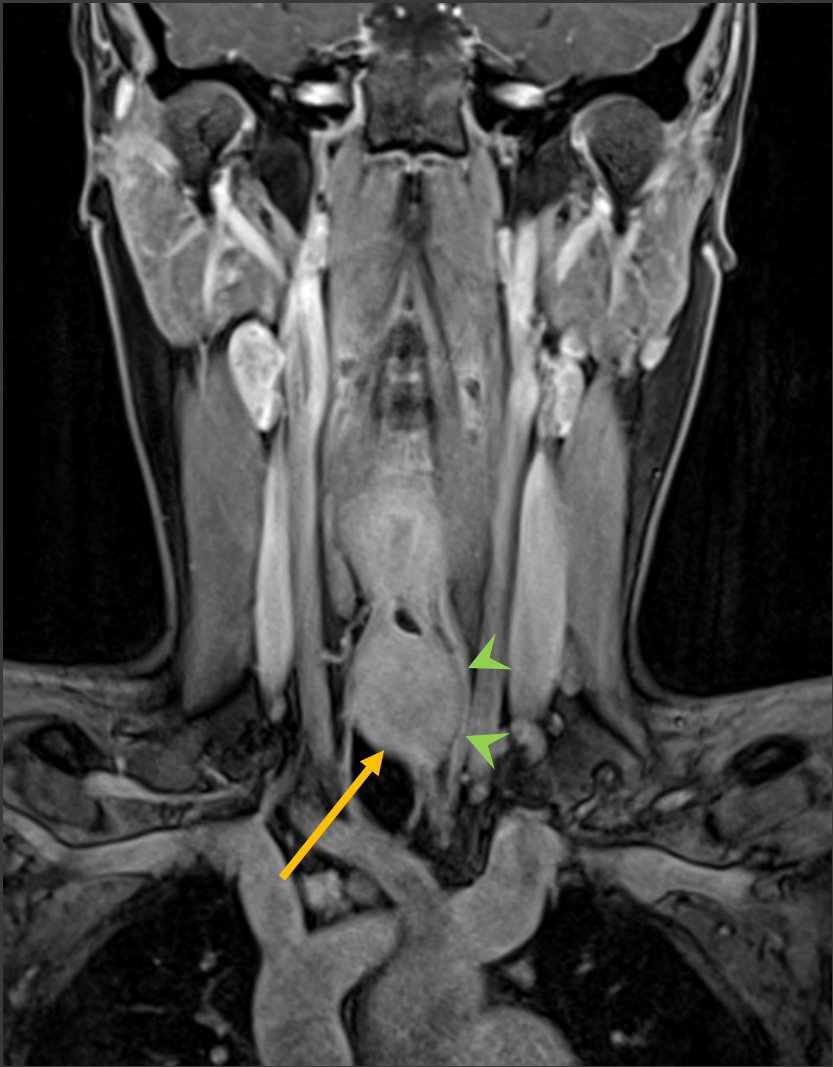
$0.58 \times 10^{-3} \text{ mm}^2/\text{s}$



F, 13yo



F, 13yo



Take home messages

- Most neck masses in children have some preference for specific locations, which can help in the differential diagnosis
 - There is substantial overlap across different entities, and some are typically transpatial
- The modality of choice for the study of head and neck masses in children is MR imaging, with dedicated protocols
- Correlation of key findings with the clinical context is often enough to reach a precise radiological diagnosis
- Radiologists need to be familiar with the most recent nomenclature of pediatric head and neck masses

Acknowledgements



University of Naples "Federico II"
Neuroradiology Unit

Prof. Arturo Brunetti
Prof. Andrea Elefante
Prof. Enrico Tedeschi
Prof. Francesco Briganti
Prof. Fabio Tortora
Dr. Sirio Coccozza
Dr. Giuseppe Pontillo
Dr. Martina Di Stasi
Dr. Chiara Paoella
Dr. Giuseppe Buono
Dr. Mariano Marseglia



Santobono-Pausilipon Children's Hospital
Neuroradiology Unit

Dr. Eugenio Maria Covelli
Dr. Carmela Russo
Dr. Domenico Cicala
Dr. Federica Mazio
Dr. Maria De Liso
Dr. Anna Nastro
Dr. Daniele Cascone
Dr. Adriana Cristofano
Dr. Camilla Russo



CDC Tortorella

Dr. Alessandra D'Amico



Great Ormond Street Hospital
Neuroradiology Unit

Dr. Felice D'Arco

